



Providing Choice & Value

Generic CT and MRI Contrast Agents



FRESENIUS
KABI

CONTACT REP

AJNR

Nitropaste for prevention and relief of vascular spasm.

M Erba, C A Jungreis and J A Horton

AJNR Am J Neuroradiol 1989, 10 (1) 155-156

<http://www.ajnr.org/content/10/1/155.citation>

This information is current as
of July 9, 2025.

Nitropaste for Prevention and Relief of Vascular Spasm

Michael Erba,^{1,2} Charles A. Jungreis, and Joseph A. Horton

Surgical neuroangiographic procedures (therapeutic embolizations) in the head and neck are often complicated by vascular spasm, particularly in external carotid artery branches. Numerous methods to relieve spasm have been attempted, including intraarterial administration of nitroglycerin, papavarine, contrast material, and lidocaine [1, 2]. Local infiltration with procaine has also been used [3]. Despite these measures, results are not always adequate, and procedures have had to be aborted.

We report a very simple and evidently safe method to prevent vasospasm, which has proved effective in 10 cases. Nitropaste is a cutaneously applied nitroglycerin ointment that has consistently had the vasodilatory effects we require without any of the complications sometimes encountered with other preparations.

Materials, Methods, and Results

Ten patients (three with meningioma, four with paraganglioma, and three with juvenile angiofibroma) who underwent embolization are included in this series. All had significant arterial spasm, which seemed likely to prolong or postpone the procedure.

Each patient was treated by the application of 2–5 in. of nitropaste to a nonhairbearing skin surface. Vascular relaxation was observed within 2–3 min in all 10 cases, and the procedure was continued (Fig. 1). No adverse reactions or complications were encountered, and patients generally experienced no unpleasant or agitating sensations.

Discussion

Nitroglycerin ointment, or nitropaste, is commonly used in the treatment of angina pectoris. It is produced by several manufacturers; the product used in this report is Nitrol ointment.* The mechanism of action is relaxation of the smooth muscles in the arterioles and venules of the body [4]. Nitropaste is applied from the tube onto a ruled piece of paper, which is then placed on the skin, usually the nonhairbearing chest. While nitropaste may be applied to any skin surface,

some reports indicate that both the clinical response and adverse reactions vary with application site. For example, the forehead appears slightly more sensitive than the chest, but good responses have been recorded from both [5]. In two of our cases, nitropaste was applied to the lateral cervical region over the area of vasospasm and subjectively the results were indistinguishable from the chest applications. Thus, proximity to the site of spasm does not appear to be a key factor. The dosage is measured in terms of the length of paste that is applied; dosage ranges from 2–5 in. and depends on the degree of spasm and the size of the patient.

The onset of action is considered by the manufacturer to be approximately 30 min. In our experience, however, the onset of action is usually within 3–5 min and sometimes less. The duration of action is approximately 8 hr and therefore during any one procedure, a second dosage has not been required.

A contraindication to the use of nitropaste is intolerance of nitrates, a problem we have not encountered. Also, we have not administered nitropaste to patients in congestive heart failure or with acute myocardial infarctions, those in whom hemodynamic changes might be more significant. Even so, the heart rates and blood pressures of our patients have not significantly changed even after a large application. Adverse reactions in angina patients have been reported to include headaches and hypotension. Neither of these reactions has occurred in our experience. Perhaps the limited dosage schedule—one single dose—is responsible. If significant hypotension were to occur, the paste would be wiped off with a damp washrag.

The use of nitropaste has been simple, effective, and, most important, safe when used in conjunction with surgical neuroangiographic procedures. In five additional cases, nitropaste was applied prophylactically at the beginning of the catheterization. Each of these was a patient in whom an external carotid embolization and multiple superselective catheterizations were performed. Although we would have expected arterial spasm, none occurred. We suggest that this technique be incorporated into the armamentarium of the angiographer and, particularly, the interventionalist.

* William H. Rorer, Inc., Fort Washington, PA.

Received November 18, 1986; accepted after revision June 8, 1988.

¹ All authors: Department of Radiology, Presbyterian-University Hospital, De Soto at O'Hara Sts., Pittsburgh, PA 15213. Address reprint requests to C. A. Jungreis.

² Present address: Department of Radiology, Salem Hospital, 665 Winter S.E., Salem, OR 97301.

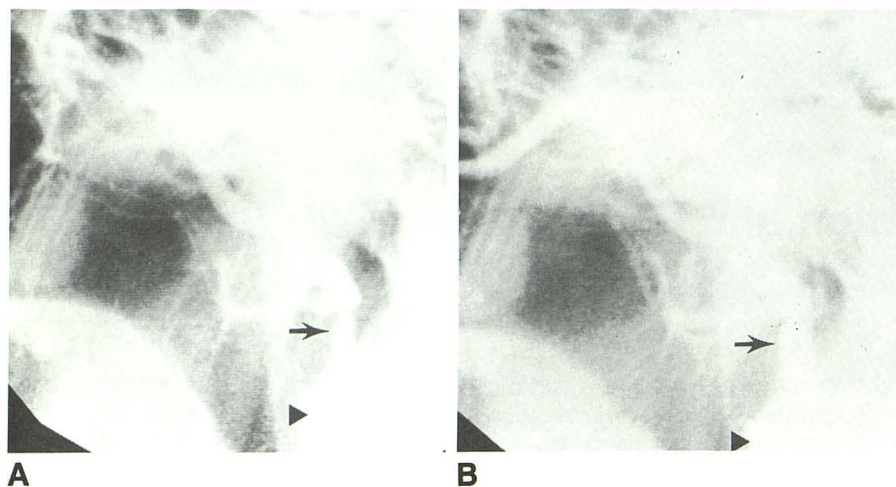


Fig. 1.—A, Lateral fluoroscopic image of distal external carotid artery with vasospasm (arrow) induced by catheter (arrowhead).

B, Vasospasm relieved (arrow) 3 min after application of nitropaste to chest. Catheter position (arrowhead) is unchanged.

REFERENCES

1. Abrams HL, ed. *Abrams angiography*, 3rd ed. Boston: Little, Brown, 1983:98-104
2. Reuter SR, Redman HC. *Gastrointestinal angiography*, 2nd ed. Philadelphia: Saunders, 1977:371-374
3. Taveras JM, Wood EH. *Diagnostic neuroradiology*, 2nd ed. Baltimore: Williams & Wilkins, 1976:850
4. Corwin S, Reiffel JA. Nitrate therapy for angina pectoris. *Arch Intern Med* 1985;145:538-543
5. Hansen MS, Woods SL, Wills RE. Relative effectiveness of nitroglycerin ointment according to site of application. *Heart Lung* 1979;8:716-720