



## Discover Generics

Cost-Effective CT & MRI Contrast Agents



WATCH VIDEO

# AJNR

## **The Anatomic Basis of Vertebrogenic Pain and the Autonomic Syndrome Associated with Lumbar Disk Extrusion**

John R. Jenkins, Anthony R. Whittemore and William G. Bradley

*AJNR Am J Neuroradiol* 1989, 10 (2) 219-231

<http://www.ajnr.org/content/10/2/219>

This information is current as of June 28, 2025.

# The Anatomic Basis of Vertebrogenic Pain and the Autonomic Syndrome Associated with Lumbar Disk Extrusion

John R. Jenkins<sup>1,2</sup>  
 Anthony R. Whittemore<sup>1</sup>  
 William G. Bradley<sup>1</sup>

Extruded lumbar intervertebral disks traditionally have been classified as posterior or central in location. A retrospective review of 250 MR imaging examinations of the lumbar spine that used mid- and high-field imagers revealed 145 positive studies, which included a significant number of extrusions extending anteriorly. With the lateral margin of the neural foramen/pedicle as the boundary, 29.2% of peripheral disk extrusions were anterior and 56.4% were posterior. In addition, a prevalence of 14.4% was found for central disk extrusions, in which there was a rupture of disk material into or through the vertebral body itself. The clinical state of *neurogenic* spinal radiculopathy accompanying posterior disk extrusion has been well defined; however, uncomplicated anterior and central disk extrusions also may be associated with a definite clinical syndrome. The *vertebrogenic* symptom complex includes (1) local and referred pain and (2) autonomic reflex dysfunction within the lumbosacral zones of Head. Generalized alterations in viscerosomatic tone potentially may also be observed. The anatomic basis for the mediation of clinical signs and symptoms generated within the disk and paradiskal structures rests with afferent sensory fibers from two primary sources: (1) posterolateral neural branches emanating from the ventral ramus of the *somatic* spinal root and (2) neural rami projecting directly to the paravertebral *autonomic* neural plexus. Thus, conscious perception and unconscious effects originating in the vertebral column, although complex, have definite pathways represented in this dual peripheral innervation associated with intimately related and/or parallel central ramifications. It is further proposed that the specific clinical manifestations of the autonomic syndrome are mediated predominantly, if not entirely, within the sympathetic nervous system.

The directional differentiation of lumbar disk extrusions by MR, together with a clarification and appreciation of the accompanying clinical somatic and autonomic syndromes, should contribute both to understanding the specific causes as well as to establishing the appropriate treatment of acute and chronic signs and symptoms engendered by many nonspecific disease processes involving the spinal column.

The written history of intervertebral disk herniation originated with Kochner's postmortem description in 1896. Since that time, continued radiologic advancements have successively improved diagnostic efficacy in the evaluation of spinal disk disease. While these methods have been directed chiefly toward the elucidation of posterior disk extrusion (PDE), occasional publications have addressed the diagnosis of anterior disk extrusion (ADE) (i.e., anterior to the confines of the neural foramen) and central disk extrusion (CDE) (i.e., into or through the vertebral body itself) [1-3]. This report details the potential of MR to reveal such extrusions and examines the pathways of pain mediation and autonomic dysfunction engendered by these lesions within the lumbar vertebral column.

## Materials and Methods

A random retrospective review was undertaken of 250 MR examinations of the lumbosacral spine on adult subjects completed during the preceding year. These studies were acquired on 0.35-T Diasonics and 1.5-T Philips or General Electric units. Intermediate and T2-weighted

This article appears in the March/April 1989 issue of *AJNR* and the June 1989 issue of *AJR*.

Received January 13, 1988; accepted after revision November 1, 1988.

Presented at the annual meeting of the American Society of Neuroradiology, Chicago, May 1988.

<sup>1</sup> MR Imaging Laboratory, Huntington Medical Research Institutes, 10 Pico St., Pasadena, CA 91105.

<sup>2</sup> Present address: Neuroradiology Section, University of Texas Health Science Center, 7703 Floyd Curl Dr., San Antonio, TX 78284-7800. Address reprint requests to J. R. Jenkins.

*AJNR* 10:219-231, March/April 1989  
 0195-6108/89/1002-0219

© American Society of Neuroradiology



spin-echo acquisitions were performed in the sagittal and axial planes with 5- and/or 3-mm-thick sections. The system of classification divided the extrusions into three major categories: anterior and posterior peripheral disk extrusions (with the lateral border of the neural foramen used as the boundary) and central extrusions into or through the vertebral body itself. Further subdivisions were used to clarify the vertebral level and the precise radial direction of anterior or posterior extrusion (midline, direct lateral, or antero- or posterolateral). The criteria used in this series for diagnosis of ADE and PDE included two parameters: (1) *focal* extension of high/mixed-intensity disk substance beyond the peripheral margin of the vertebral body, resulting in a balloon configuration with a neck indicating complete annulus rupture and disk extrusion (Fig. 1), and (2) further extension of the mixed-intensity disk fragment superiorly or inferiorly away from the intervertebral disk space, signifying migration (Fig. 2) [4-6]. CDEs were classified as (1) a focal rounded, or square-shaped extrusion of disk substance into the adjacent vertebral body synonymous with the so-called Schmorl node (Fig. 3) and (2) a transosseous extrusion of disk material obliquely through the corner edge of the vertebral body (also termed a limbus vertebra) or an extreme peripheral trans-vertebral extrusion resulting in a distracted ring epiphysis fragment (designated here as an epiphyseal avulsion) (Fig. 4) [7-9].

The term *herniation* is not used in this classification system, since it is not always possible to differentiate between complete and incomplete herniation on MR. The absolute term of *disk extrusion* is

chosen instead. *Focality* is defined as a localized outward convex contour of the disk margin in the axial plane, extending peripherally beyond the border of the remainder of the intervertebral disk for a total of less than 25% of the entire disk circumference.

None of the patients in this series underwent surgical excision of the demonstrated ADE or CDE. As the majority of the patients in this retrospective review were referred from outside institutions, only fragmentary follow-up was possible on the further care of subjects with PDE.

As an adjunct to this study, and in an effort to place the radiographic findings into a clinical context, the charts of 20 patients with isolated ADEs or CDEs were reviewed. Only ADEs and CDEs were chosen for this small review so that there would be no direct spinal-nerve-root involvement to overlay the element of presumably relatively pure vertebrogenic symptomatology.

## Results

Of 250 MR examinations, 145 subjects (58%) demonstrated 236 extrusions, leaving 105 negative studies (42%). Of these 236 extrusions, 69 (29.2%) were ADEs, 34 (14.4%) were CDEs, and 133 (56.4%) were PDEs. The peripheral extrusions revealed 82 midline PDEs, 51 posterolateral PDEs, 32 midline ADEs, 34 anterolateral ADEs, and three direct

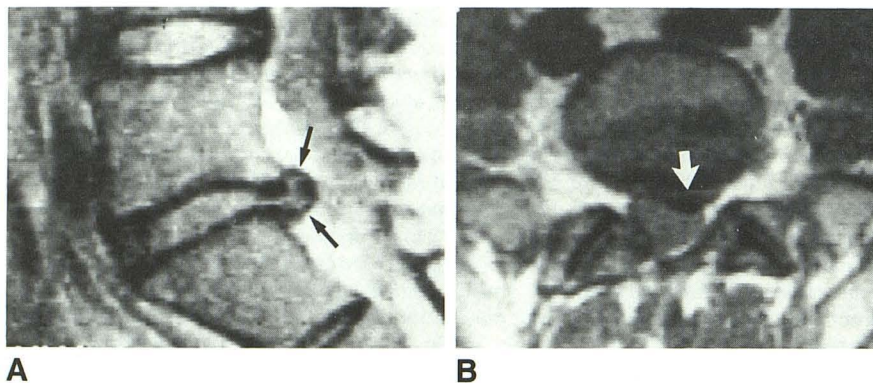


Fig. 1.—Posterior disk extrusion.  
A, Sagittal image shows extension of high/mixed-intensity disk substance beyond peripheral margin of vertebral endplate resulting in balloon configuration (arrows).  
B, Axial image shows focal nature of extrusion (arrow).

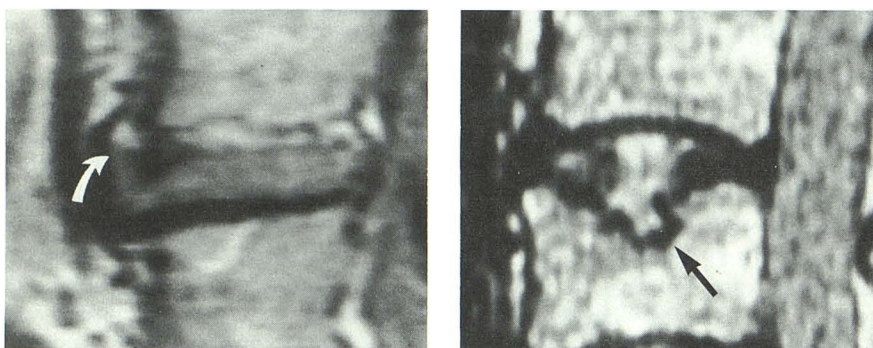


Fig. 2.—Anterior disk extrusion with migration. Sagittal image shows extension of mixed-intensity extruded disk fragment cranial from disk space (arrow).

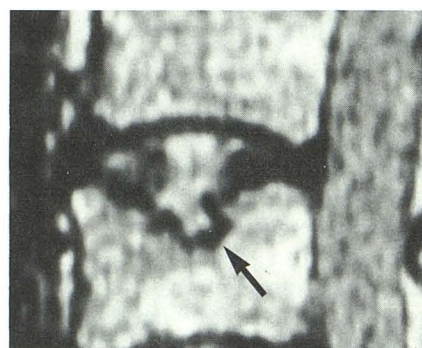


Fig. 3.—Schmorl node. Sagittal section reveals typical focal intraosseous extrusion of high-intensity central disk substance into adjacent vertebral body (arrow).

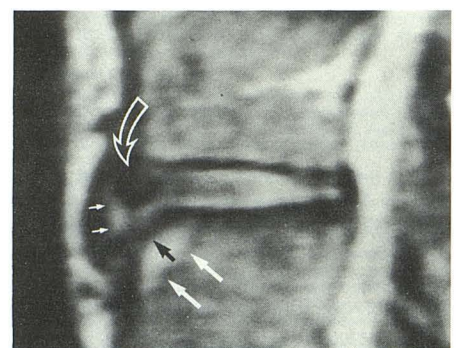


Fig. 4.—Peripheral transosseous epiphyseal avulsion-extrusion. Sagittal image shows avulsed epiphyseal site (black arrow) associated with adjacent high-intensity bony reaction (large solid white arrows), as well as retraction of annular fibers together with low-intensity epiphyseal fragment (open arrow). High-intensity extruded disk fragment is identified beneath anterior longitudinal ligament (small solid white arrows).



lateral ADEs. The total of 34 CDEs represented 26 Schmorl nodes and eight limbus-type extrusions. Of the patients with multilevel lesions, 15 had extrusions at multiple anterior levels, nine at multiple central levels, and 24 at multiple posterior levels. The types of extrusions relative to specific disk levels are summarized in Table 1.

Significant numbers of subjects revealed "isolated" extrusions falling into only one of the three major categories. In this regard, 28 patients (19.3%) of the total 145 with extrusions had isolated ADEs at 39 levels, 13 patients (9%) had isolated CDEs at 17 levels, and 72 individuals (49.7%) had isolated PDEs at 91 levels. This left 22.1%, or 32 subjects with mixed directional extrusions at *different* levels. A separate classification of multivectorial extrusion, or concomitant PDE, CDE, and/or ADE at the *same* intervertebral level, included 18 patients (12.4%) at 21 (9.8%) of a total 215 involved levels. A high frequency (81%) of multivectorial extrusions occurred at the L3–L4/L4–L5 levels. In addition, a

single case each was found of ADE concomitant with antero- and retro-listhesis at the L5–S1 level (Fig. 5). No PDEs or CDEs were identified at levels of spondylolisthesis.

A total of 14 levels with ADE demonstrated disk fragment migration away from the disk space with four migrating cranial and 10 caudal. Of eight levels with PDE manifesting migration, one migrated cranially and seven caudally.

Longitudinally within the lumbar spine, PDE was statistically most common caudally, ADE and limbus-type extrusions were most prevalent in the midlumbar region, and Schmorl nodes were seen with the greatest frequency cranial in the lumbar spine.

Remarkable detail of normal and pathologic intervertebral disk anatomy was seen frequently. MR definition of peripheral annular fibers, presumably Sharpey fibers, is observed in childhood and is better defined anteriorly (Fig. 6). Initial pathologic change within their coarser, denser anatomic configuration was noted in this anterior, peripheral disk location in

TABLE 1: Summary of Lumbar Disk Extrusions in 145 Subjects

Type of Extrusion	No. (%) by Level					Total
	L1–L2	L2–L3	L3–L4	L4–L5	L5–S1	
Posterior disk extrusion:						
Midline	0	5	7	44	26	82
Posterolateral:						
Right	0	0	2	9	11	22
Left	0	1	2	9	17	29
Subtotal	0	6	11	62	54	133 (56.4)
Central disk extrusion:						
Schmorl node	9	10	6	1	0	26
Limbus	0	4	2	1	1	8
Subtotal	9	14	8	2	1	34 (14.4)
Anterior disk extrusion:						
Midline	3	7	11	10	1	32
Anterolateral:						
Right	2	2	7	2	0	13
Left	1	3	6	5	6	21
Direct lateral	0	0	1	1	1	3
Subtotal	6	12	25	18	8	69 (29.2)
Total	15 (6.4)	32 (13.6)	44 (18.6)	82 (34.7)	63 (26.7)	236 (100)
Multivectorial extrusion <sup>a</sup>	0	2	9	8	2	21

<sup>a</sup> Multivectorial extrusions were not averaged into totals and percentages. (See text for further explanation.)

Fig. 5.—Spondylolisthetic extrusion. Sagittal image shows grade I anterolisthesis with associated anterior disk extrusion (arrows).

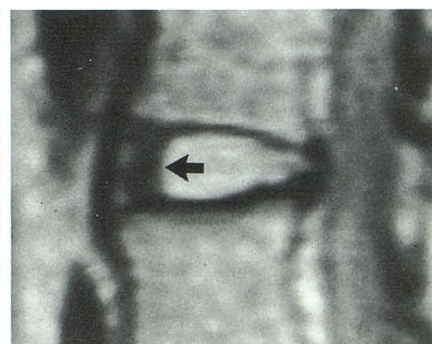
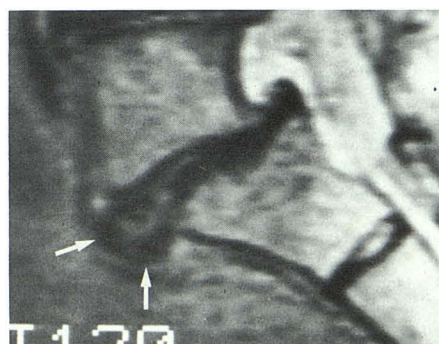


Fig. 6.—Intact peripheral annular fibers (arrow).

5

6



the form of an interruption of normal low intensity by irregular high signal interpreted as shearing or fracturing of the fibers (Figs. 7 and 8).

In frank ADE, the anterior longitudinal ligament was regularly seen to be elevated by the extrusion and suspended over the anterior vertebral border (Fig. 9). On the other hand, direct lateral ADE sometimes demonstrated a poorly defined margin, as no strong ligamentous structures are normally present laterally to confine the disk fragment (Fig. 10).

ADE of presumably long duration engenders osteophyte formation, which has a pincer or clamshell configuration partially enclosing the extruded disk fragment (Fig. 11). This differs from simple degenerative spondylotic osteophytes, which demonstrate predominantly flat, although irregular, inner surfaces.

The chart review of the 20 subjects with anterior or central

extrusions included 15 isolated ADEs and five isolated CDEs (Table 2). Pain in the lower back was noted to be moderate or diffuse in 18 of the 20. The symptoms of pain removed from the lower back were unilateral in five subjects and bilateral in the other 11. Pain was specifically referred, *not* radiating, to the groin in one, the sacroiliac joint in one, the buttock(s) in two, the hip(s) in two, and the posterior/lateral aspect of the lower extremity in 11. In addition to pain, other subjective and objective findings were observed. Two of the subjects had bilateral lower-extremity spasm/cramping. Seven patients experienced nonspecific superficial or deep paresthesias over the buttocks and proximal lower extremities. Finally, a single patient experienced an increased awareness of a periodic bilateral superficial blushing that was accompanied by a sensation of "prickling" heat within the same distribution.



Fig. 7.—Disrupted annular fibers (arrow).

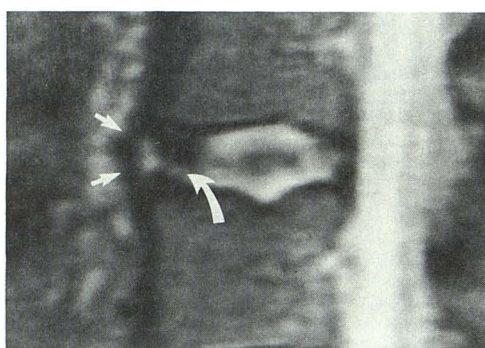


Fig. 8.—Anterior extrusion with ligamentous containment. Extrusion split between fractured fibers is identified as widened area of high intensity interposed between struts of fiber fragments (curved arrow). Disk material is contained within disk space by thick anterior longitudinal ligament (straight arrows).

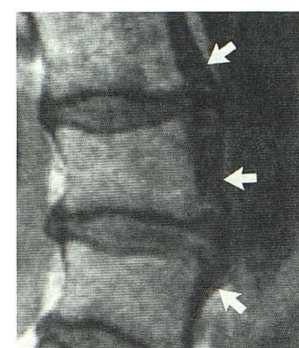


Fig. 9.—Multilevel anterior extrusions. Sagittal image shows multiple anterior disk extrusions with elevation and suspension of thick anterior longitudinal ligament over extruded disk fragments (arrows). Some of the low intensity beneath the ligament is likely due to chronic vertebral reaction to the extrusive ligamentous elevation.

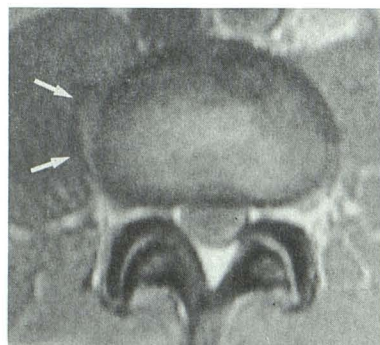
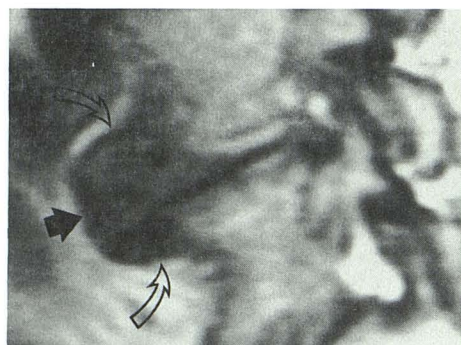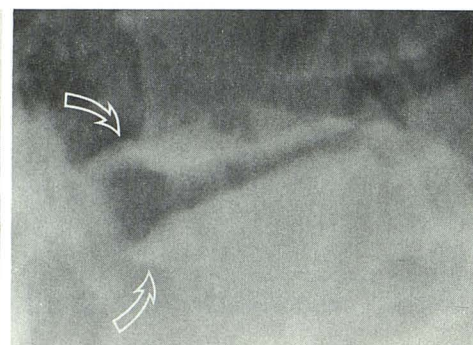


Fig. 10.—Direct lateral extrusion. Axial image shows irregular low-intensity disk extrusion invaginating into psoas muscle on right at L2-L3 (arrows).



A



B

Fig. 11.—Extrusion osteophyte.  
A, Sagittal image shows pincer osteophytes (open arrows) partially embracing extruded disk fragment (solid arrow) in clamshell configuration at L4-L5 level.  
B, Conventional radiograph at same level shows extrusion osteophytes (arrows).



**TABLE 2: Retrospective Clinical Summaries in 20 Random Subjects with Anterior or Central Disk Extrusions**

Type of Extrusion and Case No.	Age	Gender	Level(s)	Signs/Symptoms
Anterior disk extrusion:				
1	63	F	L1-L2, L2-L3	Low-back pain, bilateral hip pain
2	53	F	L5-S1	Low-back pain, right lower-extremity pain
3	63	F	L2-L3, L3-L4	Low-back pain, bilateral hip pain
4	58	F	L1-L2	Low-back pain, right sacroiliac pain
5	43	F	L3-L4	Low-back pain, bilateral lower-extremity pain
6	62	M	L1-L2, L2-L3	Low-back pain, right lower-extremity pain and paresthesias
7	47	M	L5-S1	Low-back pain, bilateral lower-extremity pain
8	58	F	L3-L4, L4-L5	Low-back pain, bilateral lower-extremity paresthesias
9	75	M	L3-L4, L4-L5	Low-back pain, bilateral lower-extremity pain and muscle spasm
10	60	F	L3-L4	Bilateral lower-extremity paresthesias
11	51	M	L4-L5	Bilateral buttock pain
12	47	M	L3-L4	Low-back pain, left lower-extremity pain and paresthesias
13	44	F	L4-L5	Low-back pain, left lower-extremity pain
14	28	F	L4-L5	Low-back pain, bilateral buttock pain, bilateral lower-extremity pain, paresthesias, and pallor/blushing
15	55	M	L1-L2	Low-back pain, bilateral lower-extremity pain
Central disk extrusion:				
16	67	F	L2-L3	Low-back pain, bilateral lower-extremity pain
17	31	M	L1-L2, L2-L3	Low-back pain, bilateral groin pain
18	71	M	L1-L2, L2-L3	Low-back pain, bilateral lower-extremity paresthesias
19	32	M	L1-L2, L2-L3, L3-L4, L4-L5	Low-back pain, bilateral lower-extremity paresthesias and muscle spasm
20	50	M	L2-L3, L3-L4	Low-back pain, bilateral lower-extremity pain

## Discussion

One of the goals of this study was to evaluate the varying degrees and directions of intervertebral disk extrusion. The highest incidence of ADE in the mid-lumbar spine contrasts with the distribution of PDE that tends to involve the lower lumbar levels. In regard to PDE, most certainly this relates to a difference in stress mechanics caudally with increasing ventral angulation at the lumbosacral junction. More weight is concentrated over the posterior regions of the disk at these lower levels, and therefore the major compacting stresses are aimed posteriorly. In addition, increased potential range of motion caudally may contribute to increased pathologic change at these disk levels. In the mid-lumbar region, however, these forces may be reversed, as forward bending

exaggerates intrinsic disk pressures as well as anteriorly placed stress, possibly leading to an increased incidence of single and multilevel extrusion directed toward the apex of the lumbar lordotic curve [10, 11].

Multivectorial extrusions (i.e., at the same disk level but in different peripheral directions) represent an unexpected phenomenon. Two possible mechanisms may explain the occurrence of these lesions: (1) simultaneous extrusions in different directions at the time of initial incident, or (2) after the initial extrusion, granulation tissue enters the area of injury along with fibrosis resulting in a certain degree of healing, which may effectively "seal" the rupture. With an ensuing traumatic event, then, an extrusion occurs in a different direction [12].

Regardless of the cause of multivectorial extrusion, the total of 21 levels observed indicates a weakness in the



intervertebral disks involved. This tendency toward disk extrusion can be explained on the basis of the dynamic biomechanics of the spinal column [10, 11]. The disks that manifested the greatest multivectorial extrusion, and thus the highest intrinsic extrusive tendency, were the L3-L4 and L4-L5 levels, the two totaling 81% of the lumbar levels with multivectorial extrusions.

The total number of disk extrusions in all directions revealed that the L4-L5 level had the highest in absolute number (34.7%). In decreasing frequency, the L5-S1 level was followed by L3-L4, L2-L3, and finally L1-L2.

A number of CDEs occurred in the younger age group. This is likely due to the fact that the annular fibers themselves are intact and strong in youth with firm anchoring in the adjacent vertebrae [13]. In a given patient, the cartilage endplate overlying the vertebral bodies centrally may be the weaker of the two structures surrounding the nucleus pulposus [10]. Therefore, the disk extrusion preferentially takes place through the cartilage and into the contiguous vertebral body, resulting in a Schmorl node. Although not proved in this patient group, the cases of multiple Schmorl nodes noted superiorly in the lumbar spine may be related to Scheuermann juvenile epiphysitis [9]. In fact, the majority of subjects with multiple upper lumbar Schmorl nodes also had evidence of adjacent nodes extending into the usual location in the thoracic spine. On the other hand, isolated lumbar Schmorl nodes were unassociated with similar thoracic disease. Nevertheless, the rarity of Schmorl nodes caudally within the lumbar spine would seem to indicate a definite vulnerability of the upper lumbar segments to intraosseous disk extrusion, quite possibly because the cartilaginous endplates are simply stronger caudally.

The limbus-type CDE also occurred in relatively higher frequency in the lower age group. However, the larger transosseous fracture/extrusion resulting in a classic limbus vertebra was seen only once in this series. Rather, small paraannular avulsions of the ring epiphysis were observed more commonly. The strong Sharpey fibers are very firmly embedded within the epiphysis of the peripheral endplate and form a bond with it that in youth is stronger than the vertebral body itself. This finding was observed only anteriorly and anterolaterally and not posteriorly, apparently because the epiphysis of the vertebral endplate does not exist posteriorly [13]. In a distribution similar to that of ADEs and probably for the same reasons, limbus-type CDEs were found to be most common in the region of the apex of the lumbar lordotic curve.

As a disk extrusion is a traumatic event, it will necessarily incite a reaction at the insertion of Sharpey fibers into the vertebral epiphysis. Anteriorly or laterally, the net chronic result may be the formation of a "pincer"-type osteophyte between adjacent vertebral bodies embracing the extruded disk material, ultimately resulting in the pathologic picture of "spondylosis deformans" [14].

The physical manifestations of PDE have been described extensively in the literature; however, ADE may also be associated with distinct clinical symptomatology. The features of this disease process were originally described in a case report by Cloward [1] in 1952 and include (1) low-back pain of acute onset, (2) possible relation to a specific traumatic

incident, (3) referred pain perceived in the buttock and/or proximal lower extremity(ies), and (4) no evidence of neurologic findings to suggest direct compression of lumbar or sacral nerve roots.

The anatomic basis for diskogenic and therefore vertebro-genic pain generated by all disk extrusions rests partially with somatic fibers originating from the recurrent meningeal nerve (sinuvertebral nerve of Luschka) supplying the posterior longitudinal ligament, the meninges, the blood vessels, the posterior extent of the outermost fibers of the annulus fibrosus, a portion of the periosteum of the vertebral bodies, and the underlying bone. In addition, a small branch from the ventral ramus of the somatic spinal nerve root directly innervates the posterolateral aspect of the vertebral body and related tissues for a variable distance. Any traumatic involvement of these structures may incite well-circumscribed *local somatic pain* due to this somatosensory innervation (Figs. 12 and 13A), and due to the direct nature of the afferent inflow from the segment of origin into the CNS via the somatic spinal nerves (Fig. 13A) [15, 16, 18-22].

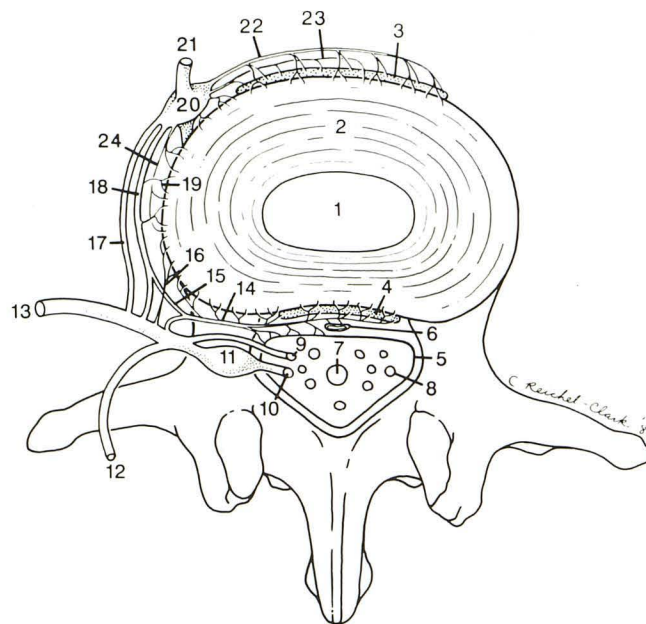


Fig. 12.—Schematic diagram of innervation of anterior spinal canal and structures of anterior aspect of spinal column (modified from [15-17]: 1 = nucleus pulposus; 2 = annulus fibrosus; 3 = anterior longitudinal ligament/periosteum; 4 = posterior longitudinal ligament/periosteum; 5 = leptomeninges; 6 = epidural vasculature; 7 = filum terminale; 8 = intrathecal lumbosacral nerve root; 9 = ventral root; 10 = dorsal root; 11 = dorsal root ganglion; 12 = dorsal ramus of spinal nerve; 13 = ventral ramus of spinal nerve; 14 = recurrent meningeal nerve (sinuvertebral nerve of Luschka); 15 = autonomic (sympathetic) branch to recurrent meningeal nerve; 16 = direct somatic branch from ventral ramus of spinal nerve to lateral disk; 17 = white ramus communicans (not found caudal to L2); 18 = gray ramus communicans (multilevel irregular lumbosacral distribution); 19 = lateral sympathetic efferent branches projecting from gray ramus communicans; 20 = paraspinal sympathetic ganglion (PSG); 21 = paraspinal sympathetic chain; 22 = anterior paraspinal afferent sympathetic ramus(i) projecting to PSG; 23 = anterior sympathetic efferent branches projecting from PSG; 24 = lateral paraspinal afferent sympathetic ramus(i) projecting to PSG. (Note.—Afferent and efferent sympathetic paraspinal branches/rami may be partially combined in vivo.)



However, many of the afferent fibers of the anterior and anterolateral disk and paradiskal structures project immediately to the paraspinal sympathetic ganglia. Polymodal afferent pain fibers to the sympathetic ganglia have been identified in all of the anterior vertebral structures except the nucleus pulposus to include the anterior longitudinal ligament, the most peripheral laminae of the anulus fibrosus, the periosteum of the vertebral body, and the vertebral body itself [15, 17–19]. There is also a major autonomic branch extending posteriorly from the sympathetic ganglion or gray ramus communicans to join the recurrent meningeal nerve [16, 21, 23]. Thus, the *entire* disk periphery, and indeed the whole vertebral column, is supplied with afferent sympathetic fibers. This extensive network was initially fully detailed by Stilwell [17] and is known as the *paravertebral autonomic neural plexus* (Figs. 12 and 14).

Depending on the vertebral level, some of these afferent fibers traverse the sympathetic ganglia and enter the ventral ramus of the somatic spinal nerve via the white ramus communicans. Subsequently, these fibers pass into the dorsal root ganglion where the cell bodies lie. The dorsal root then carries the fibers as they enter the dorsolateral aspect of the spinal cord within the tract of Lissauer, adjacent to the dorsal-horn gray matter.

The embryologic origin and anatomic path of these neural elements within the autonomic nervous system contribute to

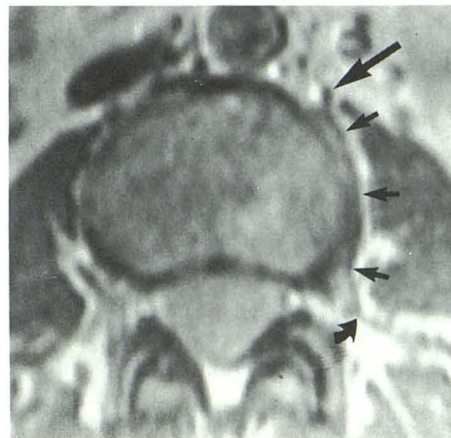


Fig. 14.—Paravertebral autonomic plexus. Axial image at L3 shows sympathetic ganglion on left at anterior sulcus of psoas muscle and vertebral body (partially obscured by chemical shift artifact) (large straight arrow), contiguous rami communicantes (small straight arrows), and junction of latter with ventral ramus of spinal nerve (curved arrow).

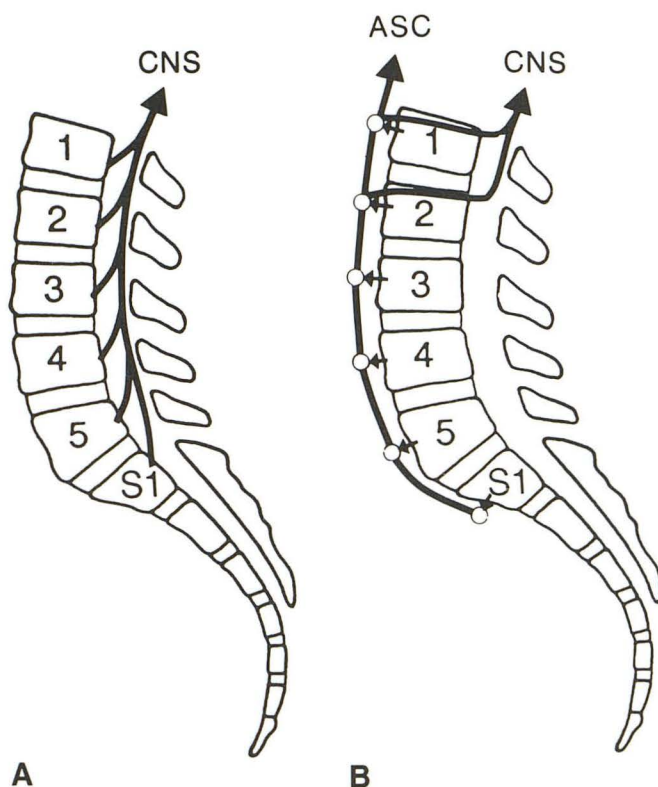


Fig. 13.—Lumbar afferent sensory patterns.

A, Direct somatic afferent inflow into CNS from branches of somatic spinal nerves at all levels.

B, Ascending autonomic (sympathetic) afferent inflow diversion into CNS of sympathetic fibers from S1 to L2 vertebral levels. ASC = ascending sympathetic chain.

the imperfect somatic localization of pain. The conscious somatotopic perception of somatic pain origin is chiefly accomplished by the point of spatial entry of afferent impulses/axons into the CNS. Some entering afferent fibers may result in appropriately localized symptomatology while others are involved with important autonomic reflex functions. However, different afferent fibers will result in the conscious perception of *distant referred pain*. This pain is referred to the region corresponding roughly to the somatic distribution of the afferent fibers of the spinal nerve with which the afferent sympathetic fibers enter the spinal canal.

Referred pain is not the classic, well-discriminated, centrifugally radiating *neurogenic pain* within the cutaneous dermatome as is seen in the radiculopathy of nerve-root compression often associated with PDE [9]. Rather, it is a diffuse, deep, dull, aching, nonspecific pain perceived in the referred pain "zones of Head," which are based loosely on the concept of "somatomes." An example of a classic, well-known Head zone is that of the ischemic myocardium, in which the patient may experience centrifugal pain within the left shoulder, arm, root of the neck, and/or jaw. In the current context, the referred pain zones mediated by primary afferent fibers originating in spinal elements seem to be largely confined to limited regions within the pelvic structures, the lower extremities, and possibly the spine itself and surrounding soft tissues [20, 24–29].

Simply stated, a somatome is defined as a field of somatic and autonomic innervation that is based on the segmental embryologic expression of the somatic tissues [30]. The complete somatome is composed of three elements: the skin (dermatome); the deep musculature (myotome); and the bones, joints, and ligaments (sclerotome). The term *somatic* indicates that these tissues embryonically originate from the precursor somites [31]. Therefore, tissues originating from the same somite will also have a common neural circuitry and thus a common pathway of referral. Pain is distantly referred to these projection fields of innervation within the lumbosacral



somatomes. The conscious perception of that referred pain is within the zones of Head, which are irregular, constricted, asymmetric, and superimposed as well as somewhat inconsistent from subject to subject (Fig. 15) [27]. Importantly, it must be noted that these regions of vertebrogenic pain referral are found in much the same physical distribution as that seen in true radicular neurogenic sciatica. That the *origin* of referred pain is a process intimately involving the peripheral nervous system and that the *perception* of referred pain is a mechanism of the CNS is confirmed by the experimental finding that local anesthesia of the region of impulse origin (spine) abolishes the pain referral; however, anesthesia of the site of referral (zone of Head) does not consistently eliminate this pain [33, 34].

The ill definition of the pain and its referred nature are further complicated by the distribution patterns of the sympathetic afferent fibers of the spine, which overlap craniocaudally as well as across the midline. Stated differently, there is no true anatomic midline or accurate segmental nature of the

lumbosacral paravertebral autonomic (sympathetic) nervous system. In addition, once afferent fibers enter the paraspinal sympathetic ganglia, they do not always exit directly into the nearby somatic ventral ramus of the spinal root. These fibers may instead ascend to a more craniad level before entering the spine. Afferent fibers can, in fact, only join the spinal nerves and subsequently the CNS via the *white rami communicantes*. An important and anatomically confirmed pattern is that there are *no* white rami communicantes below the L2 vertebral level [35]. Therefore, any sympathetic afferent fibers from the lower lumbar and upper sacral region must ascend within the sympathetic chain to, or craniad to, the L2 nerve root before they can enter the spine (Fig. 13B). Because of this ascending sympathetic afferent diversion, sympathetic pain impulses emanating from the lumbosacral regions not having white rami communicantes (below L2) will be referred to the somatome corresponding to the spinal entry level of the afferent fiber at the L2 segment or above. Thus, the conscious perception of sympathetic mediated pain

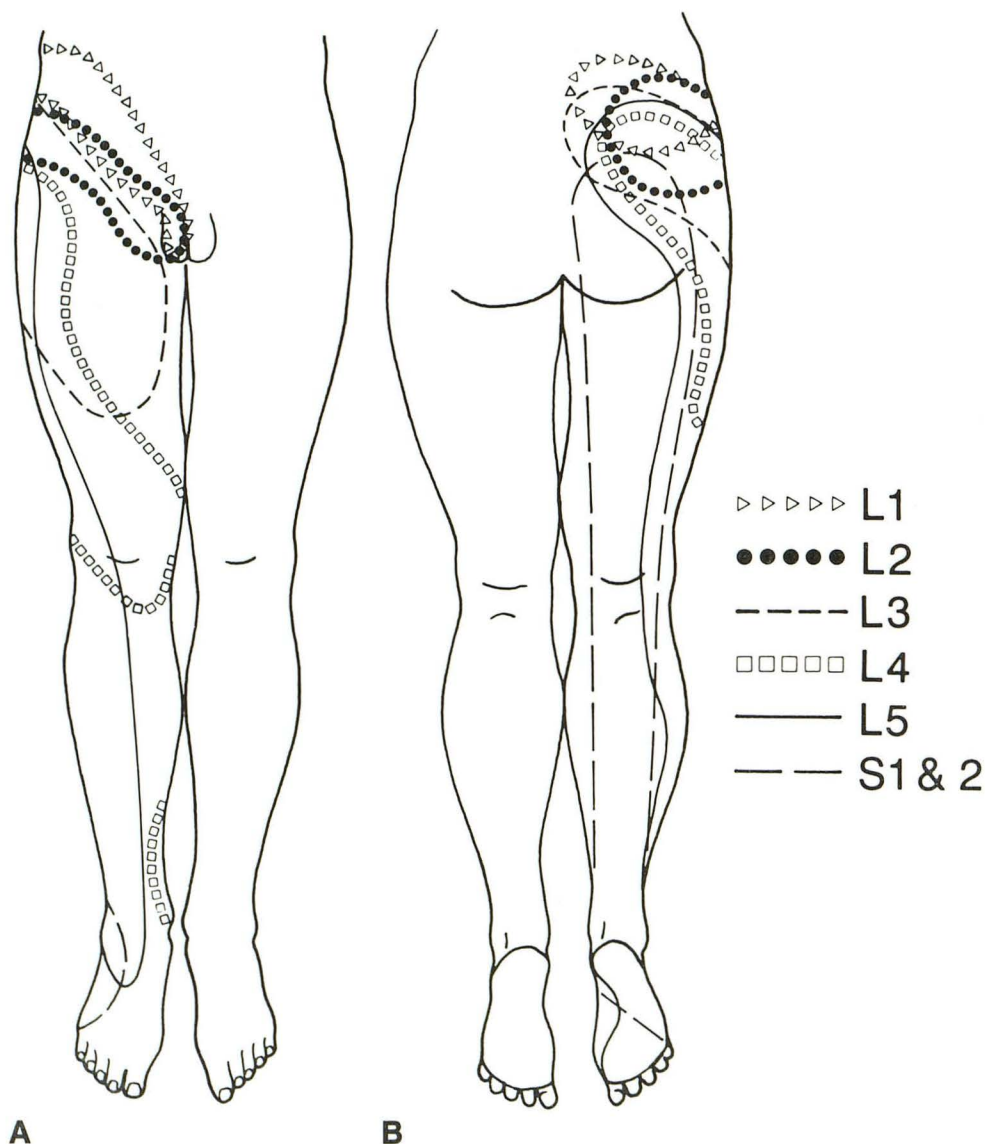


Fig. 15.—Right unilateral composite of lumbosacral Head zones of pain referral and proposed reflex autonomic dysfunction referral from segmental spinal levels. Anterior (A) and posterior (B) aspects. Note constricted, superimposed, and skipped regions. (Modified from [32].)



may be misregistered and referred to a somatome different from what its origin would have indicated, possibly resulting in summing of pain sensation due to superimposition of afferent fiber input [33].

This would explain the partial segmental superimposition of the zones of Head in the lumbosacral region, as depicted in Figure 15. The posteriorly overlapping areas of commonest centrifugal pain referral from *all* lumbar levels in fact fall largely within the superficial somatomes of the upper lumbar spinal nerves. Nevertheless, these effects are not precise, and the referral patterns are rarely completely homosegmental, but instead spread over one or several contiguous segments. However, predominantly extrasegmental pain referral might be termed aberrant, as little or none of the site of impulse origin is within the same embryologically defined somatome as the referred effect, this being a consequence of the ascending autonomic lumbar afferent inflow diversion to the L2 level.

Such unusual lumbosacral innervation patterns may also engender *local referred pain* to the spine itself and its surrounding tissues. Conscious pain originating in the spinal column is referred to the zones of Head, which are linked with vertebral segments and spinal nerves that coincidentally have afferent somatic projection fields within spinal and paraspinal structures. In other words, an integral component of the sclerotomes of spinal nerves includes the spinal elements themselves. In this manner, although the pain is not referred to the precise point of origin in the spine, it is still perceived diffusely in the region of the low back. The local referred, distant referred, and local somatic pain constitute vertebro-genic pain, which, when combined with the sometimes concurrent radiating radicular neurogenic pain, seems to explain the parallel systems operating in the spinal column responsible for the complex syndromes of spinal pain [36].

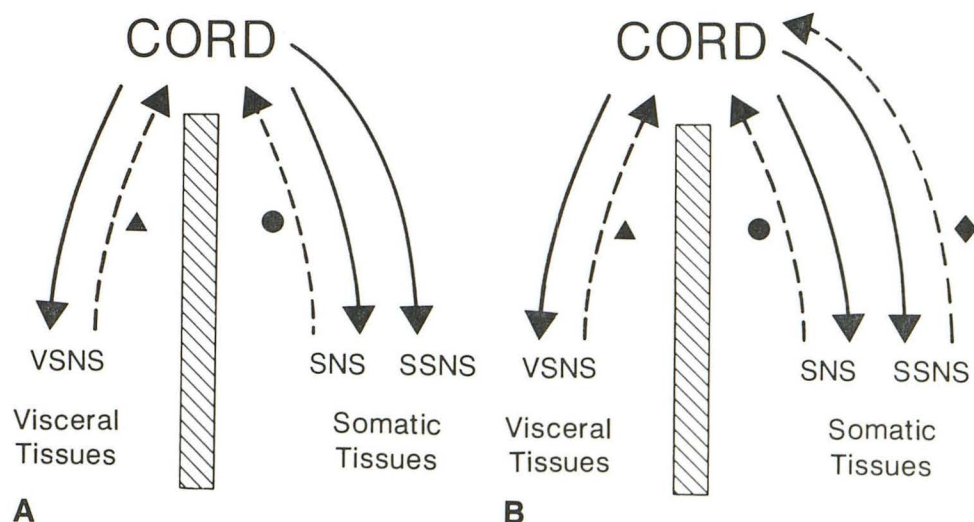
A close inspection of Figure 15 reveals areas of unsuperimposed pain referral extending far distally in the lower extremities. This is explained by the fact that there is direct sympathetic afferent inflow into the S2–S4 pelvic somatic nerve roots, and also because the innervation of spinal struc-

tures may originate from as few as three and as many as five different adjacent spinal levels [20]. Thus, direct sacral inflow and therefore direct pain referral may obtain over wide areas of the lower lumbosacral spine. Stated differently, even though there is a referred component to the pain perception, it will still be largely homosegmental [37, 38]. This might be termed appropriate pain referral, as the site of impulse origin is within the same developmentally determined somatome as the referred effect. The reason for the gaps in somatic coverage in the zones of Head is suggested by the fact that somatic tissues are not as densely populated with autonomic fibers as they are with afferent and efferent somatic fibers. As a result, the autonomic projection fields may therefore be somewhat contracted. The confining, superimposing effects of the ascending lumbar sympathetic afferent diversion may also be a major factor. These anatomic concepts help to clarify some of the peripheral mechanisms responsible for the rather nebulous fields characteristic of the zones of Head.

It may be, as the foregoing seems to indicate, that the entire perception of referred pain is handled within the autonomic (sympathetic) somatotopic organization of the CNS running in parallel with somatic afferent fibers. Embryologically, the peripheral neurologic system follows two patterns. The somatic nervous system has one distribution within the somatome. However, the autonomic nervous system develops along two different pathways. One is within visceral structures and is sometimes referred to as the visceral autonomic nervous system. The other pathway is within the somatic tissues in a distribution similar to that of the peripheral somatic nerves, although possibly not along such discretely demarcated lines. Just as there are functional sympathetic efferent connections within somatic tissues, so too must there be sympathetic afferent links to the CNS in order to complete autonomic reflex arcs. Therefore, functionally at least, the existence of "somatic" afferent sympathetic fibers is proved (Fig. 16). In fact, the presence of these peripheral autonomic afferent fibers within somatic tissues has been demonstrated clinically [39]. Since both visceral and somatic tissues are innervated by the sympathetic nervous system, and assuming

Fig. 16.—Schematic of peripheral nervous system.

A, Current understanding.  
B, Proposed configuration.  
Efferent pathways (solid arrows), afferent pathways (broken arrows), visceral tissue sympathetic afferent fibers (triangles), somatic tissue somatic afferent fibers (circles), and proposed somatic tissue sympathetic afferent fibers (diamonds). VSNS = visceral sympathetic nervous system; SNS = somatic nervous system; SSNS = somatic sympathetic nervous system.





that both tissues are served by afferent limbs, the CNS may then perceive an impulse origin within either tissue on the basis of a central embryologically predetermined linkage. However, the CNS may not be able to accurately discriminate spatially between the visceral and the somatic ramifications of this network in certain circumstances. In this way, a visceral sympathetic afferent stimulus may erroneously be consciously perceived as arising within the somatic sector of the sympathetic sensory projection field, and by definition is thus referred to this location. The converse of this might also be true.

This concisely explains the finding of referral of visceral sympathetic stimuli to the somatic sympathetic afferent projection field (and vice versa), thus defining the zones of Head predominantly or entirely as a phenomenon of a developmentally dichotomous sympathetic nervous system. In this functional context, referred actions and perceptions are an expected capacity of the autonomic (sympathetic) nervous system, rather than a truly abnormal phenomenon. Hence, the ascending afferent lumbar sympathetic diversion accounts for not only the referred effects and pain but also their *extrasegmental* CNS misregistration and mismatched *superimposition* within the lumbosacral zones of Head [38].

Only so much can be understood within the framework of the peripheral nervous system, and therefore CNS mechanisms of pain referral must also be considered. Experimental anatomic data suggest that somatic and visceral autonomic afferents may have the same or some of the same central connections at the level of the spinal cord, thalamus, and sensory cortex [20, 29, 38, 40, 41]. One simplified theory, referred to above, for the occurrence of referred pain states that since some of the same central pathways are shared by the converging visceral and somatic afferent systems, the CNS cannot precisely distinguish between the two origins of sensory input. Another hypothesis indicates that since the somatomes are continually relaying noxious stimuli, as op-

posed to the viscera, through a process of pattern recognition, the CNS attributes most of the segmental afferent inflow to somatic origins regardless of the true site of the stimulus [38, 40]. There seems to be no question, however, that some degree of modulation of afferent input from any peripheral source occurs at the level of the spinal cord [20, 42].

The actual problem of the somatotopic misregistration, whether homo- or extrasegmental, thus seems to lie at the level of the spinal cord and above. As noted, complications necessarily arise in stimulus origin localization when multiple afferent systems converge at the same spinal nerve/cord level. There is a definite somatotopic organization of the spinal cord with reference to entering afferent fibers. Not only is the level of cord entry important but so is the point of termination of the fiber spatially within the cord gray matter at any particular level. Somatic afferent fibers largely terminate within laminae II, III, and IV, while visceral afferent fibers end in laminae I and V and within the ventral horn substance (Figs. 17A and 17B). It is a basic observation that the cells on which the visceral afferents terminate are known as viscerosomatic neurons. The reason for this is that many of these neurons are driven by stimuli both from the somatic as well as the visceral tissues [29]. This then would support the concept of discrete sympathetic afferent systems within visceral and somatic tissues. In fact, some "indeterminate" somatic afferents terminate within the visceral field of the cord (on the same viscerosomatic neurons noted above), which may indicate that these neural structures are in actuality the postulated somatic tissue sympathetic afferent fibers (Fig. 17C) [29]. Presumably, many of these somatic sympathetic afferent fibers may never enter the peripheral visceral autonomic pathways but instead travel almost entirely within the somatic nerves of the extremities on their route to the spinal cord. It is only their distinctive, embryonically predetermined points of termination within the gray matter of the cord that distinguish them from nonautonomic somatic afferent fibers.

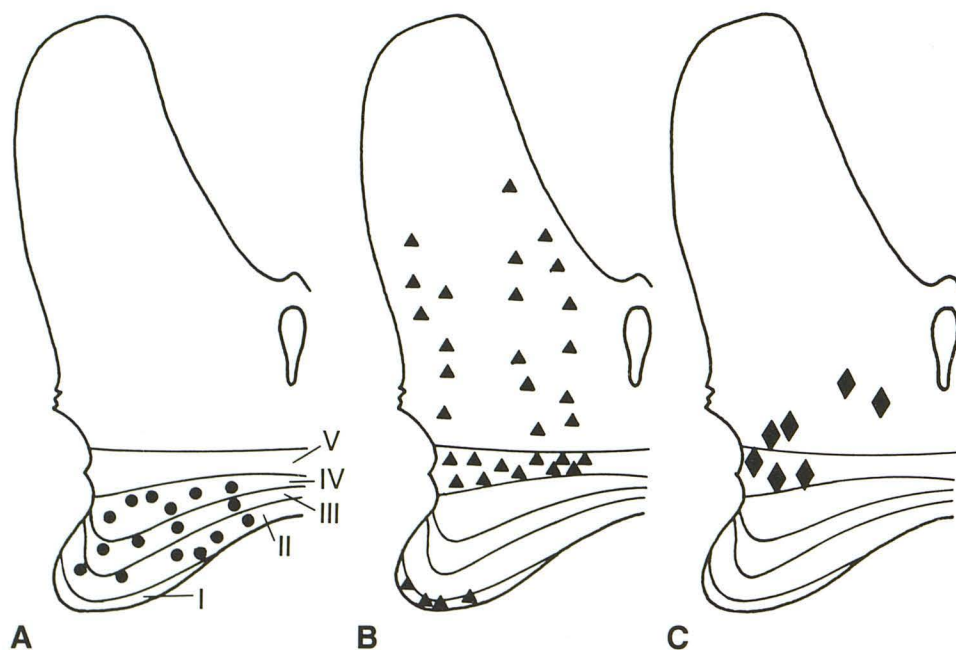


Fig. 17.—Points of termination of visceral and somatic afferent fibers on cord neurons within dorsal and ventral gray matter of right spinal hemicord. I–V = laminae of dorsal horn. (Modified from [29].)

A, Terminations of somatic (somatic tissue sympathetic) afferent fibers on somatic cord neurons (circles).

B, Terminations of visceral (visceral tissue sympathetic) afferent fibers on viscerosomatic cord neurons (triangles).

C, Terminations of somatic (proposed somatic tissue sympathetic) afferent fibers on viscerosomatic cord neurons (diamonds). Note overlapping regions in B and C.



One other complementary theory for referred pain considers the possibility of bifurcating sympathetic afferent fibers, with one limb entering the visceral tissues while the other ramifies within the somatic tissues (Fig. 18) [29, 43–45]. Regardless of whether one or both these mechanisms are functional, the important concept is that of convergence of multiple afferent axons on the same viscerosomatotopic registration region of the CNS, either primarily or via connecting interneurons, which then causes a false mental image of localization of a sensory event. Therefore, neither radiating nor referred pain has its origin in the mismatched areas of perception. Within this definition of central pain perception, both referred and radiated pain fields are thus “imagined” by the CNS.

However, the autonomic nervous system is involved not only with the conscious perception of painful stimuli: A major role of this network is the mediation of subconscious autonomic function via autonomic reflex arcs occurring at the level of the spinal cord, which in turn are influenced by higher CNS levels [20, 29, 40, 46, 47]. Just as the conscious perception of pain may be spatially misregistered, so too may be various autonomic functions. It is known that somatic as well as autonomic fibers both excite or otherwise share the same

interneurons within the spinal cord [40]. Referred autonomic dysfunction of spinal column origin may be represented in the form of aberrant centrifugal vasomotor, pilomotor, and sudomotor activity [38]. Not only positive sympathetic effects may be seen but also reverse or paradoxical effects, presumably due to pre- and/or postsynaptic efferent inhibition by polysynaptic, polyaxonal afferent spinal cord input [20, 40].

These findings are seemingly minor, however, and are much overshadowed by the manifestations of pain. Often apparently disregarded, such autonomic dysfunction was nevertheless recorded in one of the patients who was studied retrospectively. Quite possibly such phenomena may be more common than realized, and could be elicited with greater frequency if the subjects were carefully screened for such abnormalities at the time of examination.

Another finding, that of somatic muscle spasm, is also associated with autonomic function/dysfunction and was seen in two of the subjects studied [20, 29, 33, 34, 38]. This is commonly seen in clinical medicine in the form of abdominal wall rigidity allied with the visceral insult of peritonitis [38, 40]. Skeletal muscle spasm, which may become a painful process in and of itself, is accomplished by an aberrant reflex arc, as in the other autonomic reflex dysfunction described earlier. This type of referred reflex somatic muscle spasm in the lumbosacral myotome, known as a viscerosomatic reflex, must account for this clinically significant symptomatology [47]. The spasm itself may be produced by an arrest of the usual negative feedback mechanisms that ordinarily affect muscular contraction. This could occur because the stimulus does not originate within the area of the effect, the lumbosacral zone of Head, but instead from a distant referral source, the spine. Alternatively, unopposed positive feedback mechanisms may be responsible for the spasm for the same reasons [40].

In all these conditions of autonomic reflex dysfunction, the afferent limb is carried within the paraspinal sympathetic plexus. As discussed previously, largely because of the ascending sympathetic afferent inflow diversion (entering at or above L2) and because of the peculiarities of the autonomic (sympathetic) nervous system (both in its central and peripheral ramifications), there may be a spatial mismatching of otherwise normal autonomic function, causing the efferent effector limb of the arc to occur in the peripheral somatome (Fig. 19). This autonomic dysfunction might include any one or combination of dermal blushing, pallor, piloerection, diaphoresis, or somatic muscle spasm reflecting genuine peripheral signs and symptoms within the lumbosacral zones of Head [38]. The temporal relationship of these physical findings to the genesis of the vertebral lesion is, however, obscure.

An additional referred phenomenon is that of paresthesias of the somatic tissues within the zones of Head [34, 38]. This was observed in seven of the 20 subjects retrospectively reviewed. Presumably the mechanism for this is at the level of the cord and/or above, which unpredictably facilitates (hyperesthesia) or blocks (hypoesthesia) somatic afferent activity within the somatome in response to elevated paraspinal sympathetic afferent inflow [20].

Final considerations involve the general sympathetic outflow, which is occasionally seen clinically and experimentally

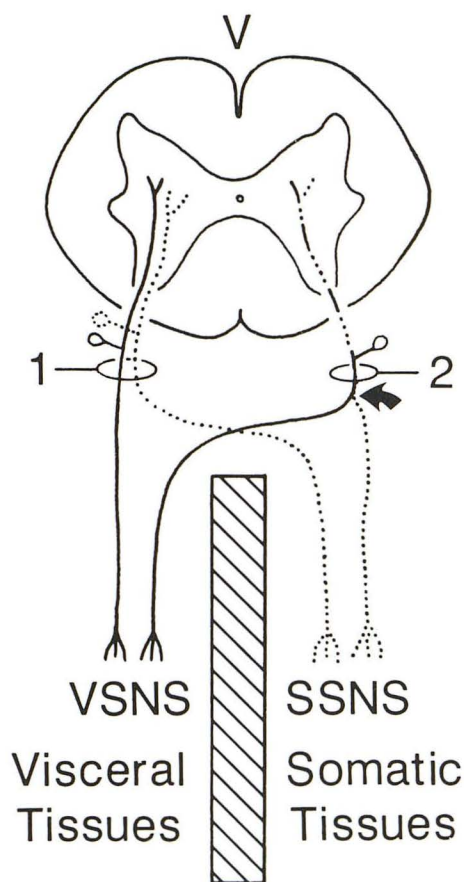


Fig. 18.—General organization of peripheral afferent sympathetic nervous system (hypothetical) [29, 43–45]: 1 = dual afferent axon configuration; 2 = bifurcating (arrow) afferent axon pattern. Visceral sympathetic afferent fibers (solid axons); somatic sympathetic afferent fibers (dotted axons). VSNS = visceral sympathetic nervous system; SSNS = somatic sympathetic nervous system; V = ventral surface of spinal cord.



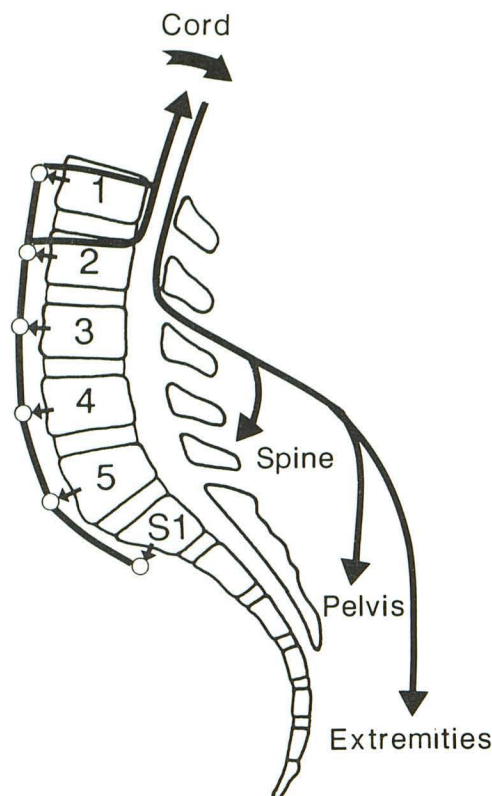


Fig. 19.—Aberrant autonomic reflex arc. Afferent limb is carried within ascending paraspinal sympathetic chain. After synapse in spinal cord, efferent limb is carried within peripheral ramifications of somatic and/or sympathetic components of somatic spinal nerves [47].

in conjunction with acute traumatic stimulation of vertebral elements. This encompasses such viscerosomatic reactions as a change in blood pressure, heart rate, and respiratory rate as well as elevations in alertness accompanied by nausea, all of which are *not* proportional to the severity and extent of the induced pain [16, 29, 34]. These findings were not seen in the small clinical review series, but neither were these parameters carefully evaluated. They may, therefore, occasionally play a role in the overall symptom complex during certain phases of spinal disease.

In closing, a statement should be made concerning primary disease of the posterior spinal elements (e.g., the facet joints and spinous processes) and the regional extraspinal tissues to include the paraspinal structures, the pelvis, and the lower extremities. It must be remembered that abnormalities in these areas may mimic signs and symptoms within the spinal column itself and/or within the somatic distribution of the sciatic nerve. These considerations must be entertained in any evaluation of spinal disease, and may in fact "contaminate" the results of any study concerned primarily with the complex aspects of intervertebral disk disease.

## Summary

In common practice, a far-reaching, perplexing, combined somatoautonomic syndrome is known to stem from spinal disease that includes varying degrees of (1) local vertebro-

genic somatic pain, (2) centrifugal vertebro-genic referred pain, (3) centrifugal neurogenic radiating pain, (4) referred sympathetic reflex dysfunction (diaphoresis, piloerection, vasomotor changes, somatic muscle spasm), (5) somatic reflex dysfunction, (6) somatic muscle weakness, (7) peripheral somatic paresthesias, and (8) generalized alterations in viscerosomatic tone (blood pressure, heart rate, respiratory rate, alertness). The *somatic syndrome* (including 1, 3, and 5–7 above) is mediated within the main somatic spinal nerve roots, or direct somatic branches thereof, in conjunction with the CNS. A unified theory is proposed that indicates that the *autonomic syndrome* (2, 4, 7 and 8 above) is predominantly if not entirely mediated within the peripheral and central ramifications of the sympathetic nervous system.

On the one hand, there is a single afferent and efferent arborization of the somatic nervous system that is within the somatic tissues. On the other hand, the sympathetic nervous system has efferent connections within both visceral and somatic tissues. In addition, there are afferent sympathetics within the visceral tissues, and research data support the hypothesis that somatic tissue sympathetic afferents exist as well. Experimental evidence indicates that both somatic and sympathetic nervous system afferents terminate largely within separate regions of the gray matter of the spinal cord. Incoming sympathetic impulses from distantly separated visceral and somatic sources may drive the same viscerosomatic cord neurons by two methods. First, two different sympathetic afferent fibers, one of visceral origin and the other of somatic origin, may terminate on the same cord neuron or associated cord interneurons. Second, bifurcating afferent fibers, with one limb each ramifying within the somatic and the visceral tissues, may terminate a single shared central axon within the spinal cord gray matter. Either or both these anatomic configurations may be operative. A separate mechanism, such as pattern recognition, may determine whether the source of the stimulus is somatotopically or viscerotopically consciously perceived, or both. This would indicate which direction the pain is referred (i.e., to the visceral or to the somatic tissues), if at all, and in turn whether pain may concomitantly be perceived locally at the site of stimulus origin. Inhibition of impulse input as well as facilitation also occurs at the cord level, which further alters cerebral perception. Craniad to the level of afferent fiber entry into the cord, there is evidence of separate or at least partially discrete ascending spinal tracts for central autonomic (sympathetic) and somatic impulse mediation. Most certainly, this input is in turn modified by higher centers, resulting in varying combinations of local somatic, local referred, and distant referred pain.

Analogous to the analysis of pain mediation, referred autonomic reflex dysfunction occurs because of a common spinal cord neuron convergence of peripheral visceral and somatic afferents. This results in a misregistration of viscerosomatic input, which in turn dictates a consonant mismatching of efferent actions. This is true for both visceral as well as somatic functions and may conceivably be manifested in either or both of the two tissues. Thus, regions of referral, or zones of Head, theoretically may be found in both visceral and somatic tissues. The summed expression of these pain sensations and autonomic actions is further altered in the



lumbosacral region by the ascending afferent diversion within the paraspinal sympathetic chain. Finally, owing to the activation of inflow into the autonomic nervous system, generalized sympathetic outflow occurs that may alter the overall viscerosomatic tone.

Any one or combination of neurogenic and/or vertebrogeic signs and symptoms may be observed in an individual subject. This variety of manifestations may mislead the patient and the physician. As discussed above, this is largely due to related patterns of local and centrifugal distribution of peripheral nerve fibers as well as their complex central connections, which consequently result in a concurrent superimposition of focal and diffuse conscious perceptions and unconscious effects. Although it was not possible in the present retrospective study to accurately match the majority of the MR findings with a precise clinical correlation, in the future this input will surely be an important factor in evaluating the relationships and significance of the somatic and autonomic lumbosacral syndromes in patients with any disease process involving the vertebral column.

#### ACKNOWLEDGMENTS

We thank S. Valdez and J. Murray for manuscript preparation, V. Caullay for manuscript research, the Huntington Medical Research Institutes staff for technical assistance, C. Reichel-Clark for artwork, and S. Valone for photographic reproductions. In addition, we express appreciation to R. Brown for use of selected case material.

#### REFERENCES

- Cloward RB. Anterior herniation of a ruptured lumbar intervertebral disk. *Arch Surg* 1952;64:457-463
- Johansen JG. Demonstration of anterior intervertebral disc herniation by CT. *Neuroradiology* 1987;29:214
- Kozlowski K. Anterior intervertebral disc herniations in children. *Pediatr Radiol* 1977;6:32-35
- Edelman RR, Shoukimas GM, Stark DD, et al. High-resolution surface-coil imaging of lumbar disk disease. *AJNR* 1985;6:479-485
- Modic MT, Pavlicek W, Weinstein MA, et al. Magnetic resonance imaging of intervertebral disk disease. *Radiology* 1984;152:103-111
- Modic MT, Masaryk T, Boumpfhey F. Lumbar herniated disk disease and canal stenosis: prospective evaluation by surface coil MR, CT, and myelography. *AJR* 1986;147:757-765
- Fitzer PM. Anterior herniation of the nucleus pulposus: radiologic and clinical features. *South Med J* 1985;78:1296-1300
- Gelman B, Freiburger RH. The limbus vertebra: an anterior disc herniation demonstrated by discography. *AJR* 1976;127:854-855
- DePalma AF, Rothman RH. Clinical manifestations of lumbar disc syndrome. In: *The intervertebral disc*. Philadelphia: Saunders, 1970:203-248
- White AA, Panjabi MM. *Clinical biomechanics of the spine*. Philadelphia: Lippincott, 1978:1-34, 277-294
- Nachemson A. The load on lumbar disks in different position of the body. *Clin Orthop* 1966;45:107-122
- Hult L. Cervical, dorsal and lumbar spinal syndromes. *Acta Orthop Scand [Suppl]* 1954;17:1-102
- Shapiro R. The herniated intervertebral disk. In: *Myelography*. Chicago: Year Book, 1984:422-496
- Resnick D. Osteophytes, syndesmophytes, and other "sygites." *Postgrad Radiol* 1981;1:217-232
- Edgar MA, Ghadially JA. Innervation of the lumbar spine. *Clin Orthop* 1976;115:35-41
- Pedersen HE, Blunck CFJ, Gardner E. The anatomy of lumbosacral posterior rami and meningeal branches of spinal nerves (sinu-vertebral nerves). *J Bone Joint Surg [Am]* 1956;38-A:377-391
- Stilwell DL. The nerve supply of the vertebral column and its associated structures in the monkey. *Anat Rec* 1956;125:139-169
- Jackson HC, Winkelmann RK, Bickel WH. Nerve endings in the human lumbar spinal column and related structures. *J Bone Joint Surg [Am]* 1966;48-A:1272-1281
- Paris SV. Anatomy as related to function and pain. *Orthop Clin North Am* 1983;14:475-489
- Wyke B. The neurology of low back pain. In: Jayson MIV, ed. *The lumbar spine and back pain*. New York: Churchill-Livingstone, 1987:56-99
- Wiberg G. Back pain in relation to the nerve supply of the intervertebral disc. *Acta Orthop Scand* 1949;19:211-221
- Malinsky J. The ontogenetic development of nerve terminations in the intervertebral discs of man. *Acta Anat (Basel)* 1959;38:96-113
- Kaplan EB. Recurrent meningeal branch of the spinal nerves. *Bull Hosp Jt Dis Orthop Inst* 1947;8:108-109
- Rothman RH, Simeone FA, Bernini PM. Lumbar disc disease. In: Rothman RH, Simeone FA, eds. *The spine*. Philadelphia: Saunders, 1982:508-531
- Brodal A. The autonomic nervous system. In: *Neurological anatomy*. New York: Oxford University, 1981:698-787
- Elliott FA, Schutta HS. The differential diagnosis of sciatica. *Orthop Clin North Am* 1971;2:477-484
- Mooney V, Robertson J. The facet syndrome. *Clin Orthop* 1976;115:149-156
- Hirsch C, Ingelmark BE, Miller M. The anatomical basis for low back pain. *Acta Orthop Scand* 1963;33:1-17
- Cervero F. Visceral nociception: peripheral and central aspects of visceral nociceptive systems. *Philos Trans R Soc Lond* 1985;B308:325-337
- Inman VT, Saunders JB de C. Referred pain from skeletal structures. *J Nerv Ment Dis* 1944;99:660-667
- Parke WW. Development of the spine. In: Rothman RH, Simeone FA, eds. *The spine*. Philadelphia: Saunders, 1982:1-17
- Chusid JG. *Correlative neuroanatomy & functional neurology*. Los Altos, CA: Lange Medical, 1985:238
- Hockaday JM, Whitty CWM. Patterns of referred pain in the normal subject. *Brain* 1967;90:482-496
- Feinstein B, Langton JNK, Jameson RM, Schiller F. Experiments on pain referred from deep somatic tissues. *J Bone Joint Surg [Am]* 1954;36-A:981-997
- Gray H. *Anatomy of the human body*. Philadelphia: Lea & Febiger, 1985;1251-1254, 1264-1265
- DePalma AF, Rothman RH. Salient clinical features of lumbar disc lesions. In: *The intervertebral disc*. Philadelphia: Saunders, 1970:181-202
- Carpenter MB. The autonomic nervous system. In: *Human neuroanatomy*. Baltimore: Williams & Wilkins, 1976:191-212
- Ruch TC. Pathophysiology of pain. In: Ruch TC, Patton HD, eds. *Physiology and biophysics*. Philadelphia: Saunders, 1982:508-531
- Pick J. The principles of the autonomic nervous system. In: *The autonomic nervous system*. Philadelphia: Lippincott, 1970:23-43
- Willis WD, Grossman RG. The spinal cord. In: *Medical neurobiology*. St. Louis: Mosby, 1973:80-115
- Willis WD, Grossman RG. Sensory systems. In: *Medical neurobiology*. St. Louis: Mosby, 1973:227-272
- Hannington-Kiff J. The modulation of pain. In: Helfet AJ, Lee DMG, eds. *Disorders of the lumbar spine*. Philadelphia: Lippincott, 1978:120-136
- Bahr R, Blumberg H, Janig W. Do dichotomizing afferent fibers exist which supply visceral organs as well as somatic structures? A contribution to the problem of referred pain. *Neurosci Lett* 1981;24:25-28
- Dalsgaard CJ, Ygge J. Separate populations of primary sensory neurons project to the splanchnic nerve and thoracic spinal nerve rami of the rat. *Med Biol* 1985;63:88-91
- Pierau F, Fellmer G, Taylor DCM. Somato-visceral convergence in cat dorsal root ganglion neurones demonstrated by double-labelling with fluorescent tracers. *Brain Res* 1984;321:63-70
- Jenkins TW. Physiology of spinal nerves. In: *Functional mammalian neuroanatomy*. Philadelphia: Lea & Febiger, 1978:107-133
- Janig W. The autonomic nervous system. In: Schmidt RF, ed. *Fundamentals of neurophysiology*. New York: Springer-Verlag, 1985:216-269