

# Generic Contrast Agents

Our portfolio is growing to serve you better. Now you have a *choice*.



FRESENIUS  
KABI

[VIEW CATALOG](#)

# AJNR

## **Congenital absence of the cervical and petrous internal carotid artery with intercavernous anastomosis.**

D J Quint, R S Boulos and T D Spera

*AJNR Am J Neuroradiol* 1989, 10 (2) 435-439  
<http://www.ajnr.org/content/10/2/435.citation>

This information is current as  
of May 10, 2025.

# Congenital Absence of the Cervical and Petrous Internal Carotid Artery with Intercavernous Anastomosis

Douglas J. Quint,<sup>1,2</sup> Roushdy S. Boulous,<sup>1</sup> and Thomas D. Spera<sup>3</sup>

Congenital absence of an internal carotid artery is a rare anomaly. Less than 100 cases have been reported in the English literature. It is usually associated with collateral flow to the involved vascular territory, so neurologic deficits are few. However, this anomaly is also associated with a high occurrence of intracranial aneurysms. We report two cases of absent internal carotid artery with collateral supply of blood through an anastomotic vessel arising from the cavernous region of the contralateral internal carotid artery. Both cases presented because of complications of associated aneurysms.

## Case Reports

### Case 1

A 60-year-old right-handed woman presented with an 8-week history of left frontoparietal headaches and progressive decrease in left visual acuity. Physical examination revealed left optic atrophy but was otherwise normal. CT scan revealed a 3.0-cm hyperdense enhancing left-sided suprasellar mass. Angiography (Figs. 1A and 1B) was performed to confirm the CT impression of aneurysm and to search for additional lesions. Besides demonstrating a 3-cm aneurysm arising from the left supraclinoid internal carotid artery, the examination revealed an anterior communicating artery aneurysm and a right middle cerebral artery trifurcation aneurysm. Also, an anomalous origin of the right cavernous internal carotid artery from the cavernous portion of the left internal carotid artery was demonstrated. The CT was again reviewed at this time and bone windows of the skull base revealed carotid canal asymmetry with the right canal appearing hypoplastic (Fig. 1C). The patient was hesitant regarding immediate surgery and was discharged with plans to return in 1 month. However, 2 weeks after she was discharged, the patient was admitted to the emergency room with severe left frontal headaches and complete blindness of the left eye. CT revealed extensive subarachnoid and intraventricular hemorrhage. The patient deteriorated and died on the sixth hospital day. No necropsy was performed.

### Case 2

A 65-year-old right-handed woman presented with acute onset of severe headache without focal neurologic deficits or seizures. Physical examination revealed nuchal rigidity, but was otherwise unremarkable. CT scan revealed subarachnoid hemorrhage. Emergent cerebral angiography (Figs. 2A and 2B), performed to evaluate for ruptured aneurysm, demonstrated an anterior communicating artery aneurysm and an anomalous origin of the left cavernous internal carotid artery from the cavernous portion of the right internal carotid artery. On the day after angiography, the patient underwent craniotomy and successful clipping of the anterior communicating artery aneurysm. The patient had repeat CT (Figs. 2C and 2D), which included high-resolution scanning through the skull base. These latter scans demonstrated an absence of the carotid canal on the left side. The patient did well and she was discharged 2 weeks after surgery.

## Discussion

Agenesis, aplasia, or hypoplasia of an internal carotid artery is a rare anomaly [1–3]. There are no universally agreed upon definitions of these terms as they apply to the internal carotid artery. The following descriptions represent the most widely accepted and most embryologically correct means for differentiating these conditions.

Agenesis reflects complete developmental failure of an organ and its primordium [4, 5]. Aplasia refers to the lack of development of an organ, although its anlage presumably existed at some time (Barr M, personal communication). Therefore, while both agenesis and aplasia of an internal carotid artery will result in an absent internal carotid artery at angiography, the two conditions can be differentiated by the absence or presence, respectively, of some remnant of the vessel (as determined at surgery or necropsy) or by secondary signs of previous fetal existence of the vessel. Such secondary signs include CT demonstration of the carotid canal in the skull base (which is thought to develop secondary to the in

Received November 2, 1987; accepted after revision February 8, 1988.

<sup>1</sup> Department of Neuroradiology, Henry Ford Hospital, Detroit, MI 48202.

<sup>2</sup> Present address: Division of Neuroradiology, University of Michigan Hospitals, East Medical Center Dr., Ann Arbor, MI 48109. Address reprint requests to D. J. Quint.

<sup>3</sup> Department of Radiology, The Toledo Hospital, Toledo, OH 43606-3899.



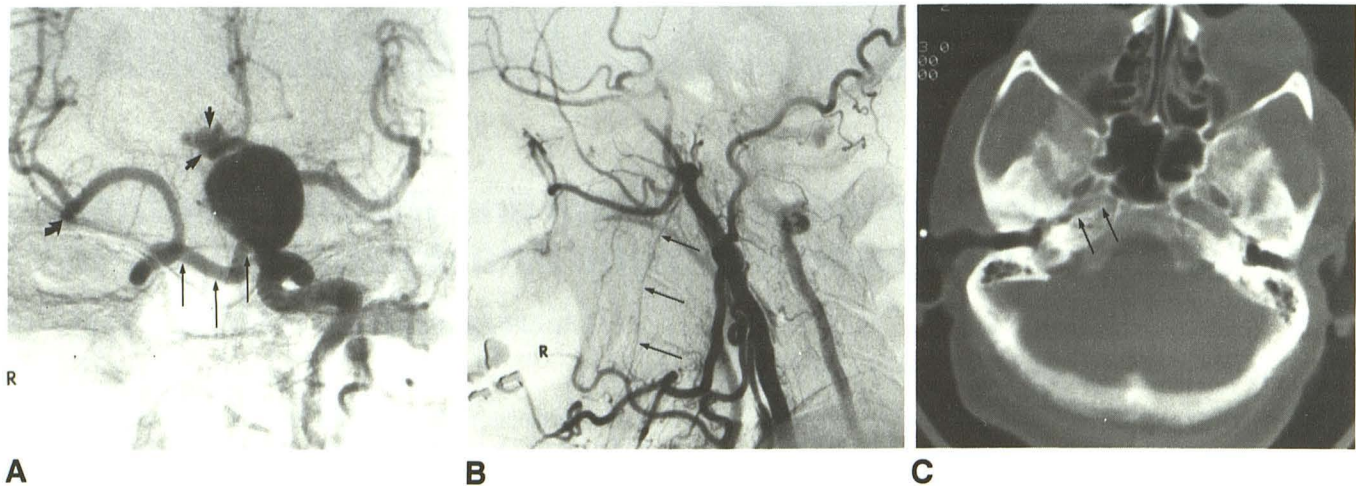


Fig. 1.—Case 1.

A, Left common carotid angiogram reveals a 3.0-cm aneurysm arising from supraclinoid portion of left internal carotid artery, which elevates the left A1 segment. Note filling of both anterior cerebral arteries through a patent anterior communicating artery and a small multilobulated aneurysm of the anterior communicating artery (*short arrows*). Also shown is antegrade filling of the cavernous and supraclinoid portions of the right internal carotid artery through an anomalous vessel (*long arrows*) arising from the cavernous portion of the left internal carotid artery. A third small aneurysm at right middle cerebral artery trifurcation (*curved arrow*) is also identified. Right A1 segment is not opacified.

B, Right common carotid angiogram demonstrates normal right external carotid vasculature without any remnant of a right internal carotid artery. A small inferior alveolar artery is identified (*long arrows*). Incidentally noted is reflux into the right vertebral artery. Vertebrobasilar angiography was normal with only transient reflux into a small left posterior communicating artery.

C, CT through skull base demonstrates hypoplasia of the right carotid canal (*long arrows*).

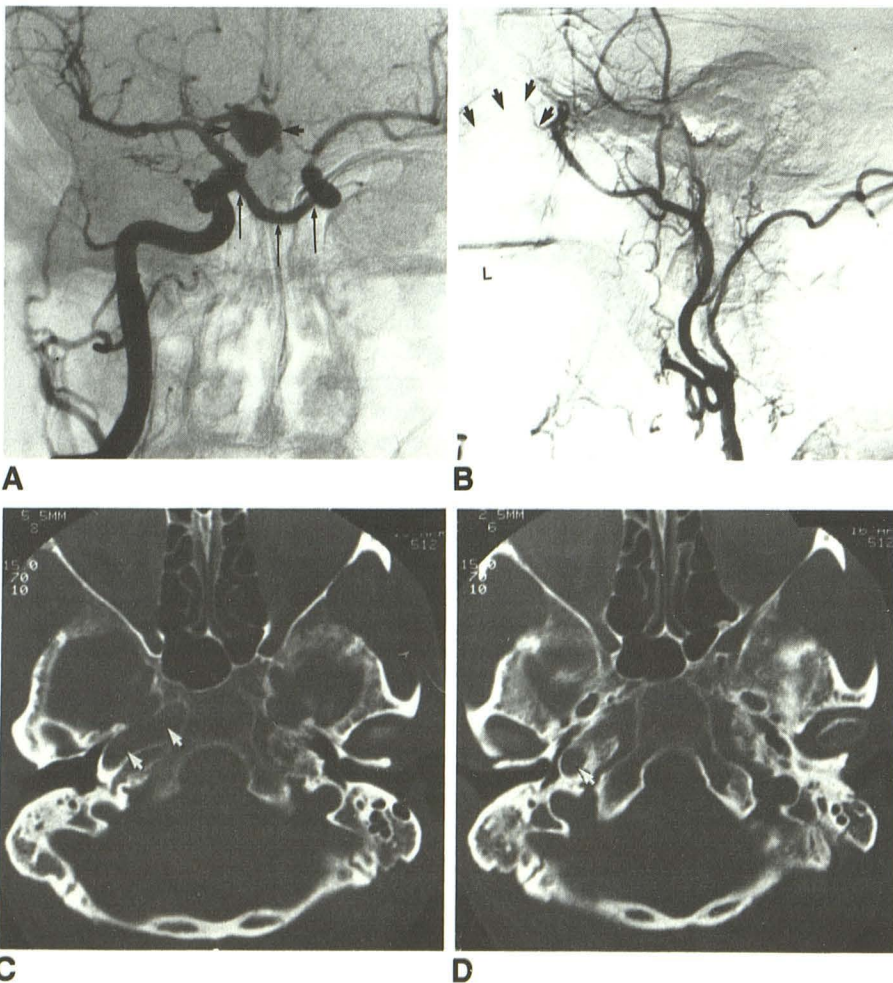


Fig. 2.—Case 2.

A, Right common carotid angiogram reveals opacification of both anterior cerebral arteries and a 1.5-cm lobulated anterior communicating artery aneurysm (*short arrows*). In addition, antegrade filling of left cavernous carotid artery through an anomalous vessel arising from region of right cavernous carotid is demonstrated (*long arrows*).

B, Left common carotid artery angiogram reveals normal left external carotid artery without any identifiable remnant of an internal carotid artery. No definite inferior alveolar artery is seen. However, a small infraorbital artery is identified (*arrows*). Vertebrobasilar angiography was unremarkable.

C and D, CT scans through skull base demonstrate absence of left carotid canal. Arrows show normal right carotid canal.



utero presence of the internal carotid artery) (Figs. 2C and 2D) [1] and/or angiographic demonstration of the infraorbital and alveolar arteries (branches of the fetal stapodial artery, which itself is a derivative of the fetal internal carotid artery) [1, 4]. It is not universally accepted that existence of these external carotid artery branches constitutes evidence for existence of an internal carotid artery in utero [4]. The third term, hypoplasia, refers to incomplete development of an otherwise normal-appearing structure (Barr M, personal communication). In the case of an internal carotid artery, the vessel can still be demonstrated angiographically, but it is smaller than normal in size. Agenesis, aplasia, and hypoplasia are most likely secondary to some embryonic insult that resulted in arrest of normal development of the artery or its primordium [6].

There is disagreement [4] as to the developmental origin of the common carotid artery and its two branches, the internal and external carotid arteries. Some authors maintain that the common carotid and the proximal internal and external carotid arteries arise together from the third aortic arch and that true agenesis of an internal carotid artery should therefore be associated with absence of the ipsilateral external carotid artery. Other authors state that only the proximal internal carotid artery arises from the third aortic arch and that the common carotid and external carotid arteries arise from the aortic sac. This would explain the differences of opinion among investigators as to the significance of the presence of an external carotid artery in making the diagnosis of agenesis versus aplasia.

In our first case, CT shows that the carotid canal is hypoplastic on the involved side (Fig. 1C). Also, the inferior alveolar artery is present (Fig. 1B). These findings, in association with angiographic absence of the cervical and petrous internal carotid artery, suggest aplasia rather than agenesis of the internal carotid artery. In our second case, the carotid canal is not identified on the involved side (Figs. 2C and 2D). Also, no alveolar artery is identified; however, a small infraorbital artery is seen. In view of the above-described disagreement as to the significance of the existence of the external carotid artery branches in differentiating agenesis from aplasia, we believe the findings (absent petrous internal carotid artery at angiography and absent carotid canal on CT) are most consistent with agenesis in this case. As stated above, agenesis and aplasia are best differentiated by direct visualization at surgery or necropsy.

With regard to the anastomotic intercarotid vessel seen in our two cases as well as in some of the earlier reports, it is interesting to note that in utero vessels connecting the internal carotid arteries have never been observed [4]. The internal carotid arteries arise from their respective third aortic arches and develop independently of one another without communication distal to the aortic sac and proximal to the anterior communicating artery. Many carotid-vertebral anastomoses are seen during fetal development (e.g., trigeminal, otic, hypoglossal, proatlantal-intersegmental), and some may persist into adult life, but no analogous fetal carotid-carotid anastomoses have been described.

Absence or underdevelopment of an internal carotid artery, a vessel that supplies blood to a large portion of one side of

the brain, is usually not associated with profound lifelong neurologic deficits. This is due to the presence of collateral sources of blood supply to the affected internal carotid artery territory. Lie [4] summarized the six basic patterns of collateral circulation in cases of agenesis, aplasia, or severe hypoplasia of one or both internal carotid arteries (Fig. 3). Type A collateral circulation exists when the ipsilateral anterior cerebral artery is supplied through the anterior communicating artery, and the ipsilateral middle cerebral artery is supplied through an enlarged posterior communicating artery. Type B collateral circulation exists when the anterior and the middle cerebral arteries are both supplied through a patent anterior communicating artery. In type C, both internal carotid arteries are absent and both the anterior and middle cerebral arteries are supplied via bilateral persistence of vascular connections from the basilar artery. In type D, the cervical portion of an internal carotid artery is absent, and the supraclinoid portion of that vessel is filled via an intercavernous vessel arising from the contralateral internal carotid artery. In type E, both internal carotid arteries are hypoplastic and supply only small anterior cerebral arteries. Both middle cerebral arteries arise from the basilar system through hypertrophied posterior communicating arteries. Finally, type F exists when the cervical portion of an internal carotid artery is absent and the precavernous internal carotid artery is formed by a rete mirabile of vessels through the skull base. Five of these types (A, B, C, E, and F) are easily explained on the basis of persistence and/or hypertrophy of well described fetal and/or normal adult vascular channels. However, type D suggests the existence of an anomalous vessel connecting the cavernous carotids and is not easily explained developmentally.

Our two patients represent examples of this anomalous vessel supplying the cavernous and supraclinoid segments of the internal carotid artery in the setting of ipsilateral absence of the cervical and petrous segments (Lie's type D) and appear almost identical to one described in 1966 [4]. There are several proposed developmental etiologies of this anomalous intercarotid vessel. One hypothesis is that two fetal trigeminal arteries anastomose and that their respective connections to the basilar artery are absent [4]. A second theory suggests that some insult to the cervical and/or petrous portion of an internal carotid artery early in development results in absence of this vessel with compensatory hypertrophy of clival branches [4] or capsular or inferior hypophyseal arteries [7] between the precavernous/cavernous internal carotid arteries [8] with eventual development of these anastomotic channels as the main collateral supply of blood to the cavernous internal carotid artery of the involved side. The exact location of this anomalous vessel (transsellar, intracaval, or retroclival) would correlate with the exact blood vessels involved (e.g., capsular, inferior hypophyseal, or clival, respectively). This second theory seems more plausible to us, since it implicates hypertrophy of known structures as the etiology of the intercarotid vessel as opposed to the development of a "new" vessel that is without a well described primordium.

Another important aspect of absence of an internal carotid artery is the documented increased occurrence of associated intracranial aneurysms. Afifi et al. [5] have recently reviewed



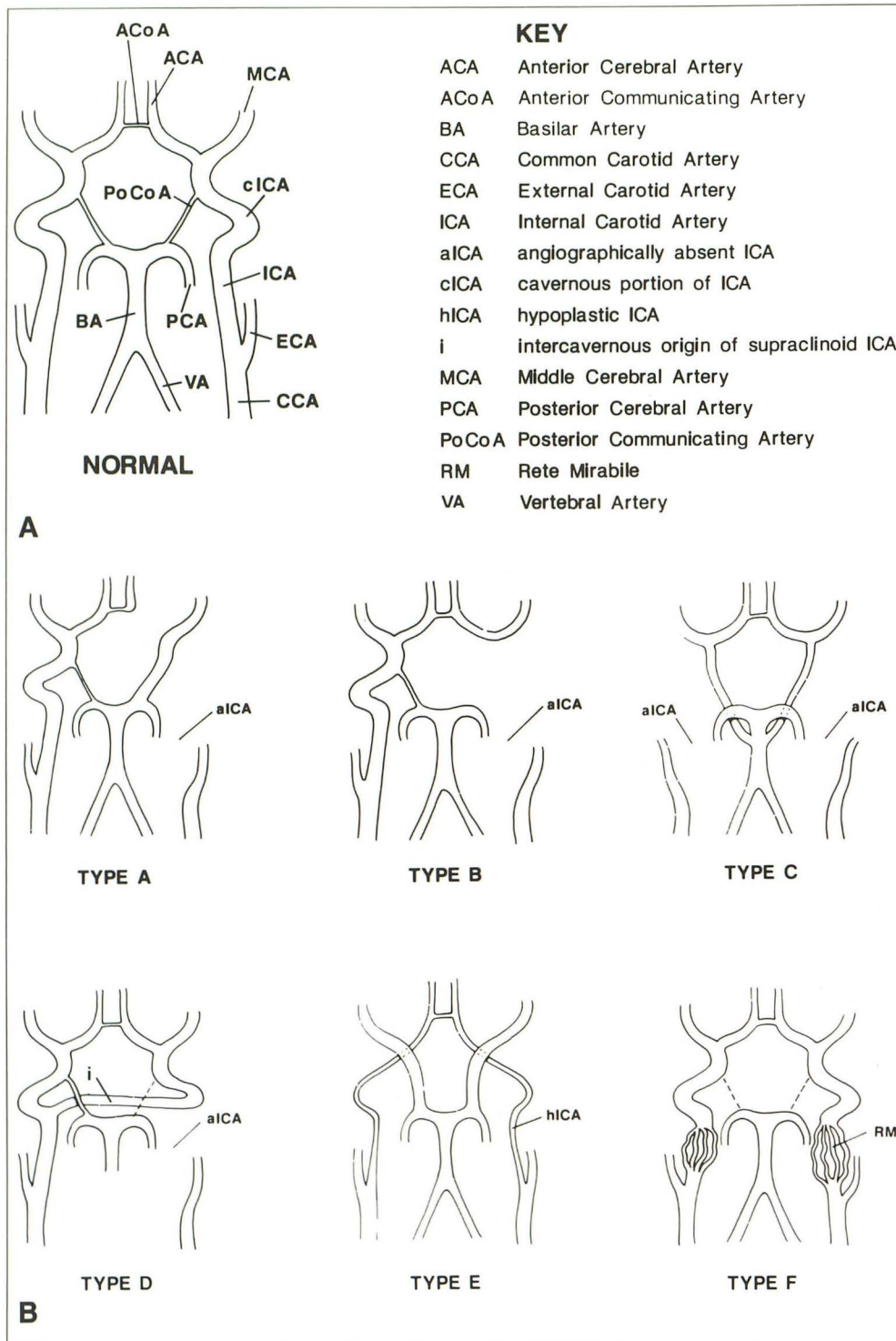


Fig. 3.—Routes of collateral blood flow when one or both internal carotid arteries are congenitally hypoplastic or absent.

A, Normal.

B, Six types of collateral flow. (After Lie [4], see text.)

the world literature and presented the 20 previously described examples of this association. Both our cases are also associated with aneurysm formation. While the frequency of aneurysms in patients with "normally" developed internal carotid arteries is estimated at 2–4% [1, 3, 9], the frequency of aneurysm formation in patients with an absent internal carotid artery has been reported in the 24–34% range [3, 5].

The increased occurrence of aneurysm formation is most likely secondary to the altered hemodynamics (altered flow pattern) of blood through collateral channels supplying the involved vascular territories. Both laboratory and clinical evidence of this is well documented in the literature [2, 10–12]. An alternative theory as to the relationship of absence of an internal carotid artery and aneurysm formation is that they

are both secondary to some underlying congenital defect [5].

Recognizing absent internal carotid arteries and the resultant mode of collateral flow to the involved territory is important for several reasons. First, neurologic thromboembolic disease in one cerebral hemisphere can be explained by peripheral vascular disease in the contralateral common carotid or even the vertebrobasilar system. Second, the increased risk of surgery (such as carotid endarterectomy or aneurysm surgery) in these patients (with only one carotid artery that may be supplying both cerebral hemispheres) can be identified, and prophylactic procedures such as external carotid–internal carotid bypass surgery could be considered before performing these procedures. Third, the possibility of encountering an intercavernous anastomotic vessel in a patient undergoing transsphenoidal pituitary surgery should be considered in any patient with absence of an internal carotid artery. Finally, there is the documented increased frequency of aneurysm formation in these patients and the risks attendant with aneurysmal expansion and/or rupture. These patients should be followed clinically and radiographically at close intervals to look for development of complications of existing aneurysms or formation of new ones.

#### REFERENCES

1. Dilenge D, Heon M. The internal carotid artery. In Newton TH, Potts DG, eds. *Radiology of the skull and brain*, vol. 2. St. Louis: Mosby 1974: 1202–1243
2. Teal JS, Rumbaugh CL, Bergeron RT, Segall HD. Congenital absence of the internal carotid artery associated with cerebral hemiatrophy, absence of the external artery, and persistence of the stapedia artery. *AJR* 1973;118:534–544
3. Servo A. Agenesis of the left internal carotid artery associated with an aneurysm on the right carotid syphon: Case report. *J Neurosurg* 1977;46:677–680
4. Lie TA. *Congenital anomalies of the carotid arteries*. Amsterdam: Excerpta Medica, 1968.
5. Afifi AK, Godersky JC, Menezes A, Smoker WR, Bell WE, Jacoby CG. Cerebral hemiatrophy, hypoplasia of internal carotid artery, and intracranial aneurysm. A rare association occurring in an infant. *Arch Neurol* 1987;44:232–435
6. Teal JS, Naheedy MH, Hasso AN. Total agenesis of the internal carotid artery. *AJNR* 1980;1:435–442
7. Kishore PRS, Kaufman AB, Melichar FA. Intracellar carotid anastomosis simulating pituitary microadenoma. *Radiology* 1979;132:381–383
8. Parkinson D. Collateral circulation of cavernous carotid artery: anatomy. *Can J Surg* 1964;7:251–268
9. Mohr JP, Fisher CM, Adams RD. Cerebrovascular diseases. In Isselbacher KJ, Adams RD, Braunwald E, Petersdorf RG, Wilson JD, eds. *Harrison's principles of internal medicine*, 9th ed. New York: McGraw-Hill, 1980;1911–1942
10. Ferguson GG. Physical factors in the initiation, growth and rupture of human intracranial saccular aneurysms. *J Neurosurg* 1972;37:666–677
11. Handa H, Nobuo H, Izumi N, Fumitada H. Saccular cerebral aneurysms in rats: a newly developed animal model of the disease. *Stroke* 1983;14: 857–866
12. Waga S, Okada M, Kojima T. Saccular aneurysm associated with absence of the left cervical carotid arteries. *Neurosurgery* 1978;3:208–212