

Generic Contrast Agents

Our portfolio is growing to serve you better. Now you have a *choice*.



[VIEW CATALOG](#)

AJNR

Diffuse pneumocephalus from *Clostridium perfringens* meningitis: CT findings.

M A Klein, J K Kelly and I G Jacobs

AJNR Am J Neuroradiol 1989, 10 (2) 447

<http://www.ajnr.org/content/10/2/447.citation>

This information is current as
of May 10, 2025.

Diffuse Pneumocephalus from *Clostridium perfringens* Meningitis: CT Findings

Pneumocephalus is defined as "the presence of air or gas within the cranial cavity" [1], but no distinction is made between localized and diffuse gas collections. We report a case of diffuse pneumocephalus caused by the gas-forming organism *Clostridium perfringens*. To the best of our knowledge, this is the first demonstration of diffuse pneumocephalus associated with *Clostridium* meningitis and the first publication of the CT findings.

Case Report

A 1-month-old boy was brought to the emergency room by his mother because of increasingly irregular respirations. On physical examination, the baby was hypotensive and his fontanelle was full. A Gram stain of the CSF showed Gram-positive rods. Diffuse pneumocephalus and generalized edema were identified on a nonenhanced head CT scan (Fig. 1). The patient died 6 hr after admission. At autopsy, a thick exudate was found on the brain surface. No abscess was seen on the gross specimen. Histologic examination revealed meningitis, and one section showed encephalitis. Brain culture grew *Clostridium perfringens*.

Discussion

Gas-forming organisms produce pneumocephalus through brain abscesses and meningitis. Excluding cases with a superimposed condition, like surgery or trauma, that can produce diffuse pneumocephalus, abscesses have been reported to produce only a localized pneumocephalus. Similarly, meningitis with a gas-forming organism has been reported to produce a localized pneumocephalus.

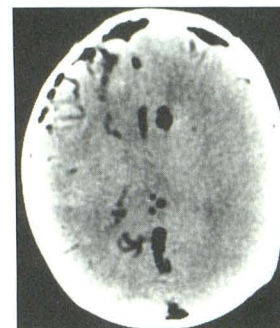
Despite the common occurrence of severe penetrating and non-penetrating head trauma, *Clostridium* meningitis without an associated brain abscess is extremely rare [2-4]. A search of the English literature yielded only 23 documented cases. *Clostridium* meningitis was associated with head trauma in 10 cases [2, 5-10], surgical intervention in five [11-15], gastrointestinal disease in four [3, 16, 17], and genitourinary surgery in one [4]. No focus was mentioned in one case [18], and no septic focus was found in two [19, 20]. One of the two cases with no focus of seeding yielded no organism in the CSF on either Gram stain or culture although the patient had signs and symptoms of meningitis and *Clostridium* bacteremia [20]. No focus of meningeal seeding could be found in our patient either clinically or pathologically.

Only one description of the CT findings of *Clostridium* meningitis has been published [19]. Unfortunately, no CT scans were included in the report, and the only description provided was that no abscess, subdural effusion, or enlarged ventricles were found. A CT scan of a patient with *Clostridium* in the CNS was found [21], but it showed a *Clostridium* abscess. Consequently, the only CT findings to date of *Clostridium* meningitis are the ones in this report: diffuse cerebral edema and diffuse pneumocephalus.

The two patients who had uncomplicated *Clostridium* meningitis with pneumocephalus had multiple gas-containing cysts at autopsy [16]. Neither had a diffuse pneumocephalus similar to that in our patient, although no radiologic studies were performed in either patient. Alternatively, our patient did not show gas-containing cysts either on CT or on pathologic examination.

In conclusion, we add *Clostridium perfringens* meningitis to the differential diagnosis of diffuse pneumocephalus found on a CT scan.

Fig. 1.—Nonenhanced axial CT scan shows diffuse pneumocephalus with gas in subarachnoid space, parenchyma, and ventricles. Indistinctness of gray matter-white matter interface is consistent with generalized edema.



Mitchell A. Klein
John K. Kelly
Irving G. Jacobs

Wayne State University/Detroit Medical Center
Detroit, MI 48201

REFERENCES

1. *Stedman's medical dictionary*, 24th ed. Baltimore: Williams & Wilkins, 1982
2. Cairns H, Calvert CA, Daniel P, Northcroft GG. Complications of head wounds with especial reference of infection. *Br J Surg* 1947;1:198-243
3. Ganchrow MI, Brief DK. A case of meningitis secondary to *Clostridium welchii*. *J Trauma* 1971;11:444-446
4. Conomy JP, Dalton JW. *Clostridium perfringens* meningitis. *Arch Neurol* 1969;21:44-50
5. Henderson JK, Kennedy WFC, Potter JM. Recovery from acute *Clostridium* meningitis. *Br Med J* 1954;2:1400
6. Colwell FG, Sullivan J, Shuman H, Cohen JR. Acute purulent meningitis due to *Clostridium perfringens*. *N Engl J Med* 1960;262:618-619
7. Moller B. Purulent *Clostridium welchii* meningitis originating from a penetrating cranial wound: report of case cured with penicillin and anti-gas gangrene serum. *Acta Chir Scand* 1955;109:395-399
8. DeWeese WO, Leblanc HJ, Kline DG. Pellet-gun brain wound complicated by *Clostridium perfringens* meningitis. *Surg Neurol* 1976;5:253-254
9. Mones MI, Moniz A, Wiezer DW. Report on a case of *Clostridium welchii* meningitis. *Clin Proc Child Hosp* 1965;21:17-22
10. O'Tanasek FJ, Chambers JW. Fulminating gas gangrene of the brain: report of a case in a civilian. *Neurosurgery* 1945;2:539-542
11. Willis AT, Jacobs SI. A case of meningitis due to *Clostridium welchii*. *J Pathol Bacteriol* 1964;88:312-314
12. Swartz MN, Dodge PR. Bacterial meningitis: a review of selected topics. I. General clinical features, special problems and unusual meningeal reactions mimicking bacterial meningitis. *N Engl J Med* 1965;272:725-730
13. Alexander JG. A fatal case of *Clostridium welchii* toxemia due to ward infection. *J Clin Pathol* 1969;22:508
14. Ho KL. *Clostridium perfringens* meningitis. *Int Surg* 1982;67(3):271-273
15. Bornstein DL, Weinberg AN, Swartz MN. Anaerobic infections: review of current experience. *Medicine* 1964;43:207-232
16. Gorse GJ, Slater LM, Sobol E, et al. CNS infection and bacteremia due to *Clostridium septicum*. *Arch Neurol* 1984;41:882-884
17. Mackay NNS, Gruneberg RN, Harries BJ, Thomas PK. Primary *Clostridium* meningitis. *Br Med J* 1971;1:591-592
18. Alpern RJ, Dowell VR. *Clostridium septicum* infections and malignancy. *JAMA* 1969;209(3):385-388
19. Gehrz RC, Ward RM, Lien RH, Thompson HR, Jarvis CW. Meningitis due to combined infections. *Am J Dis Child* 1976;130:877-879
20. Sikorski JB, Gilroy J, Meyer JS. *Clostridium perfringens* (gas bacillus) septicemia and acute purulent meningitis. *Harper Hosp Bull* 1963;21:38-42
21. Roeltgen D, Shugar G, Towfighi I. Cerebritis due to *Clostridium septicum*. *Neurology* 1980;30:1314-1316