

Generic Contrast Agents

Our portfolio is growing to serve you better. Now you have a *choice*.



[VIEW CATALOG](#)

AJNR

This information is current as of May 7, 2025.

High-Signal Periventricular Lesions in Patients with Sarcoidosis: Neurosarcoidosis or Multiple Sclerosis?

Alison S. Smith, David M. Meisler, Meredith A. Weinstein, Robert L. Tomsak, Maurice R. Hanson, Richard A. Rudick, Bradley K. Farris and Richard M. Ransohoff

AJNR Am J Neuroradiol 1989, 10 (3) 485-490
<http://www.ajnr.org/content/10/3/485>

High-Signal Periventricular Lesions in Patients with Sarcoidosis: Neurosarcoidosis or Multiple Sclerosis?

Alison S. Smith¹
David M. Meisler²
Meredith A. Weinstein³
Robert L. Tomsak⁴
Maurice R. Hanson⁵
Richard A. Rudick⁵
Bradley K. Farris⁶
Richard M. Ransohoff⁵

The vast majority of periventricular abnormalities visualized with MR imaging in patients less than 50 years old represents multiple sclerosis (MS) lesions. There are many other causes of periventricular lesions, most of which can be differentiated from MS on the basis of history and physical or MR findings. Five cases of biopsy- or Kveim test-proved sarcoidosis with MR findings consistent with MS are reported. Each of these patients, diagnosed as having sarcoidosis, had symptoms identical to those seen in MS. Although these patients have not had histologic characterization of the intraparenchymal lesions seen on MR, they illustrate the difficulty of differentiating sarcoidosis with CNS involvement from MS in some patients on the basis of clinical, radiographic, electrodiagnostic, or CSF testing.

This series contributes to a growing body of evidence that neurosarcoidosis probably should be included in the differential diagnosis of isolated periventricular lesions in patients less than 50 years old.

Of the tests used to confirm the clinical diagnosis of multiple sclerosis (MS), MR imaging is the most sensitive. MR findings have been reported in 85–96% of patients with MS [1–3]. The most characteristic MR findings in MS are periventricular lesions with increased signal with spin-density and T2-weighted images. The CSF is abnormal in 68–90% [2–6]. Evoked potentials are abnormal in 90% [2–4, 7] and CT is abnormal in 25–63% [2, 5, 7, 8] of patients with MS.

Although MR abnormalities of the CNS have been reported in patients with sarcoidosis, the emphasis has been on basilar or superficial cortical lesions [9]. Recent reports have alluded to the MR findings of periventricular lesions in neurosarcoidosis; these have been mostly associated with other CNS abnormalities such as hydrocephalus and less commonly found as isolated lesions [9–12]. We report five patients with clinical and biopsy- or Kveim test-proved sarcoidosis with CNS symptoms in whom isolated periventricular with occasional subcortical lesions were the only findings noted by MR. The clinical and MR findings mimic those associated with MS and illustrate the difficulty of differentiating MS and sarcoidosis in some patients.

Materials and Methods

Five patients with ophthalmologic and CNS complaints, previously diagnosed with biopsy-proved sarcoidosis, were evaluated by cranial MR. The patients were 32–50 years old. MR was performed in two of the five patients as part of a multicenter cooperative study investigating CNS disorders and granulomatous uveitis [13]. The remaining three patients subsequently came to our attention because they also had multifocal neurologic deficits consistent with MS, yet had biopsy-proved sarcoidosis. T1-, spin-density-, and T2-weighted MR techniques were used. CT examinations, performed 1 day to 10 years before MR in four of the five patients, were reported as normal.

This article appears in the May/June 1989 issue of *AJNR* and the July 1989 issue of *AJR*.

Received May 26, 1988; accepted after revision September 12, 1988.

¹ Division of Radiology, Cleveland Metropolitan General Hospital, 3395 Scranton Rd., Cleveland, OH 44109. Address reprint requests to A. S. Smith.

² Department of Ophthalmology, Cleveland Clinic Foundation, Cleveland, OH 44106.

³ Department of Radiology, Cleveland Clinic Foundation, Cleveland, OH 44106.

⁴ Division of Neuro-ophthalmology, University Hospitals of Cleveland, Cleveland, OH 44106.

⁵ Department of Neurology, Cleveland Clinic Foundation, Cleveland, OH 44106.

⁶ Department of Ophthalmology, University of Oklahoma, Oklahoma City, OK 73190.

AJNR 10:485–490, May/June 1989

0195–6108/89/1003–0485

© American Society of Neuroradiology

Results

Periventricular lesions were seen on spin-density- and T2-weighted images in all five cases. Subcortical lesions were also present in cases 1 and 3. Of three patients with hypertension (cases 1, 3, and 5), only one (case 3) had subcortical lesions. The pattern of abnormality in all cases was assessed prospectively as consistent with MS. No other abnormalities were noted on MR.

Case Reports

Case 1

A 37-year-old woman was seen at age 33 with sudden loss of vision in the left eye. Steroid therapy was given for optic neuritis and her vision returned after 1 week. At age 35, a chest film obtained for the evaluation of pain and swelling in both ankles showed bilateral hilar adenopathy. Mediastinal biopsy revealed noncaseating granuloma consistent with sarcoid disease. The patient was treated with steroids. One year later she developed double vision when looking to the left. A cranial CT examination was normal. Her sedimentation rate was elevated to 32 mm/hr. One and one-half years later, the patient had numbness of the right side of the face and intermittent numbness and tingling of the arms, legs, and hands. The neurologic examination was normal. Three months later, the patient had pain followed by blurred vision of the right eye. She received a triamcinolone acetonide injection for optic neuritis of the right eye with subsequent improvement in visual acuity. The neuroophthalmologic examination revealed macro-square-wave jerks consistent with disease of the cerebellar system. A subtle right internuclear ophthalmoplegia was also present.

Because of the history of bilateral optic neuritis and internuclear ophthalmoplegia, a diagnosis of MS was considered and the patient was referred for MR examination. The MR study shown in Figure 1 demonstrates multiple focal areas of increased signal in the periventricular white matter and centrum semiovale bilaterally on spin-density- and T2-weighted images. An additional lesion was noted in the right temporal periventricular white matter. On the basis of the clinical and MR findings, the diagnosis in this patient is of both MS and sarcoidosis.

Case 2

A 43-year-old woman with a history of hypertension and asthma was seen for evaluation of fever, chills, headache, malaise, generalized arthralgia, and myalgia. No definitive diagnosis was made at initial workup.

Two months later, the patient developed right facial weakness and a "film over both eyes." Sarcoidosis was diagnosed on the basis of histopathologic findings on mediastinal biopsy, which was performed after a chest film showed bilateral perihilar adenopathy. The patient had a right peripheral seventh nerve paralysis and papilledema. CSF study showed protein elevated at 97 mg/dl (normal, 15–45 mg/dl). Gamma globulin constituted 23.5% of CSF protein. Visual acuity was 20/20 in both eyes. Small, white, keratic precipitates and mild cellular reactions in the anterior chambers and vitreous of both eyes were found on slit-lamp examination. There was bilateral inferior retinal vascular sheathing. The fever and ocular inflammation responded to steroid therapy. Sarcoid ophthalmopathy with probable meningeal involvement was diagnosed. The cranial CT examination was normal. Seven years later, the patient had an MR examination for evaluation of recurrent CNS symptoms. This examination showed closely periventricular lesions (Fig. 2).

Case 3

A 35-year-old woman with hypertension, weight loss, myalgia, fever, pain, numbness, and weakness of the right arm and left lower extremity had a mediastinal biopsy diagnostic of sarcoidosis. One year later, a biopsy of scalp nodules was also consistent with sarcoidosis. Subsequently, the patient had pain and numbness of the right arm and shortly afterward in the right leg, which gradually resolved. MR examination revealed multiple areas of increased signal on spin-density- and T2-weighted images in the subcortical and periventricular white matter (Fig. 3). Two years later, the patient had photophobia in the right eye. Cranial CT examination and CSF immunoglobulins were normal.

Case 4

A 24-year-old woman with fatigue was found to have bilateral hilar adenopathy and pulmonary infiltrates on chest film. A cervical lymph-node biopsy confirmed the presence of sarcoidosis, which was

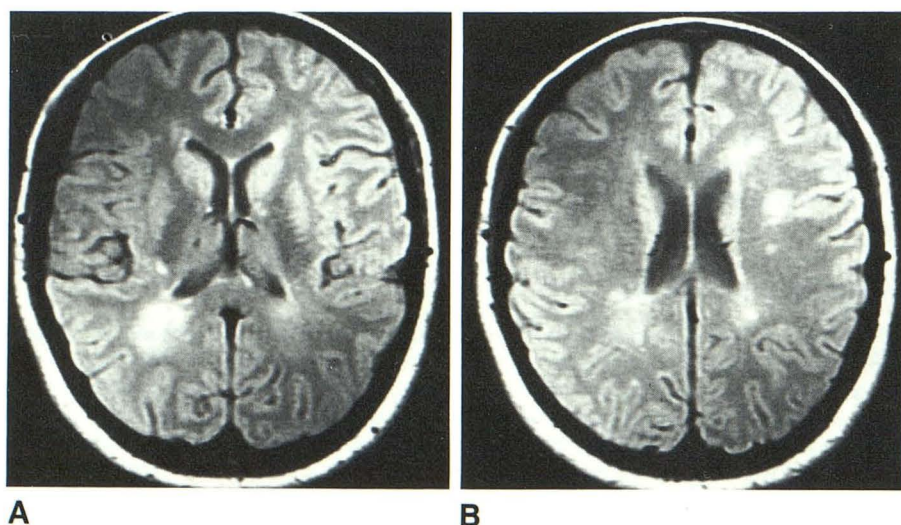


Fig. 1.—Case 1: 37-year-old woman with clinical diagnosis of multiple sclerosis and histologically diagnosed systemic sarcoidosis. Axial MR images, 2000/20 (TR/TE), show closely periventricular (A) and periventricular and centrum semiovale lesions (B).

treated with steroids. The disease was quiescent except during pregnancies 5 and 7 years later, during which she had recurrence of the infiltrates.

Bilateral uveitis was first noted 7 years after her original presentation. Her visual acuity was 20/20 in both eyes. Granulomatous-appearing keratic precipitates and an anterior chamber cellular reaction were noted on slit-lamp examination. Subsequently, the patient had recurrent bouts of granulomatous iridocyclitis involving both eyes that were responsive to topical corticosteroid drops. Eight years after her original presentation, MR examination revealed several periventricular lesions (Fig. 4).

Case 5

A 46-year-old woman had been diagnosed as having MS 14 years earlier, which was manifested by ascending numbness of the lower extremities and was treated with intrathecal steroids. She also had a 5-year history of hypertension and a previous diagnosis of sarcoidosis, made at age 20 by the finding of hilar adenopathy on chest radiography and a positive Kveim test. During the course of her illness, she had experienced peripheral numbness and tingling sensations, intermittent gait ataxia, and fatigue. She also experienced a right retrobulbar neuritis and associated central scotoma, and color desaturation in the left eye. A recent evaluation indicated a mild decrease in pinprick sensation over the torso to T7 and left lateral thigh, abnormal visual-evoked potential on the right, and an otherwise normal neurologic examination. MR examination showed multiple periventricular abnormalities characteristic of MS (Fig. 5). Family history revealed MS in one cousin and sarcoidosis in another.

Discussion

Cranial MR frequently demonstrates periventricular lesions that show increased signal intensity on spin-density- and T2-weighted images and occasionally show decreased signal intensity on T1-weighted images. In the vast majority of patients under the age of 50 years, these abnormalities represent MS lesions. However, these areas of abnormal signal in the periventricular region are not specific for MS and have also been observed in Sjögren syndrome [14], systemic

lupus erythematosus, multifocal leukoencephalopathy, AIDS, encephalitis, other brain infections [15], changes after radiation treatment of the brain, subependymal tumor [16], hydrocephalus [17], pseudotumor cerebri [18], vitamin B₁₂ deficiency [3], lymphomatoid granulomatosis (Smith AS, unpublished data), multiple cerebral infarcts (usually in patients over 50 years of age) [19, 20], and Binswanger disease.

In our series, five patients with biopsy- or Kveim test-proved sarcoidosis had periventricular lesions on MR and multifocal neurologic disease. None of our patients as studied by MR had the more common intracranial abnormalities of sarcoidosis, that is, granulomatous involvement of the leptomeninges; superficial parenchymal invasions; and, less frequently, deep parenchymal lesions and rare spinal cord involvement [21–23]. Periventricular lesions have been noted within other series of neurosarcoidosis [9–12, 24], but it should be emphasized that this can be an exclusive CNS finding and therefore is difficult to distinguish from MS.

Although the cause of these periventricular lesions in sarcoidosis remains uncertain, several possibilities exist. The lesions may be attributed to a true vasculitis, which, although rare, has been documented in neurosarcoidosis. Vasculitis has been demonstrated to be a granulomatous perivascular infiltration around arteries and veins [22, 25]. Infiltration of the leptomeningeal disease through Virchow-Robin spaces is the suspected mechanism of the arteritis termed meningovascular sarcoidosis [26, 27]. The latter can result in "subclinical" infarcts and transient ischemic attacks. In addition, nongranulomatous inflammatory changes, which could result in periventricular lesions, are frequently seen in perivascular spaces in neurosarcoidosis [27]. A less likely explanation is that the periventricular lesions result from a progressive multifocal leukoencephalopathy; seven such cases have been reported [28]. Three of the five patients reported in our study had hypertension, which may lead to premature vascular deterioration and potentially manifest as white-matter lesions on MR. In our experience, white-matter lesions are not common under

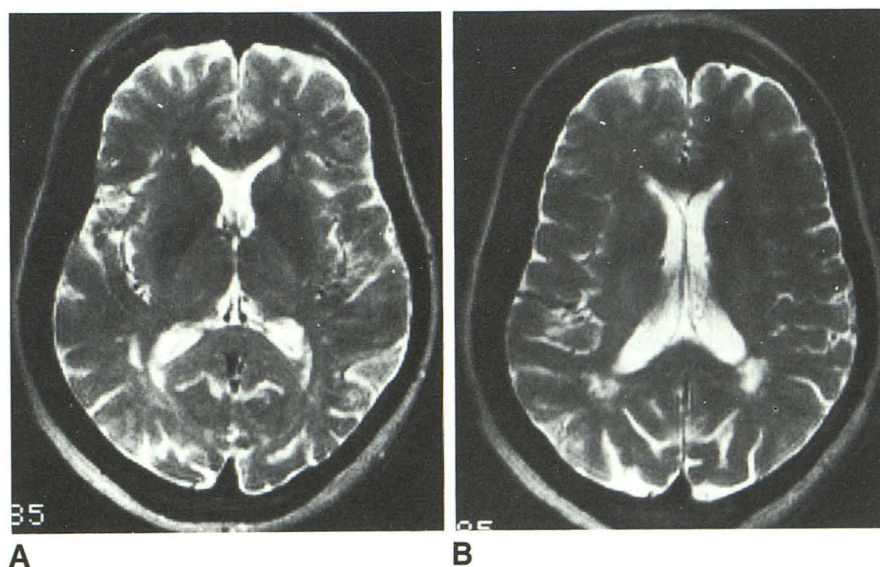
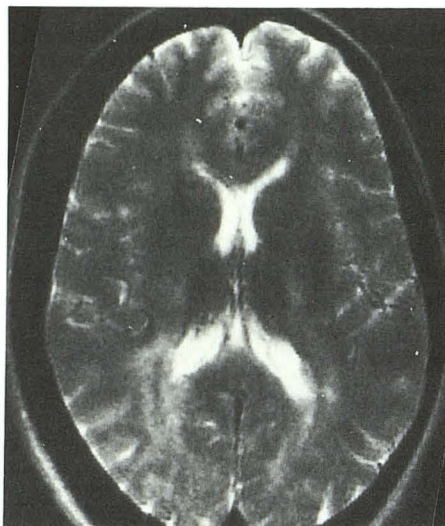


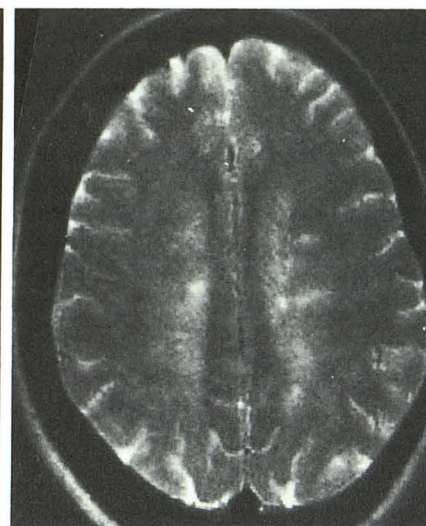
Fig. 2.—Case 2: 50-year-old hypertensive woman with systemic sarcoidosis, sarcoid ophthalmopathy, cranial-nerve palsies, and abnormal CSF studies. MR images, 2000/20 (TR/TE), show closely periventricular lesions at lower (A) and higher (B) ventricular levels.

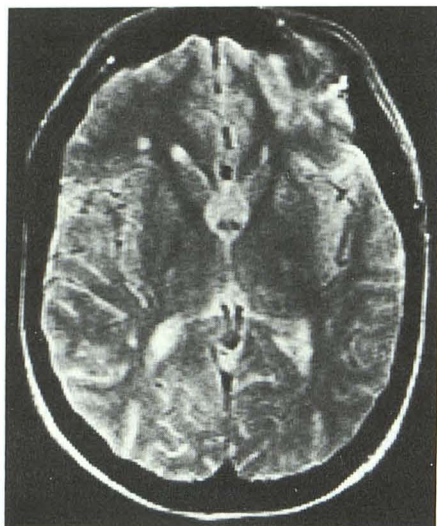

Fig. 3.—Case 3: 37-year-old woman with extremity weakness, photophobia, and systemic sarcoidosis. MR image, 2000/20 (TR/TE), shows periventricular and subcortical lesions.

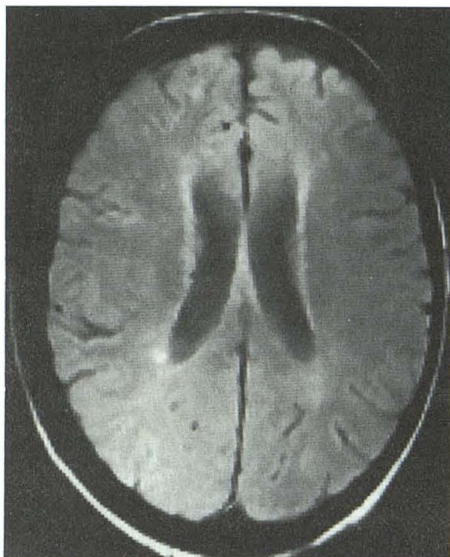


A

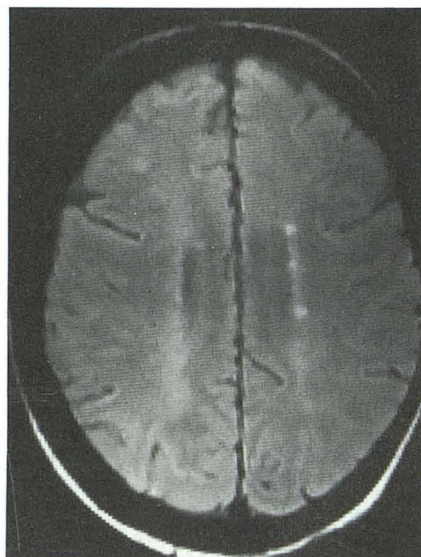


B

Fig. 4.—Case 4: 32-year-old woman with systemic sarcoidosis and bilateral sarcoid ophthalmopathy, and closely periventricular lesions seen on MR images, 2000/20 (TR/TE), at level of occipital horns (A) and above bodies of lateral ventricles (B).



A



B

Fig. 5.—Case 5: 46-year-old woman with long-standing history of both sarcoidosis and multiple sclerosis with retrobulbar neuritis, progressive extremity paresthesias, and positive visual-evoked potentials. Periventricular lesions are seen on MR images, 2010/32 (TR/TE), adjacent to (A) and above (B) bodies of lateral ventricles.

the age of 50, even in hypertensive patients. However, when present, subcortical rather than periventricular lesions are the predominant pattern in hypertensive individuals. Therefore, the cause of the periventricular lesions in our cases may be attributed to the following possibilities: (1) the presence of MS in patients who have sarcoidosis also, (2) intracranial manifestations of sarcoidosis resulting in symptoms similar to demyelinating disease, or (3) a subtype of demyelinating disease related to sarcoid.

MS and neurosarcoidosis can be difficult to differentiate clinically, since they share an undulant course and diverse

neurologic findings. Among the shared symptoms of MS and sarcoidosis are optic-nerve abnormalities, visual disturbances, gait ataxia, and incoordination. Although CNS sarcoid is clinically present in only 1–5% of patients with systemic disease, clinically silent CNS sarcoidosis has been described in 66% of patients with known systemic sarcoidosis [29, 30]. CNS symptoms can be the presenting complaint of the systemic disease [26, 31], and the rare occurrence of CNS sarcoidosis without systemic manifestations has been documented [27, 32]. The diagnosis of sarcoidosis is especially difficult in those patients whose only manifestations are

in the CNS; estimations of misdiagnosis range from 33% to 64% [29] to 80% [30]. In patients with CNS sarcoid, Wiedersholt and Siekert [31] found that 28 patients had CNS symptoms and their systemic disease was found secondarily. Symptoms and signs include diabetes insipidus, seizures, cranial-nerve involvement, corticospinal tract signs, cerebellar deficits, and myopathy. Delaney [26] described 23 patients with CNS sarcoid who had a wide range of CNS symptoms, 15 of whom had neurologic dysfunction as the presenting complaint; in seven of the 15 the neurologic deficit was the only symptom. Both MS and sarcoidosis may produce elevated spinal fluid protein, immunoglobulin G/albumin ratios, and oligoclonal bands [33].

The problem of distinguishing MS from sarcoidosis is especially difficult in those patients with ocular disease. Both MS and sarcoidosis may present with ocular findings that are characterized by an exacerbating and remitting course. The most frequent ocular manifestation of sarcoidosis is uveitis [34]. Often, this ocular inflammation is confined to the anterior segment of the eye and is designated iridocyclitis. While less common, anterior segment inflammation has been associated with MS [35].

Retinal perivasculitis, characterized clinically by perivascular sheathing and often involving the peripheral retinal vasculature, has been reported in sarcoidosis [36] and MS [37]. Retrobulbar optic neuropathy occurs in both MS [38] and sarcoidosis [39, 40], although it is much more common in MS.

Sjögren syndrome with CNS involvement can also be clinically and radiologically difficult to differentiate from MS. CNS involvement occurs in 5–20% [41, 42] of patients with this disease. The multifocal neurologic findings related to brain and spinal cord involvement—evoked responses, CSF profiles, presence of optic neuritis—may be indistinguishable from those of MS [42]. Although the mean age of presentation with CNS abnormalities is higher in Sjögren disease (38 years) than in MS, the overlap becomes significant since Sjögren syndrome is the most common rheumatologic disease [43]. MR studies in these patients have revealed periventricular lesions indistinguishable from those in MS [15].

In the series of Rudick et al. [44] of 10 patients with an incorrect diagnosis of MS, two of the patients had lesions that would be expected to give abnormal periventricular signal, Moya Moya, and Binswanger diseases.

In some cases it is not possible to differentiate the cause of periventricular lesions with MR. Age is an important criterion in differentiating the cause of these lesions. With increasing age, over 50 years old, multiinfarct dementia, B₁₂ deficiency, Binswanger disease, and "aging of the brain" become more likely as the cause of these lesions, while MS and Sjögren disease become less likely. The history and clinical and MR findings can help differentiate Moya Moya, hydrocephalus, postradiation changes, subependymal tumor, pseudotumor cerebri, encephalitis, progressive multifocal leukoencephalopathy, AIDS, and other brain infections from Sjögren disease and MS in almost all cases.

In conclusion, our series and that of Miller et al. [12] indicate that patients with sarcoidosis may have bright periventricular lesions on spin-density- and T2-weighted images, without the

classic peripheral granulomas of the brain, but with an MR appearance very similar to that of MS. Furthermore, it is sometimes difficult or impossible to differentiate sarcoid with CNS involvement from MS on the basis of clinical, CSF, and MR findings, as illustrated by our five patients with sarcoidosis. Histopathologic correlation was lacking in our series. However, histopathologic evidence that periventricular lesions can be present in cerebral biopsy-proved neurosarcoids was noted in one patient in the series of Miller et al. Autopsy examination may be the only way to exclude the possibility of coexisting sarcoid and MS.

REFERENCES

1. Drayer BP, Burger P, Hurwitz B, Dawson P, Cain J. Reduced signal intensity on MR images of thalamus and putamen in multiple sclerosis: increased iron content? *AJR* **1987**;149:357–363
2. Sheldon JJ, Siddharthen R, Tobias J, Sheremata WA, Soila K, Viamonte M. MR imaging of multiple sclerosis: comparison with clinical and CT examinations in 74 patients. *AJNR* **1985**;6:683–690
3. Uhlenbrock D, Seidel D, Gehlen W, et al. MR imaging in multiple sclerosis: comparison with clinical, CSF, and visual evoked potential findings. *AJNR* **1988**;9:59–67
4. Bartel DR, Markand ON, Kolar OJ. The diagnosis and classification of multiple sclerosis: evoked responses and spinal fluid electrophoresis. *Neurology* **1983**;33:611–617
5. Jacobs L, Kinkel WR, Polachini I, Kinkel RP. Correlation of nuclear magnetic resonance imaging, computerized tomography, and clinical profiles in multiple sclerosis. *Neurology* **1986**;36:27–34
6. Rudick RA, Pallant A, Bidlach JM, Herndon RM. Free kappa light chains in multiple sclerosis spinal fluid. *Ann Neurol* **1986**;20:63–69
7. Scotti G, Scialfa G, Biondi A, Landoni L, Caputo D, Cazzulla CL. Magnetic resonance in multiple sclerosis. *Neuroradiology* **1986**;28:319–323
8. Runge VM, Price AC, Kirshner HS, Allen JH, Partain CL, James AE. Magnetic resonance imaging of multiple sclerosis. A study of pulse-technique efficacy. *AJNR* **1984**;5:691–702
9. Ketonen L, Oksanen V, Kuuliala I. Preliminary experience of magnetic resonance imaging in neurosarcoidosis. *Neuroradiology* **1987**;29:127–129
10. Hayes WS, Sherman JL, Stern BJ, Citrin CM, Pulaski PD. MR and CT evaluations of intracranial sarcoidosis. *AJNR* **1987**;8:841–847
11. Greco A, Steiner RE. Magnetic resonance imaging in neurosarcoidosis. *Magn Reson Imaging* **1987**;5:15–21
12. Miller DH, Kendall BT, Barter S, et al. Magnetic resonance imaging in central nervous system sarcoidosis. *Neurology* **1988**;38:378–383
13. Meisler DM, Tomsak RL, Weinstein MR, et al. Magnetic resonance imaging (MRI) and HLA typing in patients with peripheral retinal perivasculitis and intermediate uveitis (abstr). *Invest Ophthalmol Vis Sci (Suppl)* **1986**;27:121
14. Kumar AJ, Rosenbaum AE, Wang H, Malat J, Provast TT, Alexander E. Magnetic resonance imaging in Sjögren's syndrome. Presented at the annual meeting of the American Society of Neuroradiology, New York City, May 1987
15. Zimmerman RA, Bilaniuk LT, Sze G. Intracranial infections. In: Brant-Zawadzki M, Norman D, eds. *Magnetic resonance*. New York: Raven, **1987**:235–258
16. Holland BA. Diseases of white matter. In: Brant-Zawadzki M, Norman D, eds. *Magnetic resonance*. New York: Raven, **1987**:259–278
17. Zimmerman RD, Fleming CA, Leeb CP, Saint-Louis LA, Deck MDF. Periventricular hyperintensity as seen by magnetic resonance: prevalence and significance. *AJNR* **1986**;7:13–20
18. Moser FG, Hilal SK, Abrams C, et al. MR imaging of pseudotumor cerebri. *AJNR* **1988**;9:39–45
19. Brant-Zawadzki M, Fein G, Van Dyke C, Kiernaw R, Davenport L, deGroot J. MR imaging of the aging brain: patchy white-matter lesions and dementia. *AJNR* **1985**;6:675–682
20. Kirkpatrick JB, Hayman LA. White-matter lesions in MR imaging of clinically healthy brains of elderly subjects: possible pathologic basis. *Radiology* **1987**;162:509–511
21. Brooks BS, El Gammal T, Hemgerford GD, Acker J, Trevor RP, Russel W. Radiologic evaluation of neurosarcoidosis: role of computed tomography.

- AJNR 1982;3:513-521
22. Leeds NE, Zimmerman RD, Elkin CM, Nussbaum M, LeVan AM. Neurosarcoidosis of the brain and meninges. *Semin Roentgenol* 1985; 20(4):387-392
 23. Clark WC, Acker JD, Dohan FC, Robertson JH. Presentation of central nervous system sarcoidosis as intracranial tumors. *J Neurosurg* 1985;63:851-856
 24. Sherman JL, Hayes WS, Stern BJ, Citrin CM, Pulaski PD. MR evaluation of intracranial sarcoidosis: comparison with CT. Presented at the annual meeting of the American Society of Neuroradiology, New York City, May 1987
 25. Mirfakhraee M, Crofford MJ, Guinto FC, Nauta HJW, Weedn VW. Virchow-Robin space: a path of spread in neurosarcoidosis. *Radiology* 1986; 158:715-720
 26. Delaney P. Neurologic manifestations in sarcoidosis. *Ann Intern Med* 1977;87:336-345
 27. Herring AB, Ulrich H. Sarcoidosis of the central nervous system. *J Neurol Sci* 1969;9:405-422
 28. Rosenbloom MA, Uphoff DF. Association of progressive multifocal leukoencephalopathy and sarcoidosis. *Chest* 1983;83:572-575
 29. Ricker W, Clark M. Sarcoidosis. A clinicopathologic review of three hundred cases including twenty-two autopsies. *Am J Clin Pathol* 1949;19:725
 30. Waxman JS, Sher JH. The spectrum of central nervous system sarcoidosis. A clinical and pathologic study. *Mt Sinai J Med (NY)* 1979;46(3):309-317
 31. Wiederholt WC, Siekert RG. Neurological manifestations of sarcoidosis. *Neurology* 1965;15:1147-1154
 32. Cariski AT. Isolated CNS sarcoidosis. *JAMA* 1981;245(1):62-63
 33. Kinnman J, Link H. Intrathecal production of oligoclonal IgM and IgG in CNS sarcoidosis. *Acta Neurol Scand* 1984;69:97-106
 34. Jabs DA, Johns CJ. Ocular involvement in chronic sarcoidosis. *Am J Ophthalmol* 1986;102:297-301
 35. Bachman DM, Rosenthal AR, Beckingsale AB. Granulomatous uveitis in neurological disease. *Br J Ophthalmol* 1985;69:192-196
 36. Spalton DJ, Sanders MD. Fundus changes in histologically confirmed sarcoidosis. *Br J Ophthalmol* 1981;65:348-358
 37. Lightman S, McDonald WI, Bird AC, et al. Retinal venous sheathing in optic neuritis: its significance for the pathogenesis of multiple sclerosis. *Brain* 1987;110:405-414
 38. Matthews WB. Symptoms and signs continued. In: Matthews WB, Acheson ED, Batchelor JR, Weller RO, eds. *McAlpine's multiple sclerosis*. New York: Churchill Livingstone, 1985:119-122
 39. Beardsley TL, Brown SVL, Sydnor CF, Grimson BS, Klintworth GK. Eleven cases of sarcoidosis of the optic nerve. *Am J Ophthalmol* 1984;97:62-77
 40. Rush JA. Retrobulbar optic neuropathy in sarcoidosis. *Ann Ophthalmol* 1980;12(4):390-394
 41. Sigal LH. The neurologic presentation of vasculitic and rheumatologic syndromes. *Medicine (Baltimore)* 1987;66(3):157-180
 42. Alexander EL, Malinow K, Lejewski BS, Jerdan MS, Provast TT, Alexander GE. Primary Sjögren's syndrome with central nervous system disease mimicking multiple sclerosis. *Ann Intern Med* 1986;104:323-330
 43. Hocannberg MC. Adult and juvenile rheumatoid arthritis: current epidemiologic concepts. *Epidemiol Rev* 1981;3:27-44
 44. Rudick RA, Schiffer RB, Schwetz KM, Herndon RM. Multiple sclerosis. The problem of incorrect diagnosis. *Arch Neurol* 1986;43:578-583