

Generic Contrast Agents

Our portfolio is growing to serve you better. Now you have a *choice*.



FRESENIUS
KABI

[VIEW CATALOG](#)

AJNR

A modified transparent angiography catheter: preliminary in vivo and in vitro evaluations.

H S Ahn and J H Anderson

AJNR Am J Neuroradiol 1989, 10 (3) 587-588

<http://www.ajnr.org/content/10/3/587.citation>

This information is current as
of May 7, 2025.

A Modified Transparent Angiography Catheter: Preliminary In Vivo and In Vitro Evaluations

Hyo S. Ahn¹ and James H. Anderson

Most of the serious neurologic complications related to angiography are embolic in nature. Meticulous catheter flushing techniques have been suggested to reduce embolic complications [1]. An experimental catheter with a 20-cm-long transparent proximal section has been evaluated to determine its usefulness in monitoring catheter flushing procedures and inadvertent injections of emboli. Catheters that are transparent throughout their entire length may not have enough radiopacity or torque control to enable adequate manipulation. Replacing the proximal portion of the catheter with a transparent tubing preserves maneuverability of the original catheter while allowing direct visualization of the extravascular portion of the catheter lumen. We report our initial experience with this modified transparent catheter.

Materials and Methods

Catheter Design

The modified catheter was constructed by replacing the proximal 20-cm portion of a 5-French polyethylene cerebral angiography catheter* with a transparent polyethylene tubing (ID, 1.40 mm; OD, 1.90 mm).† One end of the tubing was bonded to the original catheter with cyanoacrylate glue, and the other end was connected to a blunt-tip needle (16 g) (Fig. 1).

In Vitro Evaluation

In vitro experiments were carried out to evaluate the use of the catheter in detecting inadvertent introduction of emboli. Small Gelfoam particles (3 × 3 × 3 mm), suspended in saline, were loaded into 3- and 10-ml plastic syringes and injected slowly (approximately 1 ml/sec) through the modified transparent catheter. When a Gelfoam particle was detected traveling through the transparent portion of the catheter, the injection procedure was immediately terminated and the particle was retrieved into the syringe by withdrawing the plunger. This experiment was repeated 20 times with each syringe.

In Vivo Study

In vivo experiments evaluated use of the catheter during catheter flushing procedures. The left common carotid artery of an anesthetized 55-lb mongrel dog was selectively catheterized with the modified transparent catheter via the femoral artery approach. The catheter was connected to a volumetric infusion pump‡ via a three-way stopcock. The catheter was filled with undiluted blood by aspirating it with a syringe via the remaining port of the stopcock. The stopcock was then opened to allow flush solution to enter the catheter. Clearing of blood in the catheter lumen by the flush solution with various infusion rates (10, 30, 50, 75, 100, 250, and 500 ml/hr) was monitored for 3 min for each infusion rate under direct visual inspection.

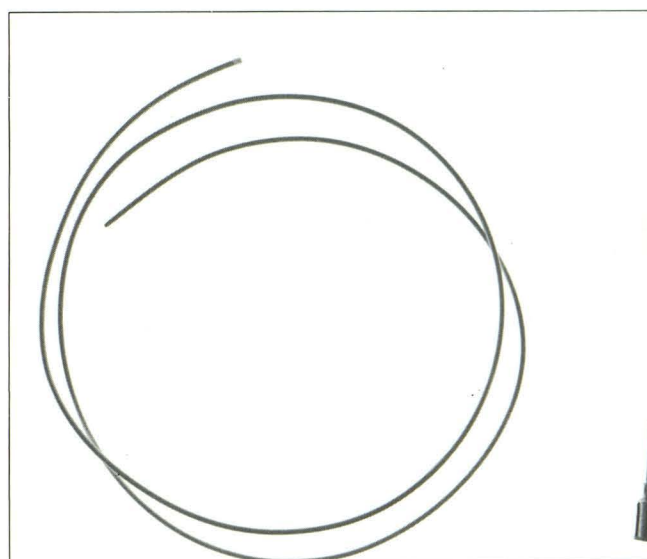


Fig. 1.—Proximal 20 cm of a 5-French polyethylene catheter was replaced with the same length of transparent polyethylene tubing (ID, 1.40 mm; OD, 1.90 mm). The two were connected by sliding the tubing over the catheter and gluing together the outer surfaces. The blunt-tip needle can be eliminated by flaring the proximal end of the polyethylene tubing and connecting standard adapters.

* Becton Dickinson, Rutherford, NJ.

† Clay Adams, Parsippany, NJ.

‡ Travenol Laboratories, Inc., Deerfield, IL.

Received April 27, 1988; accepted after revision October 25, 1988.

¹ Both authors: The Russell H. Morgan Department of Radiology and Radiological Sciences, Johns Hopkins Medical Institutions, 601 N. Wolfe St., Baltimore, MD 21205. Address reprint requests to H. S. Ahn.

Results

Gelfoam particles injected into the catheter were easily detected as they passed through the transparent portion of the catheter. All 40 particles were easily retrieved before they could exit from the catheter tip.

Transparency of the catheter allowed us to evaluate the effectiveness of various flow rates in clearing blood in the lumen under direct visual inspection. When the blood-filled catheter was connected to a volumetric infusion pump with infusion rates between 10 and 100 ml/hr, clearing of blood in the transparent portion of the catheter was slow. Layering of blood in the dependent portion of the catheter persisted throughout the experiment (3 min). Complete clearing of blood in the transparent portion of the catheter was achieved within 30 and 90 sec with a flow rate of 500 and 250 ml/hr, respectively. Once complete clearing of the transparent portion of the catheter was achieved, a decrease in the infusion rate to 30 and 50 ml/hr effectively prevented reflux of blood into the transparent portion of the catheter.

Discussion

The frequency of all neurologic complications of cerebral angiography varies from 0.9% to 4.6% [2-4]. Most complications related to catheter angiography are caused by emboli [1]. The reported frequency of inadvertent embolization during cerebral angiography is 0.4% by Olivecrona [4] and 0.9% by Pettersson et al. [5]. Emboli originate from three main sources: (1) dislodged thrombus or plaque from the intima of vessels during manipulation of catheters or guidewires, (2) thrombus dislodged from the inner surface of the catheter during injections of contrast material or saline, or by guidewire manipulation, and (3) inadvertent injections of blood clots and foreign bodies such as air bubbles and cotton fibers. Damage to vessel walls is minimized by using small-diameter catheters made of soft plastic [6]. Various technical improvements have been reported to reduce embolic complications. Heparin-coated catheters reduce thrombus formation in the inner surface of the catheters [7]. Closed systems of contrast media and flush solutions have been advocated to avoid contamination by foreign bodies [8-10]. Cronqvist et al. [11] suggested that a constant infusion of saline instead of intermittent injections may be of value in preventing intraluminal clot formation. Kido et al. [7] indicated that the rate of thrombus formation on the inner surface of the catheter is largely related to the amount of blood that is allowed to reflux into the catheter lumen. An ideal infusion rate for a particular patient is difficult to determine and may vary according to the patient's blood pressure and size of the catheter being used. To avoid overhydrating the patient, a low infusion rate that can effectively clear the catheter of blood is desirable. However, as we observed, flushing the catheter with a low infusion rate resulted in layering of blood in the dependent portion of the catheter. Therefore, it is suggested that the catheter be flushed at a high infusion rate for a few seconds at the beginning of the flush and then decreased to an effective low rate. The modified catheter may not have advantages over regular catheters in preventing injection of thrombi formed in

the nontransparent portion of the catheter but it may decrease the occurrence of thrombi formation on the inner surface of the catheter, since one can directly visualize and improve the status of flush in the catheter. Our results indicate the modified transparent catheter may be of value in preventing the inadvertent injections of emboli and in maintaining thorough flushing of the catheter.

In daily clinical practice, some 20-30 cm of the catheter would remain extravascular. By replacing some of this extravascular portion of the catheter with transparent material, an extra margin of safety can be achieved while maintaining the original properties of radiopacity and stiffness. Since the transparent tubing does not have a sufficient stiffness for torque control, the length of the transparent portion is adjusted to provide a sufficient portion of the original catheter proximal to the skin for catheter manipulation. In the present study, a 5-French catheter was used to make the modified transparent catheter. However, this modification can be easily achieved on any size catheter. Injector-connecting tubes and IV-infusion tubings now being used in angiographic procedures are transparent as a safety feature to reduce the possibility of inadvertently injecting air bubbles, emboli, and so forth. Angiographers would benefit by having extended transparent tubings as provided by the modified catheter. This prototype catheter was assembled purely for evaluation purposes. We do not recommend gluing the catheters together for clinical use. The bonding site remained intact through the experiments but we did not measure the force required to break the bond.

The clinical efficacy of a modified transparent catheter needs to be evaluated through clinical trials. The results of the preliminary work are encouraging and should stimulate manufacturers to consider providing such a catheter for evaluation and possible clinical use.

REFERENCES

1. Newton TH, Kerber CW. Techniques of catheter cerebral angiography. In: Newton TH, Potts DG, eds. *Radiology of the skull and brain: angiography*. St. Louis: Mosby, 1977:920-938.
2. Mani RL, Eisenberg RL, McDonald EJ, Pollack JA, Mani JR. Complications of catheter cerebral arteriography: analysis of 5000 procedures. I. Criteria and incidence. *AJR* 1978;131:861-865.
3. Earnest T, Forbes G, Sandok BA, et al. Complications of cerebral angiography: prospective assessment of risk. *AJNR* 1983;4:1191-1197.
4. Olivecrona H. Complications of cerebral angiography. *Neuroradiology* 1977;14:175-181.
5. Pettersson H, Fitz CR, Harwood-Nash DEF, Chuang S, Armstrong E. Iatrogenic embolization: complication of pediatric cerebral angiography. *AJNR* 1981;2:357-361.
6. Mani RL. A new double-curve catheter for selective femorocerebral angiography. *Radiology* 1970;94:607-611.
7. Kido DK, Paulin S, Alenghat JA, Waternaux C, Riley WD. Thrombogenicity of heparin- and non-heparin-coated catheters: clinical trial. *AJNR* 1982;3:535-540. *AJR* 1982;139:957-961.
8. Adams DF, Olin TB, Kosek J. Cotton fiber embolization during angiography. A clinical and experimental study. *Radiology* 1965;84:678-681.
9. Mishkin MM. Petechial reactions in angiography. *Acta Radiol [Diagn] (Stockh)* 1966;5:413-423.
10. O'Reilly GV, Hammerschlag SB, Naheedy MH. Closed reservoir system for angiography. *AJNR* 1982;3:683-684.
11. Cronqvist S, Efsing HO, Palacios E. Embolic complications in cerebral angiography with the catheter technique. *Acta Radiol [Diagn] (Stockh)* 1970;10:97-107.