

Generic Contrast Agents

Our portfolio is growing to serve you better. Now you have a *choice*.



FRESENIUS
KABI

[VIEW CATALOG](#)

AJNR

Gd-DTPA-enhanced MR imaging of pituitary adenomas.

D R Newton, W P Dillon, D Norman, T H Newton and C B Wilson

AJNR Am J Neuroradiol 1989, 10 (5) 949-954

<http://www.ajnr.org/content/10/5/949>

This information is current as
of May 15, 2025.

Gd-DTPA-Enhanced MR Imaging of Pituitary Adenomas

Diane R. Newton¹
 William P. Dillon¹
 David Norman¹
 Thomas H. Newton¹
 Charles B. Wilson²

Eleven previously nonoperated patients with suspected pituitary microadenomas were scanned on a 1.5-T GE system before and after administration of IV gadolinium-DTPA (0.1 mmol/kg). Six patients had Cushing disease, four had hyperprolactinemia, and one had acromegaly. Surgical confirmation was available in all cases, and these findings were correlated with results of CT and venous sampling, when available. The normal pituitary gland, infundibulum, and cavernous sinuses enhance immediately after the administration of gadolinium-DTPA, allowing contrast between the enhancing normal glandular tissue and low-intensity microadenomas. Contrast-enhanced MR detected a lesion not seen on the unenhanced images in two patients with Cushing disease and in one patient with hyperprolactinemia. Tumor delineation was improved with gadolinium administration in two additional cases. In six patients, administration of gadolinium did not significantly alter the precontrast interpretation. Adenomas were found at surgery in all 11 patients. The tumor was correctly localized on MR in four of the six patients with Cushing disease, resulting in an accuracy of 66.7%. In another patient, although a focal lesion was detected on MR, location of the adenoma at surgery was discrepant with the MR findings and was therefore considered a false-positive study. In the single false-negative examination, both pre- and postcontrast MR failed to detect a surgically confirmed microadenoma suspected on both contrast-enhanced CT and venous sampling. Correct localization of the adenoma was achieved in all of the five non-Cushing patients, yielding an accuracy of 100%. Immediate T1-weighted coronal scans were most useful in detecting intrasellar disease. Delayed scans obtained 30 min after injection did not improve the differentiation of pituitary gland from microadenoma.

Gadolinium-enhanced MR of the sella is helpful in evaluating patients with suspected microadenomas in whom noncontrast studies are not definitive. Diagnostic accuracy may improve in the future by the use of faster scanning techniques to maximize the immediate postcontrast interface between normal gland and tumor.

AJNR 10:949-954, September/October 1989

Received October 6, 1988; revision requested November 23, 1988; revision received March 15, 1989; accepted March 31, 1989.

Presented at the annual meeting of the American Society of Neuroradiology, Chicago, May 1988.

¹ Department of Radiology, University of California, San Francisco, 505 Parnassus Ave., San Francisco, CA 94143. Address reprint requests to W. P. Dillon.

² Department of Neurosurgery, University of California, San Francisco, CA 94143.

0195-6108/89/1005-0949

© American Society of Neuroradiology

The importance of accurate preoperative localization of pituitary microadenomas has increased with the advent of transsphenoidal microsurgical techniques. MR imaging in the coronal and sagittal planes has proved useful in the evaluation of patients with suspected pituitary disease, with excellent delineation of the contour of the gland caused by intensity differences between soft tissue, CSF, and vessels [1-5]. However, insufficient inherent contrast between normal gland and adenoma sometimes precludes definitive diagnosis [6, 7]. By optimizing the interface between normal and abnormal tissue, Gd-DTPA-enhanced MR imaging may prove useful in detecting small intrasellar lesions [4, 8, 9]. To assess the role of Gd-DTPA-enhanced MR imaging at 1.5 T in the evaluation of suspected pituitary adenomas, we studied 11 previously nonoperated patients with biochemical and/or clinical evidence of Cushing disease, hyperprolactinemia, or acromegaly in whom surgical confirmation subsequently became available.

Materials and Methods

To date we have performed over 60 gadolinium-enhanced studies on patients with suspected pituitary tumors. Surgical confirmation of MR findings in previously nonoperated patients has thus far been available in 11. These form the basis of this paper. All patients were imaged on a 1.5-T GE system before and after IV administration of Gd-DTPA. The patient group consisted of 10 women and one man, 19 to 67 years old. Six patients had clinical and biochemical stigmata of Cushing disease, four had an elevated serum prolactin level, and one was acromegalic. All 11 patients had transsphenoidal surgery at this institution, performed by one neurosurgeon.

The MR technique consisted of precontrast T1-weighted, 600/20/4 (TR/TE/excitations), scans through the sella in the sagittal and coronal planes with 3-mm slices and a 0.5-mm interslice gap. Additional T1-weighted (600/20) scans were subsequently obtained in the coronal plane either immediately or 10 min after injection of Gd-DTPA, 0.1 mmol/kg. In some patients, immediate T1-weighted sagittal and/or delayed (30 min) T1-weighted coronal scans were also acquired. Images were reconstructed with a two-dimensional Fourier transform on a 256×256 image matrix.

Pre- and postcontrast images were reviewed separately by three observers. The presence of a lesion, its location and size, and associated abnormalities of the contour of the gland were evaluated. In each case, the diagnosis of a definite adenoma was assigned a score of 2, a probable lesion was given a score of 1, and absence of a lesion received a score of 0. Deviation of the infundibulum, displacement of the posterior pituitary lobe, and extension of tumor into the cavernous sinus were also assessed. Findings were correlated with results of CT and venous sampling, when available, and with surgical findings provided by the neurosurgeon.

Results

Results of MR examinations, correlated with clinical history, CT, venous sampling results, and surgical findings are summarized in Table 1.

Lesion Detection

Adenomas were identified as low-intensity lesions on unenhanced scans and as focal areas of relative nonenhancement on images obtained immediately after gadolinium administration. At surgery, tumors were found to range from 3 to 12 mm in diameter. T1-weighted coronal images were most useful in the detection of tumors. Delayed coronal scans obtained in three patients approximately 30 min after injection did not contribute significant additional information. In two patients with Cushing disease and one patient with an elevated serum prolactin level, a focal nonenhancing lesion not evident on the unenhanced scan was identified after administration of gadolinium (Fig. 1). The presence of a tumor and its location on the postcontrast examination were graded as probable in the two Cushing patients and definite in the non-Cushing patient. In one patient with Cushing disease and one patient with elevated serum prolactin level, a probable lesion identified on the precontrast study was more clearly delineated after contrast administration, and the score for presence of a lesion was upgraded to definite (Fig. 2). In the remaining six patients, administration of contrast medium did not significantly alter the precontrast interpretation. In one of these

cases, both pre- and postcontrast MR failed to detect a surgically confirmed 5-mm ACTH-secreting microadenoma despite positive CT and venous sampling results (Fig. 3). All lesions that were seen on the unenhanced scan were also identified on the gadolinium-enhanced study.

All studies were reviewed independently by the three neuroradiologists, and individual scores were recorded. Pre- and postcontrast MR scans for each patient were distributed randomly to each reviewer. No history (other than the inherent fact that the patient had undergone transsphenoidal surgery since the MR study) was given to the reviewers. In the majority of cases there was agreement in findings between the original prospective film interpreter and the retrospective reviewers, as well as among the three neuroradiologists. In most of the cases, one of the three reviewers had prospectively interpreted the study. There was disagreement among the three reviewers as to the probable presence (+1) or absence (0) of an adenoma on the unenhanced scan in two patients. In both cases, the highest score (+1) was assigned. However, all three radiologists graded the postgadolinium MR studies in these two patients as demonstrating a definite lesion (+2). In one case, the original prospective report suggested a probable right-sided microadenoma seen only after contrast administration. However, the tumor was thought to be midline in location by all three reviewers, a finding corroborated at surgery.

Ancillary MR Findings

Ancillary MR findings such as deviation of the pituitary stalk and posterior pituitary lobe and cavernous sinus invasion were reviewed in each case. In eight patients, no ancillary findings were present. Slight overall enlargement of the gland was present in one patient, without a focal contour abnormality. The infundibulum was deviated contralateral to the side of the suspected lesion in one patient and to the left in a patient with a midline adenoma. Displacement of the posterior lobe or cavernous sinus involvement was not identified in any patient. Erosion of the sellar floor was present in another patient with a macroadenoma located predominantly within the sphenoid sinus.

Correlation with CT and Venous Sampling

A thin-section, contrast-enhanced CT scan was available in one patient with Cushing disease and was suspicious for a surgically confirmed, 5-mm, nonenhancing lesion not seen on either the pre- or postcontrast MR study (Fig. 3).

Four patients with Cushing disease underwent selective bilateral inferior petrosal sinus and internal jugular vein sampling for determination of ACTH levels. In two patients, venous sampling results correctly predicted tumor location. A definite left-sided gradient was present in one patient with a midline adenoma. In an additional patient, venous sampling was unrevealing in spite of a definite right lateral wing adenoma on the contrast-enhanced MR scan that was subsequently confirmed at surgery.

TABLE 1: Summary of Findings

Patient No.	Clinical	Focal Lesion Pre/Post	Location	Size (mm)	Ancillary MR	CT	Venous Sampling	Surgical
1	Cushing	0/+1	Mid	5	Stalk deviated to left		L > R	6-mm adenoma, mid gland
2	Cushing	0/+1	Mid	3	Slightly enlarged gland stalk deviated to right		L > R	4-mm adenoma, left mid gland
3	Cushing	+1/+2	Right	3			No gradient	4-mm adenoma, right lateral wing
4	Cushing	+2/+2	Left	3				2-3-mm adenoma, left gland
5	Cushing	+1/+1	Left	4-5				5-mm adenoma, right lateral wing
6	Cushing	0/0	0	0		Probable focal lesion, right	R > L	5-mm adenoma, right mid gland
7	Hyperprolactinemia	0/+2	Left	5				5-mm adenoma, left gland
8	Hyperprolactinemia	+1/+2	Left	5				6-mm adenoma, left gland
9	Hyperprolactinemia	+1/+1	Right	5				6-mm adenoma, right gland
10	Hyperprolactinemia	+2/+2	Central, largely extrasellar in sphenoid sinus	15	Erosion of sellar floor			12-mm intra- and extrasellar (sphenoid sinus) adenoma
11	Acromegaly	+2/+2	Right cavernous sinus	8				5-6-mm adenoma, right cavernous sinus

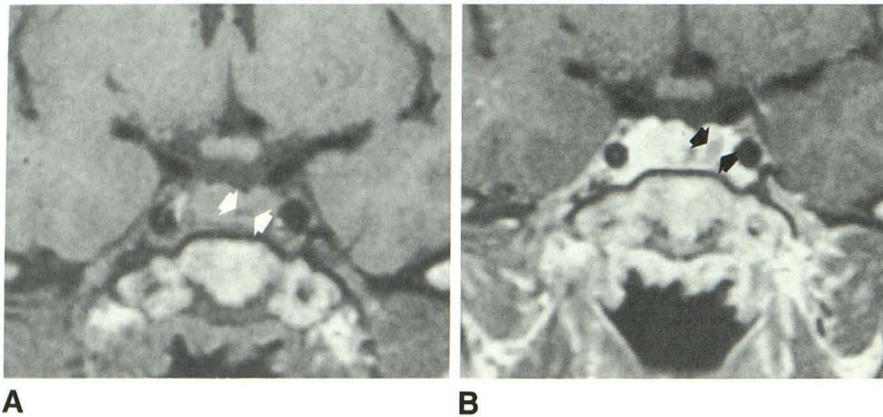


Fig. 1.—Case 7: 19-year-old woman with elevated serum prolactin level.

A, Noncontrast short TR (600/20) coronal section discloses a small, low-intensity lesion just to left of midline (arrows).

B, On short TR (600/20) coronal scan immediately after contrast administration, there is a definite (+2) 5-mm left-sided nonenhancing lesion (arrows), not evident on unenhanced study. This proved to be a 5-mm adenoma at surgery. The more medial, smaller, low-intensity lesion most likely represents a pars intermedia cyst.

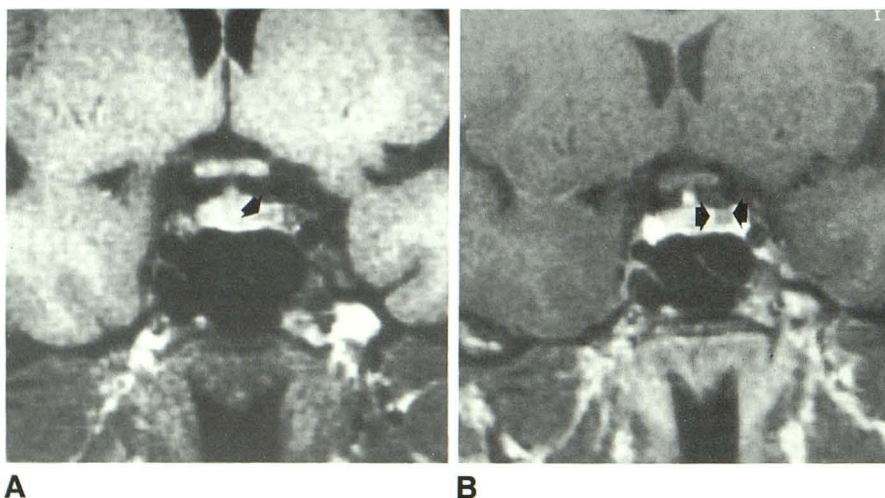


Fig. 2.—Case 10: 37-year-old woman with hyperprolactinemia.

A, Unenhanced short TR (600/20) coronal scan reveals a probable (+1) 5-mm left-sided adenoma (arrow).

B, The microadenoma (arrows) is seen to better advantage on Gd-enhanced short TR (600/20) study, upgrading the score for lesion presence to definite (+2). Findings were confirmed at surgery.

Correlation with Surgical Results

Correlation of surgical results with MR findings is presented in Table 2. In nine patients (four Cushing and five non-Cushing), the postgadolinium MR studies correctly predicted the location and size of the tumor. In three of these nine patients (two Cushing and one non-Cushing) the tumor was not detected on the unenhanced scan.

There was one false-positive study in a patient with Cushing disease. In this patient, a probable 4–5-mm left-sided lesion was detected on both the pre- and postcontrast MR scans. However, the surgical report describes a 5-mm adenoma situated within the right lateral wing. Despite confirmation of the presence of a microadenoma, this was considered to be a false-positive study given the discrepancy in location between the MR and surgical findings (Fig. 4).

In the single false-negative study, pre- and postcontrast MR failed to detect a surgically confirmed 5-mm ACTH-secreting adenoma that was suspected on contrast-enhanced CT and confirmed by venous sampling (Fig. 3).

Discussion

Previous studies have documented the utility of MR in evaluating patients with suspected pituitary pathology [1–4,

7, 8, 10]. Kucharczyk et al. [3] detected 10 of 11 microadenomas as foci of low signal intensity on T1-weighted images by using a 1.5-T magnet. These findings were corroborated in a subsequent study at 1.5 T by Kulkarni et al. [4], in which eight of eight microadenomas were demonstrated. However, despite advances in MR imaging techniques, microadenomas may elude detection. Pojunas et al. [8] failed to detect five of 11 prolactin-secreting microadenomas at 1.5 T. There has been recent evidence that a small percentage of adenomas not visible on noncontrast MR can be detected on Gd-enhanced MR. In a study using a 0.5-T scanner, two of 12 ACTH-secreting tumors were seen only after contrast administration [5]. A more recent study at 1.5 T demonstrated two of eight ACTH-secreting microadenomas only after administration of gadolinium [11].

ACTH-secreting tumors are known to be difficult to detect because of their small size at the time of presentation. The larger mean size of adenomas in our patients with hyperprolactinemia and acromegaly (7 mm) compared with the Cushing patients (4.5 mm) may in part account for the higher diagnostic accuracy of MR in the non-Cushing group. In this series, four (66.7%) of six ACTH-secreting adenomas were correctly localized. In two of these patients (33.3%), the tumors were detected only after gadolinium administration. Both pre- and

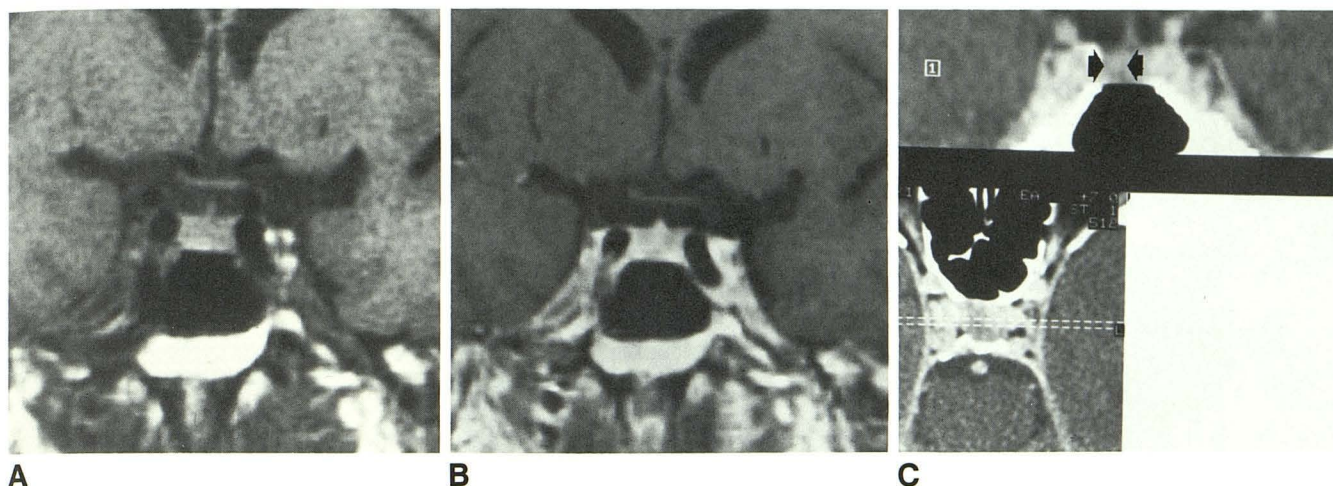


Fig. 3.—Case 6: 52-year-old man with Cushing disease.
 A and B, Both unenhanced (A) and Gd-enhanced (B) short TR (600/20) coronal scans fail to detect a microadenoma.
 C, Contrast-enhanced, thin-section CT scan shows a subtle area of nonenhancement in right gland (arrows). Venous sampling corroborated this finding, and surgical exploration confirmed the presence of a 5-mm right-sided microadenoma.

TABLE 2: Correlation of Surgical Results with MR Scans

Finding	Positive Only on Pre-Gd- DTPA Study	Positive Only on Post-Gd- DTPA Study	Positive on Both Pre- and Post-Gd-DTPA Studies
Cushing disease (n = 6)			
True positive (n = 4)	0	2	2
False positive (n = 1)	0	0	1
False negative (n = 1)	0	0	0
Non-Cushing disease (n = 5)			
True positive (n = 5)	0	1	4

postcontrast MR failed to accurately localize adenomas in two patients (33.3%).

Diagnostic accuracy was higher in the five patients with either prolactin- or growth-hormone-secreting adenomas, with all five adenomas detected on MR (100%). In this patient group, administration of gadolinium demonstrated one adenoma (20%) not visible on the noncontrast study.

The normal pituitary gland and infundibulum show marked, homogeneous enhancement after IV administration of Gd-DTPA, owing to the absence of a blood-brain barrier around these structures [5, 9, 12, 13]. It should be noted, however, that there may be some inhomogeneity of the enhancement pattern within normal glands, a finding previously described in both the CT and MR literature [14, 15]. These differences in degree of contrast enhancement have been attributed to tissue compactness, granularity, and vascularity. It is possible that this variable inhomogeneity of the normal gland may account for occasional false-positive MR studies.

In our single false-negative study, both pre- and postcontrast MR failed to detect a proved 5-mm adenoma suspected on contrast-enhanced CT and confirmed with venous sampling. Isointense adenomas have been described previously [3, 5, 7–9, 11]. Since the adenoma is a benign proliferation of a cell type normally present within the pituitary gland, it seems plausible that not all adenomas will manifest signal intensity or enhancement appreciably different from that of normal gland. In addition, contour abnormality and other ancillary findings are often absent in individuals with small microadenomas. In these cases, timing of sequence acquisition after gadolinium administration may be a critical factor in tumor detection. Enhancement of the pituitary gland persists for approximately 1 hr but is typically maximal or nearly maximal at 3 min [5, 13]. Adenomas also imbibe contrast but generally enhance more slowly and persistently than normal gland [5, 13]. Selective enhancement of the normal pituitary relative to adenoma immediately after contrast injection should therefore improve lesion conspicuity. On later images, delayed enhancement of the lesion relative to normal gland may lead to a reversal in signal intensities. This “flip-flop” phenomenon has been described in soft or semiliquid lesions, which are dark on unenhanced and immediate post-contrast-enhanced scans and become bright on delayed images [5, 11]. In some cases, therefore, there is an intermediate period during which a lesion may be isointense with adjacent normal tissue, and gadolinium might obscure rather than facilitate detection [5, 11].

Preliminary results of gadolinium-enhanced MR scans in patients with recurrent disease at this institution are less encouraging, and are not included in this paper owing to the small number of reoperated patients at the present time. Poor correlation between MR and surgical findings in patients with recurrent disease may relate to distortion of the gland as a result of previous surgery, with poor differentiation of inflammatory changes from tumor. In addition, gross evaluation of glandular architecture at the time of surgery may be hindered

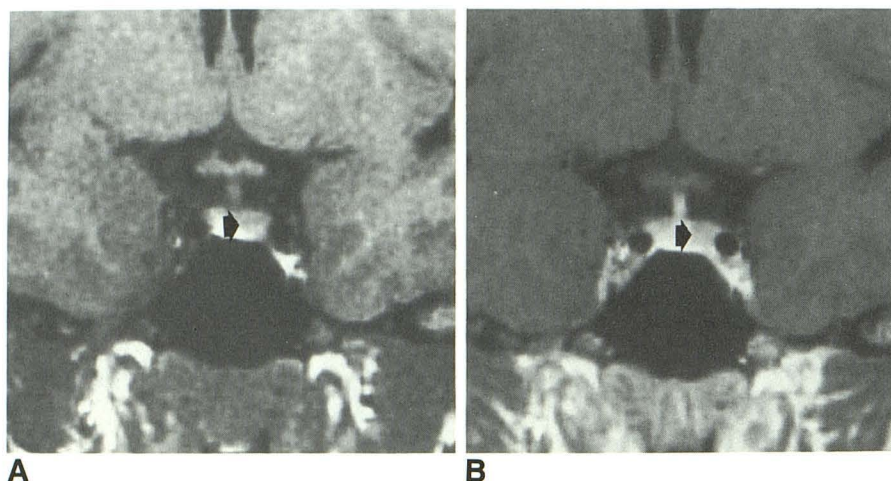


Fig. 4.—Case 5: 31-year-old woman with Cushing disease.

A and B, Probable (+1) 4–5-mm left-sided microadenoma (arrow) is seen on both the unenhanced (A) and Gd-enhanced (B) short TR (600/20) coronal scans. However, the surgical report describes a 5-mm adenoma in right lateral wing. Given the discrepancy in location between the MR and surgical findings, this was considered to be a false-positive study.

by postoperative changes, making surgical correlation difficult. This is clearly an area that needs further research.

Diagnostic accuracy may improve in the future by the use of faster scanning techniques to maximize the immediate postcontrast interface between normal gland and tumor. Additionally, very small intrasellar lesions may be identified in the near future by the application of gradient-recalled 3DFT imaging with thinner slice profiles without the need for an interslice gap [16].

REFERENCES

1. Bilaniuk LT, Zimmerman RA, Wehrli FW, et al. Magnetic resonance imaging of pituitary lesions using 1.0 to 1.5 T field strength. *Radiology* 1984;153:415–418
2. Lee BCP, Deck MDF. Sellar and juxtasellar lesion detection with MR. *Radiology* 1985;157:143–147
3. Kucharczyk W, Davis DO, Kelly WM, et al. Pituitary adenomas: high-resolution MR imaging at 1.5 T. *Radiology* 1986;161:761–765
4. Kulkarni MKV, Lee FK, McArdle CB, et al. 1.5-T MR imaging of pituitary microadenomas: technical considerations and CT correlation. *AJNR* 1988;9:5–11
5. Dwyer AJ, Frank JA, Doppman JL, et al. Pituitary adenomas in patients with Cushing disease: initial experience with Gd-DTPA-enhanced MR imaging. *Radiology* 1987;163:421–426
6. Peck WW, Dillon WP, Norman D, et al. High-resolution MR imaging of microadenomas at 1.5 T: experience with Cushing disease. *AJNR* 1988;9:1085–1091, *AJR* 1989;152:145–151
7. Davis PC, Hoffman JC Jr, Spencer T, et al. MR imaging of pituitary adenoma: CT, clinical, and surgical correlation. *AJNR* 1987;8:107–112, *AJR* 1987;148:797–802
8. Pojunaas KW, Daniels DL, William AL, Haughton VM. MR imaging of prolactin-secreting microadenomas. *AJNR* 1986;7:209–213
9. Davis PC, Hoffman JC Jr, Malko JA, et al. Gadolinium-DTPA and MR imaging of pituitary adenoma: a preliminary report. *AJNR* 1987;8:817–823
10. Doms G, Mathurin P, Cornelis G, Demeure R. MRI of pituitary adenomas: role of Gd-DTPA. Presented at the 26th annual meeting of the American Society of Neuroradiology, Chicago, May 1988
11. Doppman JL, Frank JA, Dwyer AJ, et al. Gadolinium-DTPA-enhanced MR imaging of ACTH-secreting microadenomas of the pituitary gland. *J Comput Assist Tomogr* 1988;12:728–735
12. Kilgore DP, Breger RK, Daniels DL, et al. Cranial tissues: normal MR appearance after intravenous injection of Gd-DTPA. *Radiology* 1986;160:757–761
13. Breger RK, Papke RA, Pojunaas KW, et al. Benign extraaxial tumors: contrast enhancement with Gd-DTPA. *Radiology* 1987;163:427–429
14. Roppolo HMN, Latchaw RE. Normal pituitary gland: 2. Microscopic anatomy-CT correlation. *AJNR* 1983;4:937–944
15. Mark L, Pech P, Daniels D, et al. The pituitary fossa: a correlative anatomic and MR study. *Radiology* 1984;153:453–457
16. Schwartzberg DG, Brummer ME, Davis PC, et al. High-gradient 3DFT imaging of the pituitary gland. Presented at the 26th annual meeting of the American Society of Neuroradiology, Chicago, May 1988