



Get Clarity On Generics

Cost-Effective CT & MRI Contrast Agents



FRESENIUS
KABI

WATCH VIDEO

AJNR

Central Retinal Vein Occlusion After Treatment of Cavernous Dural Arteriovenous Malformation

Masanori Hashimoto, Akira Yokota, Shigeaki Matsuoka, Yoshiki Tsukamoto and Jun-Ichiro Higashi

AJNR Am J Neuroradiol 1989, 10 (5 suppl) S30-S31

http://www.ajnr.org/content/10/5_suppl/S30.citation

This information is current as
of August 6, 2025.

Central Retinal Vein Occlusion After Treatment of Cavernous Dural Arteriovenous Malformation

Masanori Hashimoto,¹ Akira Yokota,¹ Shigeaki Matsuoka,¹ Yoshiki Tsukamoto,² and Jun-Ichiro Higashi³

We present a case of central retinal vein (CRV) occlusion complicated by the embolization of the cavernous dural arteriovenous malformation (AVM) via the superior ophthalmic vein, and we discuss the mechanism of CRV occlusion.

Case Report

A 21-year-old man was admitted to our hospital in December 1986, with exophthalmos, conjunctival injection, mild abducens palsy, mild retrobulbar pain, and bruit on the right. Digital subtraction angiography (DSA) revealed a dural AVM of the right cavernous sinus portion fed by meningeal branches of the right internal carotid artery (Fig. 1A) and external carotid artery. The superior ophthalmic vein, which was markedly hypertrophic, was filled early in the arterial phase and drained into the facial vein. An embolization of the internal maxillary branch of the right external carotid artery was carried out with Ivalon

powder. The patient complained of sustained retrobulbar pain and bruit, and angiographically the dural AVM remained unchanged with feeding meningeal vessels from the right internal carotid artery. Embolization of the right cavernous sinus via the dilated superior ophthalmic vein was performed in August 1987. On carotid DSA, the cavernous sinus was seen not to be filled after two large steel coils (each 5 mm in diameter) and six smaller coils (each 3 mm in diameter) were released into it through a polyethylene catheter. Eleven days after the embolization, severe, persistent retrobulbar pain developed suddenly on the right. Internal carotid DSA showed partial recanalization of the dural AVM: patchy filling of the cavernous sinus, partial filling of the posterior part of the superior ophthalmic vein, and dilatation of the inferior ophthalmic vein (Fig. 1B). The facial vein, which had been the main draining pathway of the orbit, was not visualized, but intraorbital staining indicated marked venous stasis (Fig. 1C). Ophthalmoscopic examination showed small multiple retinal hemorrhages, and the arm-to-retina circulation time measured by

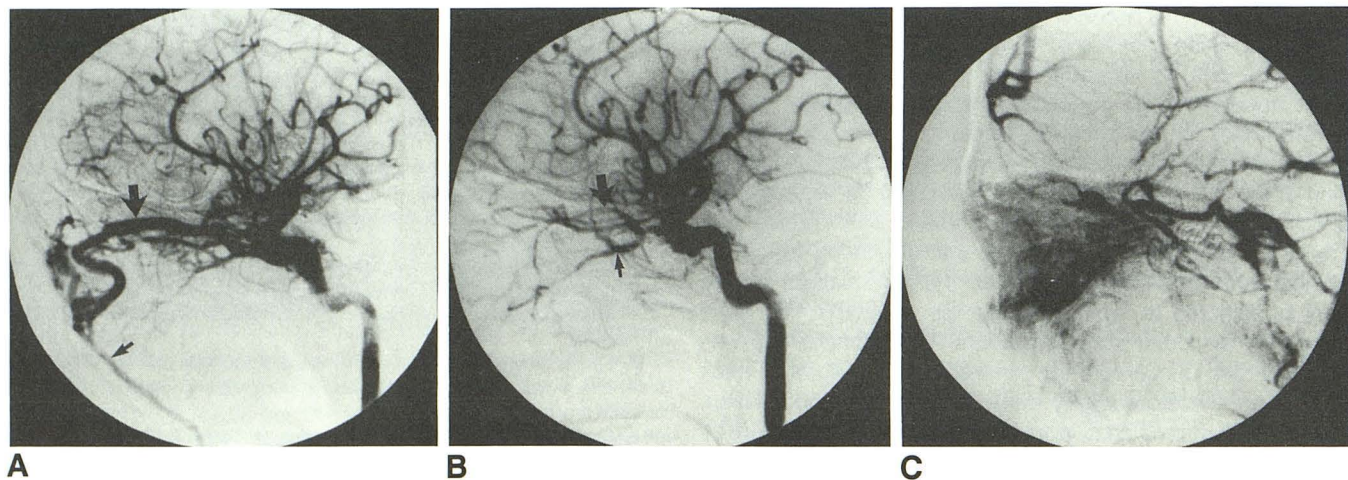


Fig. 1.—A, Digital subtraction angiography (DSA) on admission shows a dural arteriovenous malformation (AVM) of cavernous sinus fed by meningeal branches of right carotid artery. Superior ophthalmic vein (*large arrow*) is considerably hypertrophic and drains into facial vein (*small arrow*).

B and C, Right internal carotid DSA 11 days after embolization via superior ophthalmic vein shows partial recanalization of the dural AVM. Posterior part of superior ophthalmic vein (*large arrow*) and dilated inferior ophthalmic vein (*small arrow*) are visualized in arterial phase (B). Facial vein is not visualized, but intraorbital staining is marked in venous phase (C).

Received July 8, 1988; revision requested October 18, 1988; revision received January 20, 1989; accepted January 20, 1989.

¹ Department of Neurosurgery, University of Occupational and Environmental Health, Yahata Nishiku, Iseigaoka 1-1, Kitakyushu 807, Japan. Address reprint requests to M. Hashimoto.

² Department of Radiology, University of Occupational and Environmental Health, Yahata Nishiku, Iseigaoka 1-1, Kitakyushu 807, Japan.

³ Department of Ophthalmology, University of Occupational and Environmental Health, Yahata Nishiku, Iseigaoka 1-1, Kitakyushu 807, Japan.

means of fluorescein retinal angiography was prolonged, indicating CRV occlusion. The intraocular pressure increased gradually because of secondary glaucoma, and visual acuity has gradually deteriorated so that, at 15 months after the recanalization, the patient is only able to recognize hand movements 30 cm from the eyes.

Discussion

The treatment of a cavernous dural AVM is difficult, particularly when it is mainly fed by the meningeal branches of the internal carotid artery. Recently, transvenous embolization via the superior ophthalmic vein has been developed for such cases [1]. However, such embolization may cause the simultaneous obliteration of the main draining route from the orbit, such as the superior or inferior ophthalmic vein [2]. The most serious symptom resulting from the impairment of the orbital venous return is CRV occlusion [3], which is assumed to be the result of disturbance of the retinal venous return and the inflow of the retinal arterioles [4, 5].

In the present case, preoperative angiography showed that the retinal and other orbital venous flows were directed toward the facial vein through the superior ophthalmic vein with a high venous back pressure from the cavernous sinus. After the embolization of the arteriovenous fistula and the superior and inferior ophthalmic veins, the venous return from the orbit may have started to flow out anteriorly through anastomotic

veins at a critical rate. When recanalization of the fistula occurred after obliteration of the facial vein, the shunted intraorbital blood stagnated, resulting in increased intraorbital venous pressure. After this, both the elevation of the retinal venous pressure and the disturbance of the retinal arterial inflow may have caused the CRV occlusion.

Prevention of recanalization of the fistula is considered to be most important for avoiding CRV occlusion, but no effective means of prevention is as yet known. Physicians must be aware of this grave complication of embolization via the superior ophthalmic vein, particularly when large shunting in the fistula is suspected.

REFERENCES

1. Courtheoux P, Labbe D, Hamel C, Lecoq PJ, Jahara M, Théron J. Treatment of bilateral spontaneous dural carotid-cavernous fistulas by coils and sclerotherapy. Case report. *J Neurosurg* 1987;66:468-470
2. Doyon DL, Aron-Rosa DS, Ramée A. Orbital vein and cavernous sinus. In: Newton TH, Potts DG, eds. *Radiology of the skull and brain*, vol. 2. *Angiography*. St. Louis: Mosby, 1974:2220-2254
3. Jaeger EA. Venous obstructive disease of the retina. In: Duane TD, ed. *Clinical ophthalmology*, vol. 3. Philadelphia: Harper & Row, 1985: Chap. 15
4. Hayreh SS. So-called "central retinal vein occlusion." Part I. *Ophthalmologica* 1976;172:1-13
5. Hayreh SS. So-called "central retinal vein occlusion." Part II. *Ophthalmologica* 1976;172:14-37