

Generic Contrast Agents

Our portfolio is growing to serve you better. Now you have a *choice*.



FRESENIUS
KABI

[VIEW CATALOG](#)

AJNR

Comparison of MR imaging with clinical history in the identification of hemorrhage in patients with cerebral arteriovenous malformations.

D M Yousem, E S Flamm and R I Grossman

AJNR Am J Neuroradiol 1989, 10 (6) 1151-1154

<http://www.ajnr.org/content/10/6/1151>

This information is current as
of May 12, 2025.

Comparison of MR Imaging with Clinical History in the Identification of Hemorrhage in Patients with Cerebral Arteriovenous Malformations

David M. Yousem¹
Eugene S. Flamm²
Robert I. Grossman¹

Twenty-nine patients with true arteriovenous malformations as diagnosed by MR imaging or angiography were examined by MR to detect the presence of hemosiderin deposition, a marker for remote hemorrhage. The resulting information was compared with the clinical record to determine the frequency with which MR demonstrated prior hemorrhagic episodes where no clinical evidence for such episodes existed. Twenty (69%) of 29 patients with arteriovenous malformations showed evidence of acute or older hemorrhage. In four (14%) of 29 cases MR showed a hypointense signal on long TR images, suggesting hemosiderin, but no clinical history could account for prior hemorrhage. Additionally, six (21%) of 29 patients had a clinical history suggestive of acute hemorrhage, but no evidence of bleeding was found on MR.

The presence of prior or current hemorrhage is critical to deciding whether to surgically resect the arteriovenous malformation or to treat it conservatively, because of the high rate of rebleeding in patients presenting with hemorrhage or those with a history of this disorder. For this reason, MR imaging has an important role in the management of patients with arteriovenous malformations.

AJNR 10:1151-1154, November/December 1989

The symptoms associated with cerebral arteriovenous malformations (AVMs) may be caused by hemorrhage or by ischemia resulting from a steal phenomenon. Patients may present with seizures, acute headache, or progressive neurologic deficit; or they may have the AVM discovered serendipitously [1-10]. The treatment of cerebral AVMs depends on a number of factors, including the patient's age; the presence of pial or pial-dural supply; and the size, location, and depth of the lesion [1, 7, 11-15]. Definitive cure requires angiographic embolization, localized intensive radiation therapy, and/or surgical resection of the abnormal blood vessels. One of the most critical factors in the decision to treat the vascular malformation is a history of a prior hemorrhagic episode [3-5, 7, 9, 12, 13, 16, 17]. In the past, the presence of prior hemorrhage could only be inferred by a suggestive clinical history if the patient did not present with acute hemorrhage or did not have imaging studies documenting the hemorrhage at that time. MR has been shown to be exquisitely sensitive to the presence of blood breakdown products [18-21]. Hemosiderin, which has a characteristic hypointensity on short TR/TE, long TR/TE, and gradient-echo (GRE) scans, is an excellent marker for the presence of remote hemorrhage [18, 19, 21, 22]. MR has enabled the radiologist to detect remote hemorrhage even in the presence of negative or ambiguous clinical histories and unremarkable CT scans. We compared the occurrence of hemorrhagic events as determined by clinical history with the presence of acute, subacute, and chronic hemorrhagic products seen on MR images to determine the frequency of hemorrhage in patients with AVMs. In particular, the frequency of false-positive and negative clinical histories was stressed to emphasize the contribution of MR imaging to patient management.

Received January 19, 1989; revision requested March 15, 1989; revision received April 11, 1989; accepted April 25, 1989.

¹ Department of Radiology, Hospital of the University of Pennsylvania, Philadelphia, PA 19104. Address reprint requests to R. I. Grossman.

² Department of Neurosurgery, Hospital of the University of Pennsylvania, Philadelphia, PA 19104.

0195-6108/89/1006-1151

© American Society of Neuroradiology

Subjects and Methods

Since 1985, 29 true AVMs have been discovered or evaluated by MR imaging in our institution. Patients included 15 males and 14 females, 2–73 years old, with an average age of 27. True AVMs are defined as vascular anomalies in which large vessels with signal voids leading to a central nidus or large draining veins are seen on MR. Angiographic correlation, obtained in 20 of 29 cases, demonstrated characteristic tangled arrays of feeding arteries and draining veins. Capillary telangiectasis and cavernous, cryptic, and venous malformations were excluded from the study. All patients were imaged on a 1.5-T GE unit. The MR scanning protocols induced sagittal 500–700/20–30/2 (TR/TE/excitations) sequences with 5-mm-thick slices and 2.5-mm gaps, and a 128 × 256 matrix; and axial long TR double-echo sequences (2500–3500/30,80) with 5-mm-thick slices and 2.5-mm gaps, and 128–192 × 256 matrices. Occasional long TR coronal images and/or flow images using gradient recalled acquisition in the steady state (GRASS) were performed. The MR studies were reviewed retrospectively in the 29 patients to determine the presence of hemosiderin as a marker for chronic blood breakdown products. All MR examinations were taken within the 3 days of the clinical ictus so as to ensure that hemosiderin deposition would reflect prior episodes of hemorrhage rather than the acute presenting event.

Acute hemorrhage was said to be present when hypointense signal on long TR/TE scans and isointense signal on short TR/TE sequences were discovered. Subacute blood products showed hyperintensity on one or both sequences. Chronic hematoma classification required the presence of hypointensity on long TR or GRASS images attributable to the presence of hemosiderin.

The historical records of the patients were then examined to determine the frequency of clinical events that could have marked an episode of intracerebral bleeding. Specifically, we attempted to elicit a history of severe headaches, a transient neurologic event, a seizure,

or an episode involving a change in mental status or consciousness. The reviewer of the patients' records was blinded to the results of the MR analysis for hemosiderin. We believed that the occurrence of any of these constellations of symptoms more than a month prior to the patient's MR could explain the presence of hemosiderin if detected on the scan.

Results

Of the 29 patients with AVMs, nine showed no evidence of acute, subacute, or chronic blood products. Twenty (69%) of 29 patients had evidence of hemorrhage on MR; acute blood products were present in 10 of these 20 hemorrhagic cases (Table 1). Five of the 10 cases with acute hemorrhage also had evidence of hemosiderin. In three separate cases subacute hematoma was present: in one of these three patients hemosiderin deposition was present. Thus, 13 (45%) of 29 cases demonstrated acute or subacute hemorrhage, and hemosiderin was found in six (46%) of these 13 patients.

In seven other cases only hemosiderin was discovered—no acute or subacute blood products were seen. Thus, evidence of remote hemorrhage with hemosiderin deposition was present in a total of 13 patients. In four of these 13 patients there was no history, either near or remote, to explain the presence of hemosiderin. One patient was being evaluated for acute loss of consciousness and had acute and chronic blood products present. One had acute onset of a right hemiparesis and speech difficulties and showed evidence of acute hemorrhage as well as hemosiderin (Fig. 1). Another patient had multiple cutaneous hemangiomas and was being screened for brain lesions. An AVM and hemosiderin deposition was found. The fourth patient had a seizure for the first time; however, the MR demonstrated an AVM with hemosiderin, but no acute process.

Thus, in four (14%) of 29 patients the MR scan suggested prior episodes of hemorrhage, whereas no clinical history could be obtained to correlate with this finding.

In six (21%) of 29 cases an acute history of headache ($n = 4$), hemiparesis ($n = 1$), or tremors ($n = 1$) suggested an acute hemorrhagic event; however, an AVM with no evidence of acute or chronic intraparenchymal hemorrhage was found.

TABLE 1: Frequency of Hemosiderin Deposition in 29 AVM Patients

	No. of Patients with Hemorrhage (%)	No. of Hemorrhages with Hemosiderin (%)
Acute hemorrhage	10 (34)	5 (50)
Subacute hemorrhage	3 (10)	1 (33)
Hemosiderin alone	7 (24)	7 (100)
Total	20 (69)	13 (65)

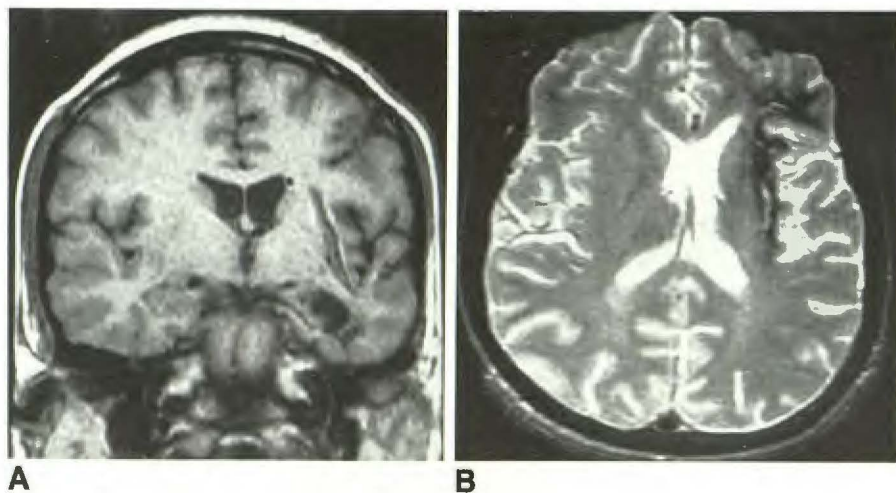


Fig. 1.—Unsuspected evidence of old hemorrhage in a patient with new onset of right hemiparesis and dysphasia.

A, Coronal 600/20 MR image shows linear area of low signal medial to left sylvian fissure. An area of encephalomalacia is seen inferiorly.

B, Axial 3000/80 MR image again shows signal void of hemosiderin deposition with faint hyperintense streak of methemoglobin being resorbed near left sylvian fissure.

An angiogram confirmed the presence of an AVM; the lesion was subsequently excised, and hemosiderin was present on pathologic examination.

Concurrent CT scans also demonstrated no areas of intracerebral or subarachnoid hemorrhage.

Discussion

Numerous studies have examined the natural history of cerebral AVMs and the frequency of hemorrhage in patients with this diagnosis [1–10, 14, 16, 17, 23]. Unfortunately, these patients make up a very heterogeneous group, with the AVMs varying in size, depth, location, complexity of feeding and draining vessels, presentation, and age of onset. Thus, intracranial hemorrhage has been reported to be the presenting symptom in 20–75% of patients with cerebral AVMs, a very wide range [1–10, 16]. MR demonstrated acute and/or subacute hemorrhage in 45% of our 29 cases, a value near the middle of the range of reported occurrences. The frequency of hemorrhage is less in patients with supratentorial AVMs, in elderly patients, and in smaller-sized malformations [1, 4, 5, 7, 11, 23]. Six (21%) of the 29 AVMs in our study were infratentorial, but the occurrence of hemorrhage in our supra- and infratentorial lesions was similar. Other presenting symptoms occurring less frequently include seizures (18–53%), progressive neurologic deficits (7–21%), headaches, syncope, confusion, or bruits [3–7, 9, 16].

The significance of associated intracranial hemorrhage is underscored by the frequency of rebleeding and of morbidity and mortality figures once a first hemorrhagic episode has occurred. Numerous studies have demonstrated that rebleeding in AVMs occurs in 23–67% of patients with extended follow-up at a rate of approximately 2–3% per year [1, 3, 4, 7, 9, 16, 23]. Six (30%) of the 20 patients who had AVMs that bled had evidence of at least two episodes of hemorrhage. One study showed a 25% rebleed rate within 1 year if the patient had had two prior episodes of hemorrhage [4]. Although the mortality from the initial hemorrhage may be as low as 3–14%, each subsequent hemorrhage has a 6–21% mortality rate [3, 9, 11, 13, 16, 17]. Neurologic handicaps at a 10-year follow-up are present in 27% of patients after a single hemorrhage, but increase by nearly 10% in the event of a rebleed [2–4, 6, 9, 12].

If a patient presents with symptoms and findings other than intracranial hemorrhage, the course is different. Aminoff [11] found that in AVMs without hemorrhage the risk of bleeding is only 1% per year, with a 10-year mortality rate of less than 5%. Other studies [2, 3, 5, 7, 11, 16] report rebleeding in 23–26% of patients who present with hemorrhage, but in only 17–18% of patients presenting with other symptoms, such as epilepsy, neurologic deficits, or bruits. Fults and Kelly [16] reported a 40.5% risk of dying from an intracranial hemorrhage if the initial presentation is an acute hemorrhage, but only an 11.6% risk when epilepsy without hemorrhage is the first manifestation of the AVM. Morbidity figures parallel these findings, showing neurologic deficits to be less common in patients without a hemorrhagic presentation [16]. Thus, the prognosis for patients presenting with unruptured AVMs is significantly better than for those presenting with hemorrhage.

The importance of these figures lies in their applications to patient management. There is considerable controversy in

the literature concerning the proper treatment of patients with AVMs who have had no prior history of bleeding. While some favor a conservative approach, citing operative morbidity and mortality rates of 5–28% and 1–13%, respectively, others point to the psychological effects of the fear of hemorrhage and studies demonstrating a lower frequency of rebleeding and neurologic deficit on long-term follow-up with operative management [4–9, 13, 14, 16, 24]. The postoperative mortality rates of unruptured AVMs are slightly lower than those of ruptured cases (0% vs 2%) [12]. No definite consensus has been reached regarding the optimal treatment of nonhemorrhagic AVMs, with neurologists and neurosurgeons apparently on opposite sides of the issue.

On the other hand, the statistics of subsequent hemorrhage and mortality in those patients who present with hemorrhage or have a prior history of hemorrhage as stated above have led to near unanimous approval of surgical management in this subset of patients. For this reason, the detection of hemorrhage by MR becomes critically important in patient management. This retrospective study was performed to demonstrate the ability of MR to detect clinically occult incidences of prior hemorrhage. The exquisite sensitivity of MR to the paramagnetic effects of hemosiderin have already been demonstrated with its ability to detect hemosiderin-laden occult cerebrovascular malformations [21]. Although the long TR/TE scans are quite sensitive to hemosiderin deposition, GRE sequences, with their added sensitivity to T2* effects, may be useful adjunctive images. Atlas et al. [25] have shown that in 30 of 61 cases of hemorrhagic intracranial lesions GRE images detected more hemorrhagic by-products than spin-echo images. However GRE obscured the diagnosis or failed to depict the lesion in 14 of the 61 and was less specific than spin-echo scans (calcium, ferritin, air, and melanin may produce hypointensity on GRE images that is similar to hemosiderin). The presence of hemosiderin around AVMs has been shown pathologically to correlate with prior episodes of bleeding [22]. In this study we have shown that MR can make a very important contribution to patient management in at least 14% of patients by demonstrating evidence of a prior hemorrhage. Surgical treatment was recommended in four of 29 patients who otherwise might not have been recommended for excisional therapy owing to a negative clinical history of previous hemorrhage. Additionally, the confidence in recommending conservative management in the nine patients with no evidence of hemosiderin was increased. Heros and Tu [12] have shown that a clinical history of earlier hemorrhagic episodes did not correlate with the surgical and pathologic findings in 6% of their patients. We have also demonstrated that in the acute setting a clinical history of acute hemorrhage was not corroborated by MR in six (21%) of 29 cases. Thus, two possibilities exist: the clinical history may be inaccurate in portending hemorrhagic episodes, or MR is not detecting some hemorrhages. In some patients who present clinically with acute headache, MR may miss the rare AVMs that bleed only into the subarachnoid space. These presumably would be detected by CT. However, with high-resolution MR scans currently available, intraparenchymal hemorrhages should not be missed by MR. Therefore, while the dispute over the treatment of nonhemorrhagic AVMs may continue, at least

the classification of patients into the intraparenchymal hemorrhagic or nonhemorrhagic category can be made with greater assurance after MR.

Another valuable contribution that MR may make is in increasing the accuracy of the statistics concerning the natural history of AVMs. Because the majority of investigations into AVMs has relied on CT to detect hemorrhage, and because MR is clearly more sensitive than CT for this purpose [20, 21], the reported frequency of hemorrhage may be revised as more series of patients are examined with MR. The frequency of hemorrhage we encountered (69%) is at the upper end of the reported spectrum. We expect that series with cases demonstrating hemosiderin on MR but without CT evidence of hemorrhage will set a higher range for hemorrhage in these lesions. Assuming that the significance of hemorrhage on MR will be equivalent to that shown on CT, this may lead to more aggressive overall therapy. Since the neurosurgeons are primarily concerned with the issue of hemorrhage versus nonhemorrhage, we believe its detection by MR will be of equal value as when demonstrated by CT.

Demonstrating the presence of hemosiderin deposition on MR images in the face of no clinical evidence of remote hemorrhage in patients with AVMs is valuable information for the decision-making process in these patients. Ensuring that no intraparenchymal hemorrhage has occurred and detecting acute and subacute blood products that may account for presenting symptoms are also primary functions of the MR scan. This study found that MR is more accurate than clinical history in 14% of cases clinically negative for hemorrhage and in 21% of clinically positive cases, reinforcing the vital role MR plays in the management of patients with cerebral AVMs.

REFERENCES

1. Batjer H, Samaan D. Arteriovenous malformations of the posterior fossa: clinical presentation, diagnostic evaluation and surgical treatment. *J Neurosurg* 1986;64:849-856
2. Brown RD Jr, Wiebers DO, Forbes G, et al. The natural history of unruptured intracranial arteriovenous malformations. *J Neurosurg* 1988;68:352-357
3. Crawford PM, West CR, Chadwick OW, Shaw MD. Arteriovenous malformations of the brain: natural history in unoperated patients. *J Neurol Neurosurg Psychiatry* 1986;49:1-10
4. Forster DMC, Steiner L, Hakanson S. Arteriovenous malformations of the brain: a long-term clinical study. *J Neurosurg* 1972;37:562-570
5. Jomin M, Lesoin F, Lozes G. Prognosis for arteriovenous malformations of the brain based on 150 cases. *Surg Neurol* 1985;23:362-366
6. Morgan MK, Johnston I. Intracranial arteriovenous malformations: an 11 year experience. *Med J Austr* 1988;148:65-68
7. Perret G, Nishioka N. Report on the cooperative study of intracranial aneurysms and subarachnoid hemorrhage: arteriovenous malformations. *J Neurosurg* 1966;25:467-490
8. Svien HJ, Olivie I, Angluo-Rivero P. The fate of patients who have cerebral arteriovenous anomalies without definitive surgery. *J Neurosurg* 1956;13:381-387
9. Svien HJ, McCrae JA. Arteriovenous anomalies of the brain: fate of patients not having definitive surgery. *J Neurosurg* 1965;23:23-28
10. Veerapen RJ, Sbeih IA, O'Laoire SA. Surgical treatment of cryptic AVMs and associated hematoma in the brainstem and spinal cord. *J Neurosurg* 1986;66:333-338
11. Aminoff MJ. Treatment of unruptured cerebral arteriovenous malformations. *Neurology* 1987;37:815-819
12. Heros RC, Tu Y-K. Is surgical therapy needed for unruptured arteriovenous malformations? *Neurology* 1987;37:279-286
13. Iansek R, Elstein AS, Balla JL. Application of decision analysis to management of cerebral arteriovenous malformations. *Lancet* 1983;1:1132-1136
14. Luessenhop AJ, Rosa L. Cerebral arteriovenous malformations. *J Neurosurg* 1984;60:14-22
15. Shi Y-Q, Chen X-C. A proposed scheme for grading intracranial arteriovenous malformations. *J Neurosurg* 1986;65:484-489
16. Fults D, Kelly DL Jr. Natural history of arteriovenous malformations of the brain: a clinical study. *Neurosurgery* 1984;15:658-662
17. Graf CJ, Perret GE, Torner JC. Bleeding from cerebral arteriovenous malformations as part of their natural history. *J Neurosurg* 1983;58:331-337
18. Gomori JM, Grossman RI, Bilaniuk LT, Zimmerman RA, Goldberg HI. High-field MR imaging of superficial siderosis of the central nervous system. *J Comput Assist Tomogr* 1985;9:972-975
19. Gomori JM, Grossman RI, Goldberg HI, Hackney DB, Zimmerman RA, Bilaniuk LT. High-field spin-echo MR imaging of superficial and subependymal siderosis secondary to neonatal intraventricular hemorrhage. *Neuroradiology* 1987;29:339-342
20. Gomori JM, Grossman RI, Goldberg HI, Zimmerman RA, Bilaniuk LT. Intracranial hematomas: imaging by high-field MR. *Radiology* 1985;157:87-93
21. Gomori JM, Grossman RI, Goldberg HI, Hackney DB, Zimmerman RA, Bilaniuk LT. Occult cerebral vascular malformations: high-field MR imaging. *Radiology* 1986;158:707-713
22. McCormick WF. The pathology of vascular ("arteriovenous") malformations. *J Neurosurg* 1966;24:807-816
23. Guidetta B, Delitala A. Intracranial arteriovenous malformations. *J Neurosurg* 1980;53:149-152
24. Spetzler RF, Luessenhop AJ, Aminoff MJ. AVM surgery (letters). *Neurology* 1988;38:167-169
25. Atlas SW, Mark AS, Grossman RI, Gomori JM. Intracranial hemorrhage: gradient-echo MR imaging at 1.5 T. *Radiology* 1988;168:803-807