

Generic Contrast Agents

Our portfolio is growing to serve you better. Now you have a *choice*.



FRESENIUS
KABI

[VIEW CATALOG](#)

AJNR

MR demonstration of pituitary hyperplasia and regression after therapy for hypothyroidism.

W W Hutchins, J V Crues, 3rd, P Miya and K W Pojunas

AJNR Am J Neuroradiol 1990, 11 (2) 410

<http://www.ajnr.org/content/11/2/410.citation>

This information is current as
of May 12, 2025.

MR Demonstration of Pituitary Hyperplasia and Regression After Therapy for Hypothyroidism

In many centers, MR has become the imaging study of choice for evaluating diseases of the pituitary [1]. The diagnosis of pituitary adenoma is confirmed by showing a gland that is more than 10 mm in height with or without associated sellar deformity and displacement of the pituitary stalk. We report a case of a hypothyroid patient with elevated levels of serum prolactin and a homogeneously enlarged pituitary gland mimicking a pituitary adenoma on T1-weighted (TR/TE = 600/20) MR images. The pituitary enlargement and hyperprolactinemia resolved after thyroid hormone replacement. To our knowledge, this is the first case for which MR depiction of pituitary hyperplasia and subsequent regression after thyroid replacement therapy has been described.

Case Report

A 29-year-old woman had galactorrhea, amenorrhea, cold intolerance, dry skin, and dry hair after an uncomplicated term pregnancy. The serum level of prolactin was 46.5 $\mu\text{g/l}$ (normal, 0–13.8). MR performed to exclude pituitary adenoma showed diffuse enlargement of the gland, which was 14 mm in height (Fig. 1). A diagnosis of prolactinoma was made, and the patient was referred for a complete endocrine workup. Physical findings included mild enlargement of the thyroid gland, galactorrhea, and visual field defects consistent with a bilateral superior quadrantanopsia. The level of thyroid-stimulating hormone (TSH) was elevated 450 $\mu\text{IU/ml}$; (normal, 0–10), and the level of free serum thyroxine was decreased (0.2 ng/dl; normal, 0.8–2.3), confirming the diagnosis of hypothyroidism. Because of the laboratory evidence of hypothyroidism, pituitary surgery was postponed until the patient had had a trial of replacement of thyroid hormone. After 3 months of treatment with Synthroid (levothyroxine sodium), the level of TSH decreased to 23 $\mu\text{IU/ml}$, and the level of prolactin returned to normal. Repeat MR showed a normal-sized pituitary gland. The patient subsequently began menstruating again and became pregnant a second time.

Discussion

Thyrotropin releasing hormone (TRH) is secreted by the hypothalamus and stimulates secretion of pituitary hormones, especially TSH. Circulating serum thyroxine acts as a negative feedback on the hypothalamic secretion of TRH. In hypothyroidism, the lack of thyroxine feedback leads to elevated levels of TRH, which cause pituitary thyrotroph and lactotroph hypertrophy; increased secretion of TSH and prolactin; and enlargement of the pituitary gland.

Pituitary and sellar enlargement in patients with thyroid disease is well established. Enlargement of sellar volume in patients with hypothyroidism was shown initially on skull series via direct measurements of the bony sella [2, 3]. Furthermore, the size of the sella correlated directly with the level of serum TSH and inversely with the levels of circulating T_3 and T_4 . With the advent of CT, direct visualization of the pituitary gland provided nonsurgical confirmation of pituitary enlargement in hypothyroidism and regression after replacement therapy with thyroid hormone [4–6]. The traditional CT criteria for pituitary macroadenoma include homogeneous enlargement of the gland to a height greater than 10 mm, with or without erosion of the sellar floor and deviation of the stalk. The radiographic findings of pituitary hyperplasia, however, are similar. CT demonstration of a presumed macroadenoma has prompted surgical exploration and discovery of pituitary thyrotroph and lactotroph cell hyperplasia in an otherwise normal pituitary gland [7]. On T1-weighted coronal MR images of the pituitary, microadenomas usually appear as areas of low signal intensity [8], whereas macroadenomas are isointense with the adjacent normal gland, though they may contain low-intensity

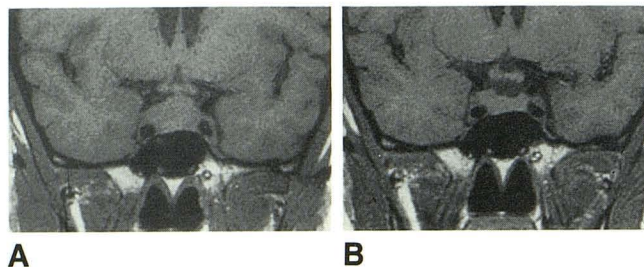


Fig. 1.—**A**, T1-weighted (600/20) coronal MR image shows diffusely enlarged pituitary gland consistent with macroadenoma or hyperplasia. **B**, T1-weighted MR image at same level as **A** obtained after 3 months of thyroid hormone replacement shows normal-sized pituitary gland. Note that right side of gland is larger than left side. This is thought to represent asymmetric regression of a hyperplastic gland.

necrotic areas [9]. Therefore, the radiographic findings of macroadenoma overlap those of a diffusely enlarged gland seen in pituitary hypertrophy on both CT and MR.

Despite the initial diagnosis of prolactin-secreting adenoma in our case, a complete endocrine workup and clinical history established the diagnosis of hypothyroidism. Thyroid replacement therapy and follow-up demonstration of regression prevented unnecessary surgery or medical therapy. Increased use of MR in the evaluation of patients who have amenorrhea, galactorrhea, and hyperprolactinemia may increase the detection of pituitary hypertrophy. In the appropriate clinical setting, however, it is prudent to recognize that pituitary enlargement may be the product of gland hypertrophy caused by excessive hormonal stimulation.

William W. Hutchins
Pueblo Radiology Medical Group
Santa Barbara, CA 93105
John V. Cruess III
Pamela Miya
Kathleen W. Pojunas
Santa Barbara Cottage Hospital
Santa Barbara, CA 93105

ACKNOWLEDGMENT

We thank the Cottage Hospital Research Project for support of this work.

REFERENCES

1. Peck WW, Dillon WP, Norman D, Newton TH, Wilson CB. High-resolution MR imaging of microadenomas at 1.5 T: experience with Cushing disease. *AJNR* 1988;9:1085–1091
2. Taveras JM, Wood EH. *Diagnostic neuroradiology*. Baltimore: Williams & Wilkins, 1964:1.103
3. Yamada T, Tsukui T, Ikejiri K, et al. Volume of sella turcica in normal subjects and in patients with primary hypothyroidism and hyperthyroidism. *J Clin Endocrinol Metab* 1976;42:817–822
4. Okuno T, Sudo J, Momoi T. Pituitary hyperplasia due to hypothyroidism. *J Comput Assist Tomogr* 1980;4(5):600–602
5. Pita J Jr, Shafey S, Pina R. Diminution of large pituitary tumor after replacement therapy for primary hypothyroidism. *Neurology* 1979;29:1169–1172
6. Guerrero LA, Carnovale R. Regression of pituitary tumor after thyroid replacement in primary hypothyroidism. *South Med J* 1983;76:529–531
7. Pioro EP, Scheithauer B, Laws ER, et al. Combined thyrotroph and lactotroph cell hyperplasia simulating prolactin secreting pituitary adenoma in long standing primary hypothyroidism. *Surg Neurol* 1988;29:218–226
8. Pojunas KW, Daniels DL, Williams AL, et al. MRI imaging of prolactin-secreting microadenomas. *AJNR* 1986;7(2):209–213
9. Kucharczyk W, Davis DO, Kelly WM, et al. Pituitary adenomas: high-resolution MR imaging at 1.5 T. *Radiology* 1986;161:761–765