

Generic Contrast Agents

Our portfolio is growing to serve you better. Now you have a *choice*.



FRESENIUS
KABI

[VIEW CATALOG](#)

AJNR

Balloon embolization of a basilar bifurcation aneurysm.

G Guglielmi

AJNR Am J Neuroradiol 1990, 11 (4) 653-655

<http://www.ajnr.org/content/11/4/653.citation>

This information is current as
of May 17, 2025.

Balloon Embolization of a Basilar Bifurcation Aneurysm

Guido Guglielmi^{1,2}

With interventional neuroangiography it is possible to treat medium-sized (diameter ranging from 6 to 15 mm) saccular aneurysms while preserving the parent vessel. In this procedure a balloon is introduced, inflated, and detached into the aneurysm, occluding the sac and the neck [1-5]. Endovascular treatment of inoperable large and giant aneurysms, may require, if tolerated, the permanent balloon occlusion of the parent artery [6-9]. A patient with a medium-sized basilar bifurcation aneurysm presented with symptoms referable to subarachnoid hemorrhage and vasospasm. Therapeutic embolization of the aneurysm was successfully performed with a detachable silicone balloon.

Case Report

A 61-year-old man was admitted for abrupt loss of consciousness associated with neck stiffness. He displayed mental confusion with drowsiness and psychomotor agitation. A physical examination revealed neck stiffness, severe left hemiparesis, and left third cranial nerve impairment. Lumbar puncture yielded bloody CSF. A plain CT scan showed the presence of blood in the basal cisterns and a small rounded hyperdense mass located at the level of the interpeduncular cistern. A four-vessel cerebral angiogram showed a medium-sized (8 × 8 × 9 mm) basilar bifurcation aneurysm and vasospasm affecting the posterior cerebral arteries and the superior cerebellar arteries (Fig. 1). A base view indicated that the posterior cerebral arteries and superior cerebellar arteries did not originate from the aneurysm (Fig. 2).

Via a transfemoral approach, an 8-French catheter was introduced into the left vertebral artery. Through this, a Hieshima balloon (DSB-1.8-L) (Interventional Therapeutics, S. San Francisco) mounted on a Tracker catheter (Target Therapeutics, San Jose, CA) was introduced into the aneurysm. The balloon was then filled with hydrosoluble nonionic hypertonic contrast medium (Omnipaque, Shering, W. Germany) (two-thirds contrast medium and one-third physiologic saline solution), the aneurysm was occluded, and the balloon was detached by gentle traction. After detachment, angiography showed exclusion of the aneurysm from the circulation and the patency of the entire vertebrobasilar system, except for the left posterior cerebral artery (Fig. 3).

The patient's state of consciousness deteriorated in the days following the embolization, because of a posthemorrhagic hyperten-

sive hydrocephalus. A ventriculoperitoneal shunt was placed 1 week after the embolization, with a resulting progressive improvement in his state of consciousness. A four-vessel angiogram obtained 25 days after the embolization confirmed occlusion of the aneurysm. The left posterior cerebral artery filled via the left carotid artery (Fig. 4). A neurologic examination performed at this time showed persistence of mild mental deterioration, with amelioration of the left motor deficit and of the third cranial nerve involvement. Subsequently, plain skull radiographs were obtained every 15 days for 9 months and showed no change in balloon size (Fig. 5). After 9 months, the neurologic examination revealed complete resolution of both the left hemiparesis and the third cranial nerve palsy.

Discussion

Aneurysms of the posterior circulation account for 15% of all intracranial aneurysms. Basilar bifurcation aneurysms are the most common ones (51%) of the posterior circulation.

In terms of surgical outcome in small, medium-sized, and large basilar bifurcation aneurysms, Peerless and Drake [10], in a series of 450 patients, reported excellent results in 69% of patients, good results in 15%, poor results in 12%, and death in 4%, while Yasargil [11] reported a 26% rate of morbidity and mortality in a series of 47 similar cases (in eight of these cases, clipping was found impossible at surgery). Peerless and Drake [10] stated that the majority of the unsatisfactory surgical results occurred with aneurysms of the terminal basilar artery, a cogent reminder of the vital importance to normal brain function of the perforating vessels from the P1 segment.

As an alternative to classic surgery, Romodanov and Shcheglov [4] reported their experience on endovascular balloon embolization of 93 anterior circulation aneurysms with preservation of the parent artery. In 1986 Higashida et al. [3] reported a similar experience with 25 cases of anterior and posterior circulation aneurysms. In both series a solidifying substance was used to fill the balloon before the detachment.

Endovascular balloon embolization of medium-sized intracranial saccular aneurysms is an attractive treatment method in cases in which surgical approach is difficult. Some may

Received June 5, 1989; revision requested July 26, 1989; revision received October 2, 1989; accepted October 4, 1989.

This work was supported by a grant from the Ministero della Pubblica Istruzione (1983-2-12-1).

¹ Servizio di Neuroangiografia Terapeutica, Dipartimento di Scienze Neurologiche, Università di Roma, Rome, Italy 00185.

² Present address: Department of Radiological Sciences, UCLA Medical Center, 10833 Le Conte Ave., Los Angeles, CA 90024. Address reprint requests to G. Guglielmi.

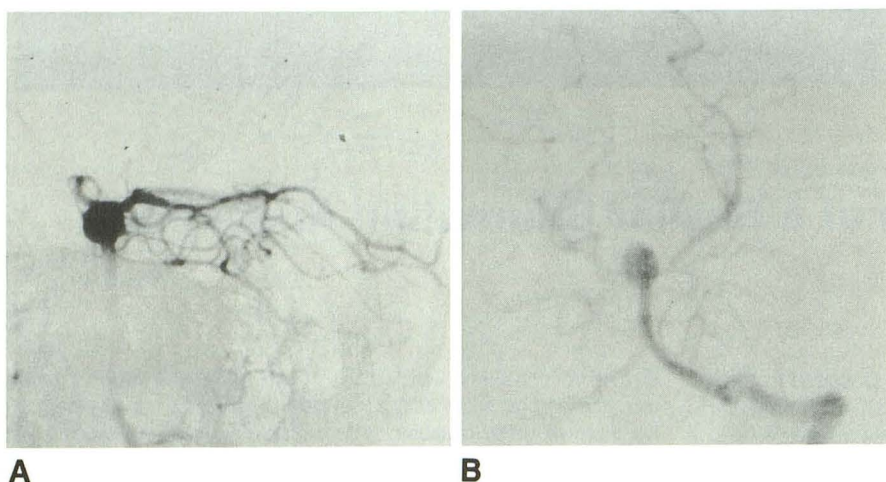


Fig. 1.—A and B, Vertebral angiograms show a medium-sized basilar bifurcation aneurysm, lateral view (A) and Towne's projection (B).

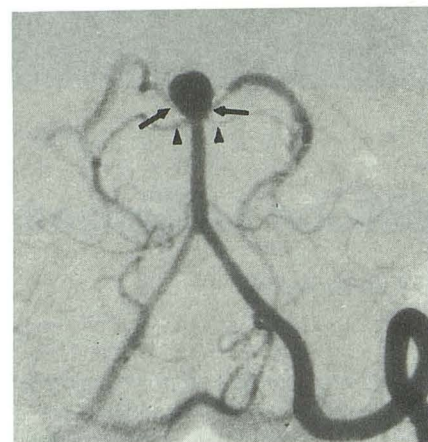


Fig. 2.—Vertebral angiogram (base view) shows that neither the posterior cerebral arteries (arrows) nor the superior cerebellar arteries (arrowheads) are coming out of the side of the aneurysmal sac.

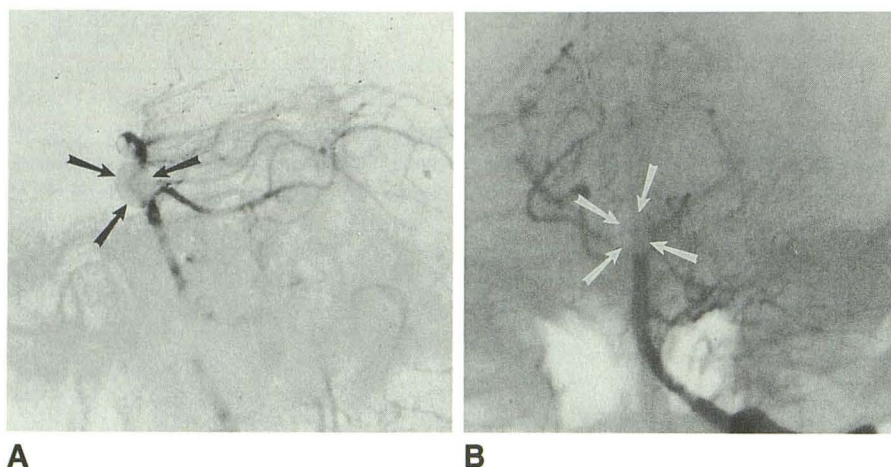


Fig. 3.—A and B, Postembolization angiograms, lateral view (A) and Towne's projection (B). The aneurysm is completely occluded by the balloon (arrows). The left posterior cerebral artery is not injected.

argue that the inflation of a balloon into an aneurysm carries some risk of aneurysm rupture due to possible overdistension or deformation of portions of the sac—moreover, if an aneurysm ruptures during a surgical intervention, the surgeon is able to manage this occurrence while nothing can be done if an aneurysm breaks during a balloon embolization. However, Romodanov and Shcheglov [4] report only one case of aneurysm rupture in 93 embolized cases while Higashida et al. [3] had no aneurysm rupture in 25 embolized cases. The same authors report two cases of balloon rupture with consequent leakage of solidifying substance in which both patients died. Early detachment of the balloon led to neurologic complications in two other cases.

The main technical difference between the cases reported above and the present case is that the balloon was filled with contrast medium rather than a solidifying substance. This technique was used because the aneurysmal volume was 0.4

cm³ while the dead space of the Tracker catheter is 0.35 cm³, and it was not possible to use a vent tube to exchange the contrast medium with any solidifying substance. Nevertheless, the control angiogram at 9 months showed that the balloon was still inflated, although it was assumed that a balloon filled with contrast medium would tend to deflate in a few weeks. It is a common experience, for instance, that latex balloons used in the treatment of posttraumatic carotid-cavernous fistulas deflate within a few weeks. The reason that our balloon did not collapse after 9 months may be that most of the blood filling the aneurysm was expelled while the balloon was being inflated within the aneurysm. We believe that, at the end of the procedure, most of the wall of the balloon was surrounded by a thin layer of blood, which lay between the balloon itself and the inner aneurysmal wall. After the detachment of the balloon into the aneurysmal sac, this became a watertight compartment. The hydrostatic pressure

Fig. 4.—25 days after embolization left carotid angiogram shows that the left posterior cerebral artery is filled by the carotid system.

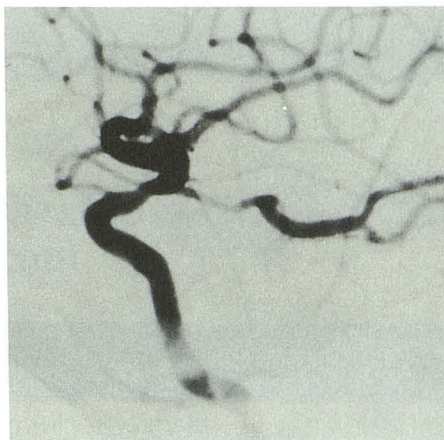

Fig. 5.—Standard radiograph taken 9 months after embolization. The balloon (arrows) is the same size as in the immediate postembolization radiographs.



within the balloon, the colloidal-osmotic pressure in the plasma located between the balloon and the inner aneurysmal wall, and the hydrostatic pressure of the blood located between the balloon and the inner aneurysmal wall rapidly reached equilibrium, causing the balloon to remain inflated. The superficial tension of the balloon, owing to the distension of its wall, is reduced to values that are compatible with the stable deformation of the balloon. In carotid-cavernous fistulas, the balloons deflate because they do not lie in a watertight compartment, but rather are in the cavernous sinus.

Three factors explain why the balloon did not deflate through its own neck: (1) the wall of the neck of the balloon was thicker and therefore less permeable to fluid; (2) the balloon was filled with hypertonic contrast medium and therefore fluid might enter the balloon in the first 5–6 weeks; after this period even the balloons filled with hypertonic contrast medium begin to deflate [12]; and (3) in less than 1 month after embolization, the neck of the balloon was probably covered entirely by endothelium, since it is well known that endothelial cells are capable of covering foreign material in the bloodstream within that time. This phenomenon is mediated by platelet aggregation and fibrous tissue growth [13, 14]. In the present case, neoendothelium and its underlying fibrous tissue eventually rendered even more unlikely the fluid exchange between the neck of the balloon and the bloodstream.

ACKNOWLEDGMENTS

I owe many thanks to F. Felici, III, Chair of Human Physiology, University of Rome "La Sapienza" and to M. Feliciani, Service of Neuroradiology II, University of Rome "La Sapienza" for their useful suggestions.

REFERENCES

1. Campos JC, Antunes JL. Intra-saccular balloon embolization of a giant basilar tip aneurysm. In: *Proceedings of the twenty-sixth annual meeting of American Society of Neuroradiology*. Chicago, May 15–20, 1988:131
2. Hieshima GB, Higashida RT, Wapensky J, et al. Balloon embolization of a large distal basilar artery aneurysm. Case report. *J Neurosurg* 1986;65:413–416
3. Higashida RT, Hieshima GB, Halbach VV, et al. Intravascular detachable balloon embolization of intracranial aneurysms. Indications and techniques. *Acta Radiol Suppl* (Stockh) 1986;369:594–596
4. Romodanov AP, Shcheglov VI. Intravascular occlusion of saccular aneurysms of the cerebral arteries by means of a detachable balloon catheter. In: Kravynbühl H, ed. *Advances and technical standards in neurosurgery*, vol. 9. New York: Springer-Verlag, 1982:25–49
5. Serbinenko FA. Balloon catheterization and occlusion of major cerebral vessels. *J Neurosurg* 1974;41:125–145
6. Berenstein A, Ransohoff J, Kupersmith M, et al. Transvascular treatment of giant aneurysms of the cavernous carotid and vertebral arteries. Functional investigation and embolization. *Surg Neurol* 1984;21:3–12
7. Fox AJ, Viñuela F, Pelz DM, et al. Use of detachable balloons for proximal artery occlusion in the treatment of unclippable cerebral aneurysms. *J Neurosurg* 1987;66:40–46
8. Guglielmi G. Balloon embolization of a giant vertebral-basilar aneurysm. Case report. *AJNR* 1989;10(Suppl):S28–S29
9. Guglielmi G, Guidetti G, Feliciani M, et al. Management and therapeutic embolization of giant intracranial aneurysms: experience with 25 cases. In: *Proceedings of the first European congress of neurology*. Prague, April 18–22, 1988:482–483
10. Peerless SJ, Drake CG. Posterior circulation aneurysms. In: Wilkins RH, Rengachary SS, eds. *Neurosurgery*. New York: McGraw-Hill, 1985:1422–1437
11. Yasargil MG. Clinical considerations, surgery of intracranial aneurysms and results. In: *Microneurosurgery*, vol. 2. Stuttgart: Thieme, 1984:232–256
12. Hieshima GB, Grinnell VS, Mehringer CM. A detachable balloon for therapeutic transcatheter occlusions. *Radiology* 1981;130:227–228
13. Debrun GM, Varsos V, Liszczak TM, et al. Obliteration of experimental aneurysms in dogs with isobutyl-cyanoacrylate. *J Neurosurg* 1984;61:37–43
14. Zanetti PH, Sherman FE. Experimental evaluation of a tissue adhesive as an agent for the treatment of aneurysms and arteriovenous anomalies. *J Neurosurg* 1972;36:72–79