

Generic Contrast Agents

Our portfolio is growing to serve you better. Now you have a *choice*.



FRESENIUS
KABI

[VIEW CATALOG](#)

AJNR

Symptomatic external laryngocele in a newborn: findings on plain radiographs and CT scans.

C A Lewis, M Castillo, E Patrick and R Sybers

AJNR Am J Neuroradiol 1990, 11 (5) 1002

<http://www.ajnr.org/content/11/5/1002.citation>

This information is current as
of May 15, 2025.

Symptomatic External Laryngocele in a Newborn: Findings on Plain Radiographs and CT Scans

Laryngocele causing stridor and respiratory distress in infants is extremely rare. Less than 10 cases have been described in the world literature [1]. A case of a symptomatic laryngocele occurring in a 2-day-old infant is presented.

Case Report

A 2-day-old boy had a soft-tissue mass in the left side of the neck. Three days after its discovery, stridor and respiratory distress developed, and it was noted that the size of the mass had increased. Soft-tissue views of the neck showed a cystlike structure that contained an air-fluid level and extended anteriorly and laterally to the trachea (Fig. 1). A barium esophagram showed that the mass did not communicate with the esophagus. A contrast-enhanced CT scan showed a single cystic cavity with an air-fluid level in the left side of the neck displacing the trachea to the right. The mass extended superiorly to the level of the uvula and inferiorly to the left sternoclavicular joint. On CT, no definite communication between the cystic mass and the larynx or pharynx was seen.

At surgery, a smooth-walled mass with a minute stalk between the mass and the larynx was excised. Histopathologic examination showed a cystic structure lined by respiratory and disrupted squamous epithelium, with evidence of chronic and acute inflammation. These findings confirmed the diagnosis of external laryngocele.

Discussion

Laryngoceles are abnormal dilatations of the appendix of the laryngeal ventricle and are classified as internal, mixed, or external [2]. An internal laryngocele is confined to the interior of the larynx. An external laryngocele protrudes through the thyrohyoid membrane, at the point where the superior laryngeal nerve and vessels enter the larynx. A mixed laryngocele contains components of both the internal and external types and has a short segment connecting the two components [2].

Laryngoceles are more common in adults and are seen more frequently in Caucasian males [3]. In one report [3] of 131 cases, mixed laryngoceles were the most common type (44%), and external laryngoceles were the least common (26%). In addition to soft-tissue masses in the neck, infants with laryngoceles may have signs and symptoms of respiratory obstruction and difficulty feeding. Use caution during clinical evaluation, as compression of the mass can increase the internal component of a mixed laryngocele and may lead to abrupt obstruction of an already compromised airway [2].

On radiographs, anteroposterior and lateral soft-tissue views of the neck are often diagnostic and should be obtained first. Typical findings on these views of an external or mixed laryngocele include a sharply defined round or oval radiolucency within the soft tissues lateral to the hyoid bone and thyroid cartilage [4]. Internal laryngoceles are not well visualized on frontal radiographs because the air-filled

sac may project over the cervical spine [2]. Lateral radiographs may show the air-filled sac anterior and superior to the larynx. The laryngocele also can extend from the ventricle to the hyoid bone. Barium studies of the esophagus can help differentiate a laryngocele from a lateral pharyngeal diverticulum. The latter often fills with barium during the study, but a laryngocele does not [5]. CT findings include a smooth air-filled structure with well-defined borders that can contain a fluid level. On CT, internal laryngoceles can be recognized in the paralaryngeal space, extending from the level of the false cord and laryngeal ventricle to the thyrohyoid membrane. A mixed laryngocele can be seen extending through the thyrohyoid membrane into the adjacent lateral soft tissues of the neck [6]. The attenuation of laryngoceles can vary from air to fluid or soft-tissue values, depending on the contents [6]. If it can be established that a communication exists between the air sac and the airway at the level of the laryngeal ventricle, the definitive diagnosis of laryngocele can be made on the basis of CT findings [6].

The radiologic differential diagnosis includes (1) branchial cleft cyst (typically located medially to the sternocleidomastoid muscle), (2) cystic hygroma/cavernous lymphangioma (usually occurring posteriorly to the sternocleidomastoid muscle), and, less likely, (3) an aberrant thyroglossal duct cyst (generally manifested later in life) [7].

Curtis A. Lewis

Mauricio Castillo

Ellen Patrick

Robert Sybers

Emory University Hospital
Atlanta, GA 30322

REFERENCES

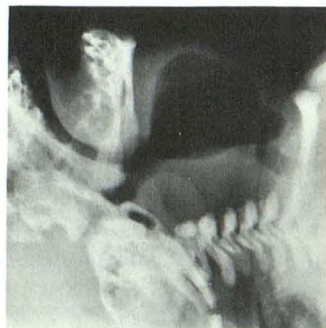
1. Walpita PR. Laryngocele in an infant. *J Pediatr Surg* 1975;10(5):843-844
2. Giovanniello J, Grieco RV, Bartone NF. Laryngocele. *AJR* 1970;108:825-829
3. Canalis RF, Maxwell DS, Hemenway WG. Laryngocele: updated review. *J Otolaryngol* 1977;6:191-199
4. Baker HL, Baker SR, McClatchey KD. Manifestations and management of laryngoceles. *Head Neck Surg* 1982;4:450-456
5. Kattan KR, Zaheer MA. Laryngocele. *JAMA* 1980;244:1617-1619
6. Glazer HS, Mauro MA, Aronberg DJ, Lee JK, Johnson DE, Sagel SS. Computed tomography of laryngoceles. *AJR* 1983;140:549-552
7. Silverman PM, Korobkin M, Moore AV. Computed tomography of cystic neck masses. *J Comput Assist Tomogr* 1983;7(3):498-502

Fig. 1.—Symptomatic external laryngocele in a newborn.

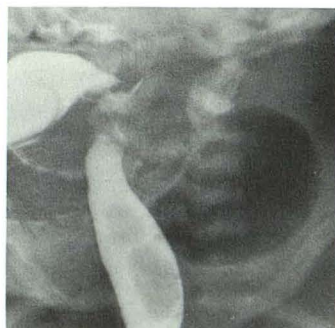A, Lateral radiograph of neck in supine patient shows an air-containing cystlike structure in anterior soft tissues. Apparent increased precervical soft tissues are due to fluid within dependent part of laryngocele.

B, Oblique barium esophagram shows large air-filled mass in left side of neck. No barium entered the lesion.

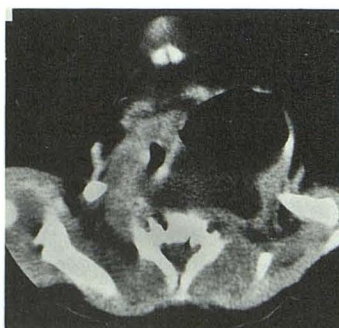C, Contrast-enhanced CT scan of neck shows laryngocele extending posteriorly and displacing trachea to right. Note fluid layering in dependent part of laryngocele. No definite communication between mass and airway is seen. Note that lesion is deep to sternocleidomastoid muscle and that differentiating it from a branchial cleft cyst communicating with the pharynx may not be radiologically possible.



A



B



C