

Generic Contrast Agents

Our portfolio is growing to serve you better. Now you have a *choice*.



[VIEW CATALOG](#)

AJNR

Small-cell carcinoma of the prostate: metastases to the brain as shown by CT and MR with pathologic correlation.

R M Freedy and K D Miller, Jr

AJNR Am J Neuroradiol 1990, 11 (5) 947-948
<http://www.ajnr.org/content/11/5/947.citation>

This information is current as
of May 13, 2025.

Small-Cell Carcinoma of the Prostate: Metastases to the Brain as Shown by CT and MR with Pathologic Correlation

Small-cell carcinoma of the prostate is a rare clinicopathologic entity that has a nearly 100% mortality rate when distal metastases are present. Sites of metastatic disease have included the lymphatic system, lungs, liver, and soft tissues. No report of metastases to the brain has been published before.

Case Report

A 63-year-old man with a history of hypertension and non-insulin-dependent diabetes mellitus had had fever, night sweats, and vertigo for 2 months. Digital rectal examination revealed a firm prostate containing a small, hard, centrally located nodule. No other abnormalities were detected on physical examination. Laboratory studies showed an elevated erythrocyte sedimentation rate, increased levels of C-reactive protein and lactic dehydrogenase, and decreased levels of serum albumin. Further workup included a gallium scan, flexible sigmoidoscopy, abdominal CT and MR imaging, and CT and MR of the liver. None of these examinations showed any pathologic changes. A ^{99m}Tc -labeled methylene diphosphonate bone scan showed abnormal uptake of the nucleotide in several areas, including the calvaria; multiple levels of the cervical, thoracic, and lumbar spine; pelvis; ribs; left femoral neck; midshaft of the right femur; sternum; and right shoulder, all consistent with diffuse osseous metastatic disease. Bone marrow obtained from the left superior iliac crest contained tumor cells of metastatic adenocarcinoma, and the histologic findings were consistent with those of a primary tumor of the prostate. Tumor cells in the bone marrow were positive for prostate-specific antigen by the immunoperoxidase technique. Follow-up needle biopsy of the prostate showed class 5 cells, and follow-up laboratory blood analysis showed markedly increased serum levels

of prostatic acid phosphatase and prostate-specific antigen. The patient was placed on Southwestern Oncology Group Protocol 8494 chemotherapy, including flutamide and leuprolide, and analgesics and was discharged from the hospital.

At first, the patient did well; however, 6 weeks after discharge, he began to have generalized weakness, bursts of inappropriate language, and jerky movements of the right arm and lower extremity. Contrast-enhanced CT of the head showed an enhancing, round, nodular lesion with surrounding low-density edema deep in the left hemisphere in a periventricular location, consistent with metastatic disease or a primary intracranial neoplasm (Fig. 1A). Follow-up cranial MR showed a lesion in the left frontal lobe (Figs. 1B–1D), findings consistent with primary or metastatic neoplasm. Abdominal sonography showed hepatomegaly with diffuse metastases scattered throughout both lobes of the liver, including the caudate lobe. Chemotherapy and general palliative measures were continued; however, the patient deteriorated clinically and died 7 days after admission.

Final anatomic diagnoses at autopsy were (1) anaplastic small-cell carcinoma of prostate arising in the right lateral lobe with extension to the right inguinal, paraaortic, peripancreatic, and hilar lymph nodes and (2) metastatic carcinoma to the liver, spleen, lungs, adrenal glands, right psoas muscle, nerves at the greater sciatic foramen, multiple bones, and the left cerebrum.

Discussion

Primary small-cell carcinoma of the prostate is extremely uncommon; fewer than 40 cases have been reported in the current literature [1–8]. Additionally, paraneoplastic syndromes associated with this type of prostatic carcinoma have been described [2, 3].

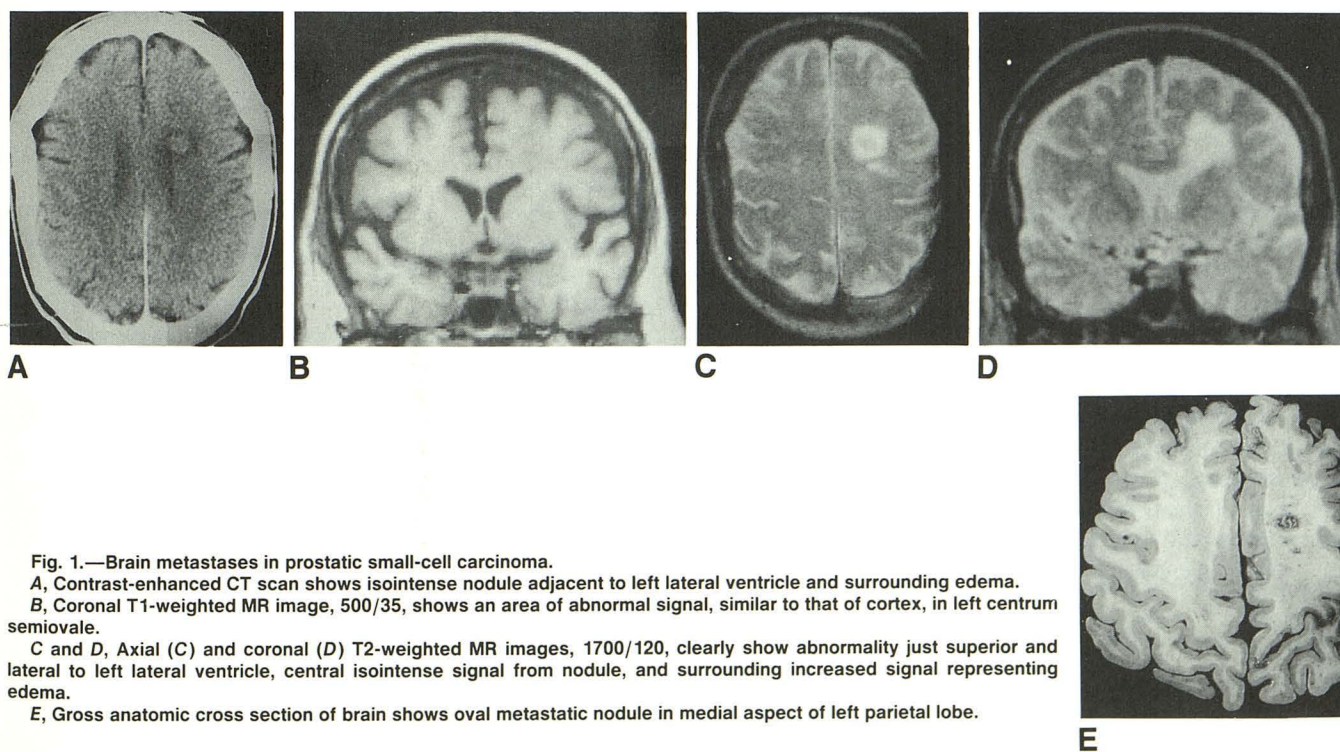


Fig. 1.—Brain metastases in prostatic small-cell carcinoma.

A, Contrast-enhanced CT scan shows isointense nodule adjacent to left lateral ventricle and surrounding edema.
B, Coronal T1-weighted MR image, 500/35, shows an area of abnormal signal, similar to that of cortex, in left centrum semiovale.
C and D, Axial (C) and coronal (D) T2-weighted MR images, 1700/120, clearly show abnormality just superior and lateral to left lateral ventricle, central isointense signal from nodule, and surrounding increased signal representing edema.

E, Gross anatomic cross section of brain shows oval metastatic nodule in medial aspect of left parietal lobe.

Extrapulmonary small-cell carcinomas occur in a wide variety of anatomic locations and have a propensity for metastatic disease, as does the pulmonary form. Locations previously reported for extrapulmonary small-cell carcinomas include esophagus, stomach, pancreas, larynx, small and large bowel, urinary bladder, and prostate. Histologically, small-cell carcinomas are classified as pure or combined; the latter signifies areas of squamous and/or glandular differentiation in the primary origin [4].

In our case, at autopsy, the right lobe of the prostate was involved with adenocarcinoma, which had a subtle transition to a small-cell type in the lateral aspect of the lobe. Microscopic evaluation of the lungs showed multiple small nodules indiscriminately distributed within the lung parenchyma and visceral pleural surface; all were nodules of the metastatic small-cell type. Cut sections of the brain revealed a metastatic nodule in the left cerebrum of the small-cell type with surrounding edema (Fig. 1E). No other CNS metastases were found at autopsy. All other visceral metastatic lesions were of the small-cell type.

The results at autopsy correlated well with the CT and MR findings. Contrast-enhanced CT showed a poorly enhancing, round, nodular shadow with a surrounding low-density area consistent with edema in the periventricular region of the left hemisphere. Etiologic considerations based on the CT findings included primary CNS tumor, metastatic disease, or a granulomatous focus. Follow-up T1-weighted MR images showed the lesion in the left cerebrum as nearly isointense with the cortex in this area. T2-weighted images showed central isointensity with surrounding increased signal of CSF density, reflecting surrounding edema. When the MR findings were compared and correlated with the CT findings, the most likely etiologic considerations were primary or metastatic neoplasm. Gadopentetate dimeglumine was not commercially available as a contrast agent at the time of the MR.

Although the CT and MR demonstration of metastases to the brain is not unusual, the histopathologic correlation is noteworthy. Given the aggressiveness of small-cell tumors historically, and their propen-

sity to develop widespread metastases, including brain metastases, small-cell prostatic carcinoma would be expected to behave in a similar manner. Such a presumption now has a factual basis (i.e., this case report). This knowledge is important because staging workups for biopsy-proved, disseminated prostatic carcinoma must include CT or MR studies to detect possible intracranial metastatic lesions. The results of either radiologic study might have a significant impact on treatment.

R. Marvin Freedy
Kenneth D. Miller, Jr.
Ochsner Medical Institutions
New Orleans, LA 70121

REFERENCES

1. Manson AL, Terhurne D, MacDonald G. Small cell carcinoma of prostate. *Urology* **1989**;33(1):78-79
2. Tetu B, Ro JY, Ayala AG, Ordonez NG, Logothetis CJ, von Eschenbach AC. Small cell carcinoma of the prostate associated with myasthenic (Eaton-Lambert) syndrome. *Urology* **1989**;33(2):148-152
3. Ghandur-Mnaymneh L, Satterfield S, Block NL. Small cell carcinoma of the prostate with inappropriate antidiuretic hormone secretion: morphological, immunohistochemical and clinical expressions. *J Urology* **1986**;135:1263-1266
4. Ibrahim NBN, Briggs JC, Corbishley CM. Extrapulmonary oat cell carcinoma. *Cancer* **1984**;54:1645-1661
5. Turbat-Herrera EA, Herrera GA, Gore I, Lott RL, Grizzle WE, Bonnin JM. Neuroendocrine differentiation in prostatic carcinomas. *Arch Pathol Lab Med* **1988**;112:1100-1105
6. Tetu B, Ro JY, Ayala AG, Johnson DE, Logothetis CJ, Ordonez NG. Small cell carcinoma of the prostate. Part 1. A clinicopathologic study of 20 cases. *Cancer* **1987**;59:1803-1809
7. Ro JY, Tetu B, Ayala AG, Ordonez NG. Small cell carcinoma of the prostate. Part 2. Immunohistochemical and electron microscopic studies of 18 cases. *Cancer* **1987**;59:977-982
8. Bleichner JC, Chun B, Klappenbach S. Pure small cell carcinoma of the prostate with fatal liver metastasis. *Arch Pathol Lab Med* **1986**;110:1041-1044