

Generic Contrast Agents

Our portfolio is growing to serve you better. Now you have a *choice*.



FRESENIUS
KABI

[VIEW CATALOG](#)

AJNR

Multicenter study of gadopentetate dimeglumine as an MR contrast agent: evaluation in patients with spinal tumors.

G Sze, G K Stimac, C Bartlett, W P Dillon, V M Haughton, W Orrison, F Kashanian and H Goldstein

This information is current as of May 15, 2025.

AJNR Am J Neuroradiol 1990, 11 (5) 967-974
<http://www.ajnr.org/content/11/5/967>

Multicenter Study of Gadopentetate Dimeglumine as an MR Contrast Agent: Evaluation in Patients with Spinal Tumors

Gordon Sze¹
 Gary K. Stimac²
 Christopher Bartlett³
 William P. Dillon⁴
 Victor M. Haughton⁵
 William Orrison⁶
 Franciska Kashanian⁷
 Harold Goldstein⁷

Received September 11, 1989; revision requested October 31, 1989; revision received May 11, 1990; accepted May 15, 1990.

This work was supported by a grant from Berlex Laboratories, Inc., Wayne, NJ.

¹ Department of Medical Imaging, Memorial Sloan-Kettering Cancer Center, New York, NY 10021. Present address: Department of Diagnostic Radiology, Yale University School of Medicine, 333 Cedar St., P.O. Box 3333, New Haven, CT 06510. Address reprint requests to G. Sze.

² Department of Radiology, University Hospital, University of Washington, Seattle, WA 98195, and First Hill Diagnostic Imaging Center, Seattle, WA 98104. Present address: 6849 51st Ave. N.E., Seattle, WA 98115.

³ Department of Radiology, Army Medical Corps Cancer Research Center, Lakewood, CO 80214. Present address: Department of Radiology, Memorial Hospital, 1400 E. Boulder St., Colorado Springs, CO 80909.

⁴ Department of Radiology, University of California, San Francisco, CA 94143.

⁵ Department of Radiology, Medical College of Wisconsin, Froedtert Memorial Lutheran Hospital, Milwaukee, WI 53226.

⁶ University of New Mexico/Los Alamos Center for Non-Invasive Diagnosis, and Department of Radiology, University of New Mexico School of Medicine, Albuquerque, NM 87131.

⁷ Berlex Laboratories, Inc., Wayne, NJ 07470.

0195-6108/90/1105-0967

© American Society of Neuroradiology

In an open-label, multicenter study, the efficacy and safety of gadopentetate dimeglumine (0.1 mmol/kg) administered IV as an MR imaging contrast agent were evaluated in 113 patients with symptoms of spinal tumors. The examinations were performed with a variety of imagers at different field strengths. Scans with short and long TRs were obtained in all patients before and after IV administration of the contrast medium. Contrast enhancement was seen in 77% of patients. No enhancement was seen in 23%, but this absence was useful diagnostic information in all cases. In 66% of the cases, additional information regarding location, size, configuration, and/or characterization of the lesion was obtained from postcontrast scans. The investigators made a change from referral diagnosis to postinjection diagnosis in 30% of the cases. Postinjection images provided additional information in 96% (43/45) of intradural extramedullary and intramedullary tumors; it also provided additional information in 20 (53%) of 38 cases of extradural tumor. Gadopentetate dimeglumine demonstrated a high level of safety and tolerance, as evidenced by the lack of clinically significant trends toward abnormal changes from baseline evaluations for physical and neurologic examinations, vital signs, and hematologic and blood chemistry parameters and by the low prevalence and mild nature of adverse reactions.

Gadopentetate dimeglumine was found to be efficacious in the evaluation of suspected spinal tumors. High levels of safety and tolerance were demonstrated.

AJNR 11:967-974, September/October 1990

Recently, several articles have appeared that have discussed the utility of gadopentetate dimeglumine (formerly known as gadolinium-DTPA) in the MR evaluation of spinal disease [1-11]. All of these articles have focused either on one anatomic region of the spine or on one clinical entity. In the extradural space, it has been suggested that contrast enhancement may not be necessary for routine clinical use but may be beneficial when a specific question is posed, such as differentiating disk from scar (epidural fibrosis) or disk from tumor [3-5, 8]. In the intradural extramedullary space, contrast enhancement has been found to be effective for the delineation of both primary and secondary tumors [2, 4, 6, 8-10]. Finally, in the intramedullary space, contrast enhancement has been demonstrated to be useful in the evaluation of suspected cord tumors [1, 6, 7, 9-11]. We present the results of an open-label, multicenter study designed to evaluate the efficacy and safety of 0.1 mmol/kg of gadopentetate dimeglumine administered IV in patients with suspected spinal tumors who were undergoing MR imaging.

Subjects and Methods

The overall study population originated in six centers and consisted of 113 patients with symptoms suggestive of spinal tumors. Valid data for safety analysis were available in all 113 patients and valid data for efficacy evaluation were available in 111 patients; two patients were excluded from efficacy evaluation owing to variations from the study protocol (e.g.,

preinjection scans obtained 22 days prior to injection or coronal views substituted for sagittal views). The inclusion and exclusion criteria for entering patients into this study are listed in Table 1. The 113 patients included 54 women and 59 men 19–82 years old.

The study drug, gadopentetate dimeglumine, was provided to the investigators by the sponsor as a sterile, clear, colorless to slightly yellow, aqueous solution in one 20-ml vial in a concentration of 0.5 mol/l. One numbered medication package was assigned to each patient. Each medication package contained one 20-ml vial of gadopentetate dimeglumine and one 10-ml vial of normal saline solution for IV flush following administration of gadopentetate dimeglumine.

After giving written informed consent, patient participation in the study began when baseline evaluations were initiated and baseline laboratory values were examined and found to be in the appropriate range. MR images were obtained on several MR systems at various field strengths: 0.15, 0.35, 1.0, and 1.5 T. Short TR/short TE (T1) and long TR/long TE (T2) sagittal and T1 axial spin-echo sequences were obtained before administration of the contrast agent.

Gadopentetate dimeglumine (0.5 mol/l) was administered IV in a dose of 0.2 ml/kg (0.1 mmol/kg) and at a rate of approximately 10 ml/min. This was followed by a 5-ml saline flush. After administration of the contrast agent, a T1 sagittal scan, a T2 sagittal scan, a T1 axial scan, and a repeat final T1 sagittal scan were obtained, in that order.

The films were interpreted by the investigator at each study site. There were three parts to the efficacy evaluation: (1) the global evaluation, (2) the contrast score evaluation, and (3) the intensity measurement evaluation. The series of global evaluation questions is listed in Table 2. If there was a positive response to the question "Compared with preinjection MR images, do postinjection MR images provide additional radiologic information?" the investigators were asked to consider three scan comparisons (preinjection T1 vs postinjection T1, preinjection T2 vs postinjection T2, and preinjection T2 vs postinjection T1) and to give answers (yes, no, or not applicable) as to whether the additional information concerned the following parameters: lesion location, lesion size, lesion configuration, differentiation from edema, differentiation from necrosis, and number of

TABLE 2: Global Evaluation Questions

Is there postinjection contrast enhancement? If no, is this useful diagnostic information? (If considered useful, explain.)
Compared with preinjection MR images, do postinjection images provide additional radiologic information?
If the answer is yes, consider the following scan comparisons: preinjection T2 vs postinjection T1, pre- vs postinjection T1, and pre- vs postinjection T2. Is additional information provided concerning:
Lesion location
Lesion size
Lesion configuration
Differentiation from edema
Differentiation from necrosis
Number of lesions (if yes, give number of additional lesions)
Does your preinjection MR diagnosis differ from the referral diagnosis?
If yes, indicate most specific diagnosis.
Which pulse sequence provided the most additional information?
Does your postinjection MR diagnosis differ from your preinjection MR diagnosis?
If yes, indicate most specific diagnosis.
Which pulse sequence provided the most additional information?

lesions. Parameters such as the extent of edema or necrosis were judged from the MR appearance of the lesions. No attempt was made to correlate the size of the lesion with the amount of enhancement; therefore, some of these parameters were estimations based on the available imaging information. If there was a yes answer to the additional information inquiry regarding the number of lesions, the number of additional lesions observed was recorded.

For the contrast score evaluation, each investigator rated the relative intensity of tissue and disease within a particular image. A score of zero was given if there was no enhancement; that is, if there was no delineation of boundary or increase in relative intensity of the suspected lesion. A score of 1 was given if contrast was equivocal; that is, if a marginally delineated boundary between the lesion and surrounding area could be seen. A score of 2 was given if contrast was good; that is, if an adequately delineated boundary between the lesion and surrounding area could be seen. Finally, a score of 3 was given if contrast was excellent; that is, if a clearly delineated boundary could be seen between the lesion and surrounding area.

An additional analysis was performed in which the distributions of the contrast score difference between specified scans were compared. The distribution of the preinjection contrast scores vs the postinjection scores for each of the following five scan comparisons was calculated: T1 sagittal, pre- vs first postinjection; T2 sagittal, pre- vs postinjection; T1 axial, pre- vs postinjection; T2 sagittal, preinjection, vs T1 sagittal, first postinjection; and T1 sagittal, first postinjection, vs last postinjection. The contrast score difference consisted of the postinjection score minus the preinjection score. Results of +1, +2, or +3 indicated that the postinjection score was better (higher) than the preinjection score; results of -3, -2, or -1 indicated that the preinjection score was better than the postinjection score. Results of zero indicated equal pre- and postinjection scores.

For each scan, intensity measurements were evaluated for normal cord and mass lesion, if present. If normal cord was not present on a particular scan, an alternative anatomic location that contained normal tissue was chosen for reference purposes. The absolute difference between the intensity of the mass and normal cord was divided by the normal cord intensity. Five scan comparisons were made (the same as those described for the contrast score differences above) in order to evaluate the intensity score results.

TABLE 1: Inclusion and Exclusion Criteria for Entering Patients into This Study

Inclusion
Presented with symptoms suggestive of spinal tumors
Was at least 18 years old
If female, was not pregnant or nursing, and was using an effective form of contraception (for at least the previous month)
Was willing and able to continue study participation for a 24-hr period after administration of the study medication to ensure the completion of all study parameters
Had signed informed consent to participate in the study
Exclusion
Weight more than 100 kg
Considered medically unstable
Undergoing cytostatic therapy or radiation therapy during the study period
Severe or uncontrolled hypertension
Any contraindication(s) to MR imaging (e.g., cardiac pacemaker or surgical clips)
Serum creatinine value above 2.0 mg/dl
Had received any investigational drug within 30 days of baseline evaluations
Had received an iodinated contrast agent within 44 hr
Had sickle cell or other hemolytic anemia
Had previously received gadopentetate dimeglumine under this protocol

After the overall analyses, the patients were divided into three groups depending on whether the location of the disease was extradural, intradural extramedullary, or intramedullary. The results were then reinterpreted in light of this new information. The global analyses and the contrast evaluations were reviewed in order to detect trends within each group.

Safety evaluations were performed also. At baseline, which was within a 72-hr period preceding administration of the contrast medium, a clinical history, physical examination, and neurologic examination were obtained. Hematologic (hematocrit, hemoglobin, RBC count, WBC count, differential, and platelet estimate) and blood chemistry (blood urea nitrogen, creatinine, lactate dehydrogenase, SGOT, SGPT, potassium, sodium, chloride, glucose, total protein, alkaline phosphatase, total bilirubin, indirect bilirubin [if total bilirubin was within normal limits, indirect bilirubin was not necessary], uric acid, and iron) evaluations were performed also. A second physical examination and neurologic examination were performed 24 hr after gadopentetate dimeglumine was administered. In addition, vital signs were monitored within 1 hr prior to drug administration, at the completion of postinjection imaging, 2–4 hr after injection, and 24 hr after injection. Blood chemistry evaluations were repeated at 2–4 hr and 24 hr after injection, while hematologic evaluations were repeated 24 hr after injection. During the entire procedure and the 24-hr period following injection of the contrast agent, patients were observed for clinical adverse effects. Symptoms were graded as mild, moderate, or severe in intensity and classified by the investigator as being definitely, probably, possibly, remotely, or not related to the study drug. Time of onset, duration, treatment (if any), and outcome were also recorded for each adverse reaction.

Results

Information regarding the referral diagnoses, final diagnoses based on both pre- and postinjection imaging and clinical findings, and the location of the lesions is shown in Tables 3 and 4.

Four patients with a referral diagnosis of bone metastases had different final diagnoses. In two cases, the MR scans proved negative; in one case, leptomeningeal tumor was found; in the fourth case, arachnoiditis was shown. In 12 cases, the diagnosis was changed in patients suspected of having primary tumors of nonglial origin. In six cases, no abnormality was found. In two cases, extradural tumor was seen. In another two cases, cord tumors were noted. In one case, only postinfectious scarring was found. In another case, a patient was found to have leptomeningeal tumor spread. In

10 cases, diagnoses were changed in patients suspected of having gliomas. In four cases, the diagnosis was changed to normal. In three cases, the diagnosis was changed to benign syrinx. In two patients, severe degenerative changes were noted. In one patient, diffuse subarachnoid metastases were found. In two cases, the referral diagnosis of leptomeningeal tumor was changed after further clinical evaluation. In one patient no abnormality was found, while the other proved to have extradural metastases. Finally, in five patients, the diagnosis of miscellaneous was changed to another diagnosis. In three cases, the category of unknown was changed to cord glioma. In one case, the referral diagnosis of unknown was changed to negative. In one final case, a cord heman-gioblastoma was found.

Efficacy Evaluation

Global evaluation.—The results of the global evaluation are summarized in Table 5. Contrast enhancement was seen in 86 (77%) of 111 patients. Seventy-nine of the 86 cases were tumors. Contrast enhancement was absent in 25 (23%) of 111 patients; this absence was considered useful diagnostic information in all patients, but particularly in 21 of the 25 cases that proved not to be neoplasms. Fourteen of the 25 cases in which spinal tumors were suspected, but in which no enhancement was seen, were found to be totally normal. The lack of contrast enhancement increased the investigators' confidence in their interpretations of the images. Five patients were believed to have benign syringes, and the lack of enhancement was believed to diminish the likelihood of tumor. One patient was diagnosed as having multiple sclerosis involving the cord, and the existence of nonenhancing plaques in the cord was thought to be consistent with the behavior of

TABLE 3: Comparison of Referral and Final Diagnoses

Diagnosis	No. of Patients	
	Referral Diagnosis	Final Diagnosis
Metastases (extradural and intradural) ^a	36	36
Leukemia/lymphoma/myeloma	10	10
Primary other (nonglial origin)	27	16
Glial origin	28	23
Miscellaneous	12	14
Negative	0	14
Total	113	113

^a The data for two of these patients were not considered valid for efficacy evaluations, but were included here for completeness.

TABLE 4: Location of Lesions

Location	No. of Patients
Cervical spine	9
Thoracic spine	21
Lumbosacral spine	16
Cervical canal and contents	25
Thoracic canal and contents	19
Lumbosacral canal and contents	22
More than one location	1
Total	113

Note.—The data for two patients were not considered valid for efficacy evaluations, but were included here for completeness. These patients are counted in cervical and lumbosacral spine locations.

TABLE 5: Results of Global Evaluation

Variable	No. of Patients (%)
Postinjection contrast enhancement	
Present	86/111 (77)
Absent	25/111 (23)
Absence was useful diagnostic information	25/25 (100)
Additional radiologic information obtained from post- compared with preinjection scans	73/111 (66)

multiple sclerosis plaques in the brain. One patient with a history of meningitis was found to have postinfectious adhesions. The lack of enhancement helped to exclude superimposed tumor. Four patients in whom enhancement was not exhibited, but who were found to have tumors, are discussed later.

In 73 (66%) of 111 patients, additional radiologic information, including pertinent negative information, was obtained from the post- compared with the preinjection scans. In all of these cases, the pulse sequences that provided the most additional information were the T1-weighted sequences.

Of these 73 patients, additional information regarding lesion location was found in 44 (60%). In 49 (67%) of the 73 patients, lesion size was better defined. In 68 (93%) of the 73 patients, lesion configuration was better delineated. In 18 (25%) of the 73 patients, differentiation of tumor from edema and, in a similar number, differentiation of tumor from necrosis were possible. In 21 (29%) of the 73 patients, the number of lesions noted on the postinjection scans differed from the number noted on the preinjection scans. In 20 patients, additional lesions were seen on the postinjection scan compared with the preinjection scan; in one patient, a lesion was observed on the preinjection scan that was not seen on the postinjection scan.

Contrast score evaluation.—The results of the evaluations of the scans for enhancement are given in Table 6. Of 110 patients who had both T1 sagittal pre- and first postinjection scans, excellent contrast between the lesion and the surrounding area was seen on the first postcontrast T1 scan in 43 (39%), compared with 12 (11%) on the T1 scan prior to the administration of gadopentetate dimeglumine. At the other extreme, in 53 (48%), no enhancement was seen before the administration of gadopentetate dimeglumine, while in only 24 (22%) was there no enhancement on the same scan after injection of gadopentetate dimeglumine. The additional analysis, comparing the distribution of the contrast score difference between specified scans, was helpful also. For the T1 sagittal scans, the preinjection score was better (higher) than the postinjection (early and/or late) score in 10 patients (9%). In 37 patients (34%), preinjection scores equaled postinjection scores. In 63 patients (57%), the postinjection scores were better (higher) than the preinjection scores. The difference in the proportion of patients with a better score after injection compared with those with a better score before injection,

using the GSK (Grizzle, Starmer, Koch) method, was found to be statistically significant ($p < .01$) [12]. Similar values were found when the contrast scores for T1 axial scans before and after injection were compared.

Intensity measurement evaluation.—Finally, for each scan, intensity score ratios were analyzed (Table 7). The intensity score ratios support the findings of the global evaluation and the contrast evaluation. In 86 (78%) of 110 patients, higher-intensity score ratios were found for the mass (lesion) on the postinjection T1 sagittal scan, compared with eight (7%) in whom higher-intensity score ratios were found on the preinjection T1 sagittal scan. Similar figures were found for the T1 axial scans, comparing pre- and postinjection scans. Less dramatic findings, but still in favor of the postinjection scans, were found when the T2 sagittal or the T1 sagittal postinjection scans and T2 sagittal preinjection scans were compared.

Analysis by spinal compartment.—Altogether, there were 38 cases of extradural tumor, 22 cases of intradural extramedullary tumor, and 23 cases of intramedullary tumor, for a total of 83 cases. The remaining 28 of the 111 patients for whom there was valid efficacy data did not have tumors but

TABLE 7: Results of Intensity Score Evaluations

Scan Comparison	No. of Patients
T1 sagittal	
Preinjection better	8
Postinjection better	86
T2 sagittal	
Preinjection better	24
Postinjection better	69
T1 axial	
Preinjection better	10
Postinjection better	80
T1 sagittal postinjection vs T2 sagittal preinjection	
Preinjection better	19
Postinjection better	75
Postinjection T1 sagittal	
Last scan better	29
First scan better	64

Note.—The numbers for preinjection better indicate those patients who had higher-intensity score ratios on the preinjection scan than on the postinjection scan for the mass lesion; the numbers for postinjection better indicate patients who had higher-intensity score ratios on the postinjection scan than on the preinjection scan for the mass lesion.

TABLE 6: Results of Contrast Score Evaluations

Scan	No. of Patients				
	Total	No Enhancement (0)	Equivocal (1)	Good (2)	Excellent (3)
Sagittal					
T1 (preinjection)	110	53	23	22	12
T1 (first postinjection)	110	24	19	24	43
T1 (last postinjection)	108	23	21	25	39
T2 (preinjection)	111	43	29	27	12
T2 (postinjection)	111	31	17	39	24
Axial					
T1 (preinjection)	109	61	26	18	4
T1 (postinjection)	109	26	19	32	32

were found to be either normal or to have nonneoplastic lesions, such as benign syrinxes. In the extradural space, enhancement was present in all but two cases of tumor, one of myeloma, and one of leukemia. Lack of enhancement was considered useful in both cases. The absence of enhancement was consistent with the quiescent stage of the disease after recent therapy.

Enhancement provided additional information in 20 of the 38 cases of extradural tumor that did enhance when precontrast scans were compared with postcontrast T1-weighted scans (see Fig. 1). In 17 of the 20 patients, contrast material helped to better define the configuration of the lesion. In nine of the 20 patients, contrast material provided more information regarding lesion location; in nine patients, contrast material permitted more accurate assessment of lesion size. In six patients, contrast material enabled better differentiation to be made between tumor and necrosis. In five patients, contrast material helped better define the number of lesions; in five patients, contrast material helped to differentiate tumor from surrounding edema. In 18 of the 38 cases, no additional information was obtained. In 11 of the 38 cases analyzed, decrease in contrast score between the lesion and its surrounding area was seen after injection. In the remaining cases, the contrast either did not change (nine patients) or improved (18 patients) after the administration of contrast agent.

In the intradural extramedullary space, enhancement was present in 20 of 22 cases (see Fig. 2). The exceptions occurred in a case of leptomeningeal prostate carcinoma and in a case of possible epidermoid. For the case of subarachnoid tumor, lack of enhancement was considered useful, and this finding, combined with the clinical history, resulted in a change of diagnosis to leptomeningeal tumor spread. Although the referral diagnosis was schwannoma, the lack of any visible

mass, especially after the administration of contrast material, was believed to diminish the likelihood of this possibility. For the case of possible epidermoid, a cystic mass was noted. Lack of enhancement was believed to be typical of this type of tumor.

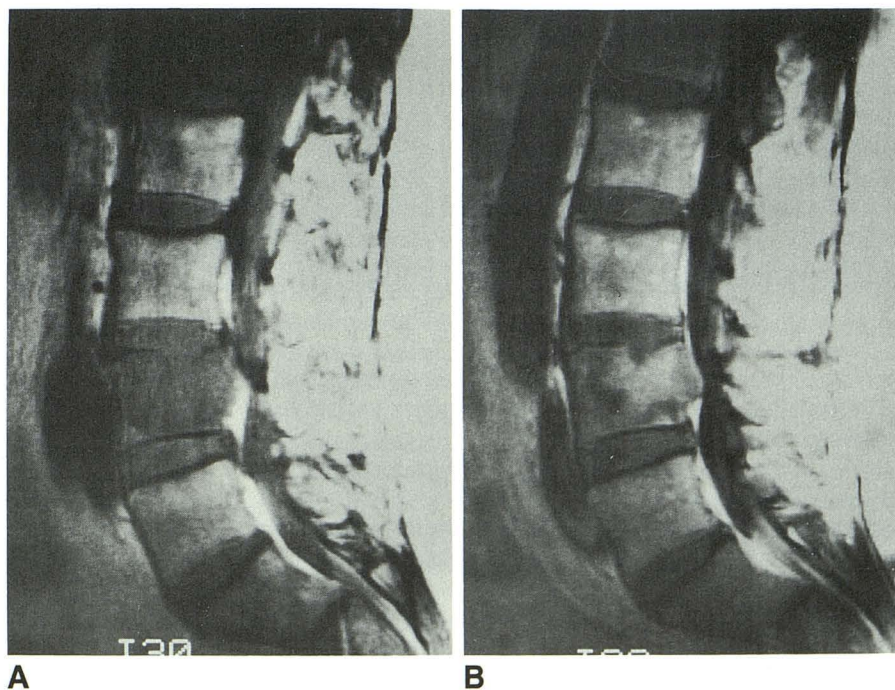
Eight of the 22 cases of neoplasm in the intradural extramedullary space were primary tumors, mainly meningiomas or neurofibromas. Fourteen of the 22 cases were leptomeningeal tumors or conus and filum neoplasms. Additional information was found in 21 of the 22 cases when precontrast scans were compared with postcontrast T1-weighted scans. In 18 of the 21 patients, contrast material improved evaluation of the configuration of the lesion. In 16 patients, contrast material helped in the assessment of lesion size, while in 14, contrast material improved the ability to determine lesion location. In eight patients, the administration of contrast material resulted in a change in the number of lesions seen. In three patients, contrast material helped differentiate necrosis from tumor. After the administration of gadopentetate dimeglumine, the contrast either remained unchanged (six patients) or increased (15 patients), with the exception of one case in which the contrast decreased.

For the intramedullary tumors, enhancement was seen in all 23 cases (see Fig. 3). Additional information was obtained in 22 cases when precontrast scans were compared with postcontrast T1-weighted scans. In 21 of the 22 patients, contrast material helped to better determine the configuration of the lesion. In 20 patients, contrast material provided more accurate assessment of lesion size, while in 16, more precise evaluation of lesion location was obtained. In nine patients, tumor could be better separated from necrosis. In each of seven patients, the number of lesions was more correctly tabulated and the differentiation of tumor from edema was

Fig. 1.—Extradural tumor (metastatic melanoma).

A, Short TR sagittal scan (600/20) shows low-intensity lesions at L1 and L4, associated with compression of L4.

B, After administration of gadopentetate dimeglumine, short TR sagittal scan (600/20) discloses a much more homogeneous appearance to vertebral bodies owing to enhancement of L1 and L4 to near isointensity relative to normal marrow. Compression deformity of L4 is still easily identified.



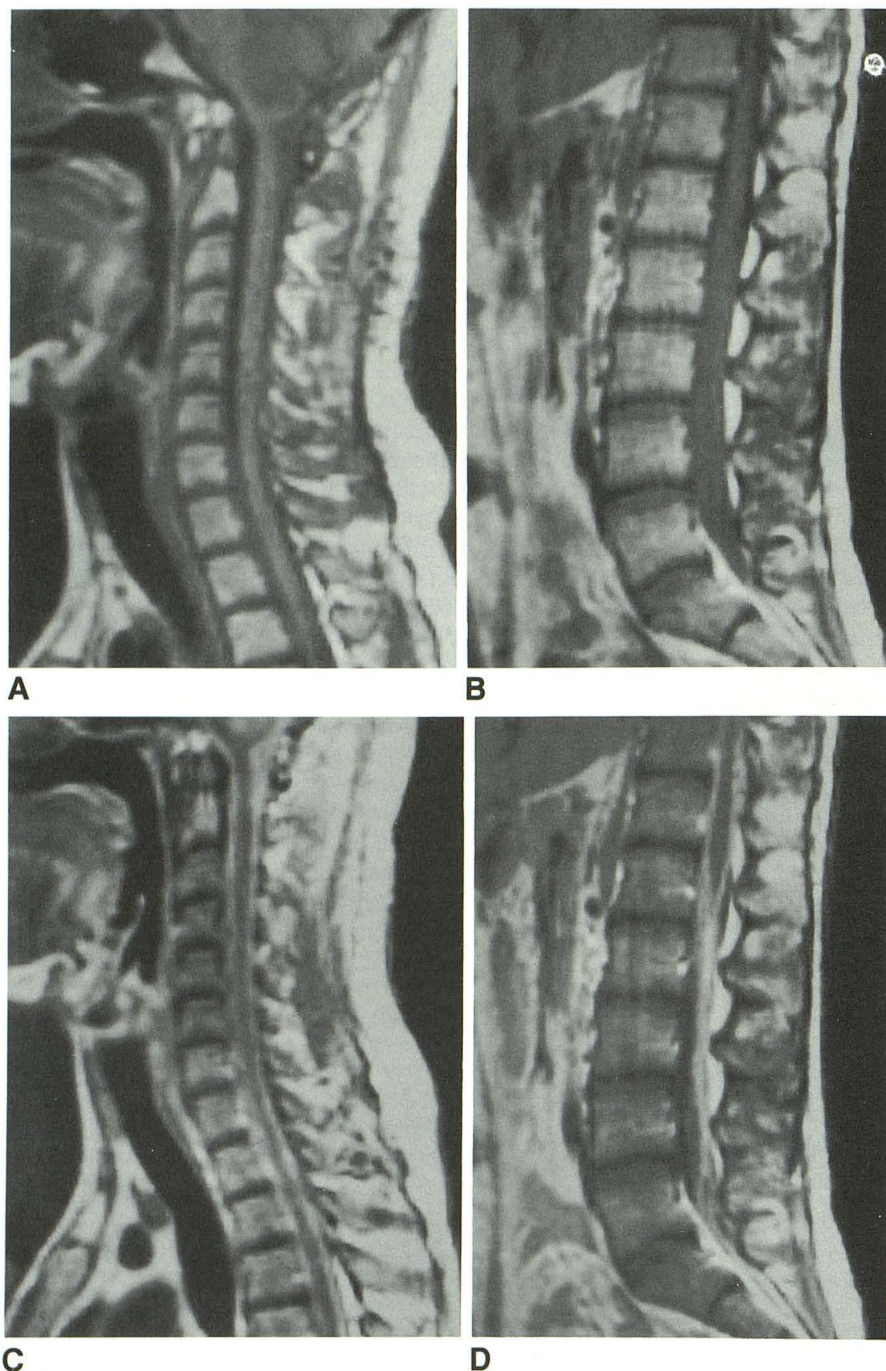


Fig. 2.—Intradural extramedullary tumor (seeding from a high-grade cerebral astrocytoma).

A and B, Short TR/TE sagittal scans (500/20) do not show a definite abnormality in subarachnoid space, although mass is present in posterior fossa.

C and D, Short TR/TE sagittal scans (500/20) after administration of gadopentetate dimeglumine disclose diffuse enhancing tumor filling subarachnoid space. Enhancing tumor was also seen in posterior fossa.

facilitated. After the administration of gadopentetate dimeglumine, contrast either remained unchanged (four patients) or increased (19 patients).

In five of the 28 cases in which no tumor was found, benign syrinxes were identified. These lesions lacked contrast enhancement, and the administration of contrast medium was important in evaluating these five lesions.

Safety Evaluation

In regard to safety and tolerance, 10 patients (8.8%) reported at least one adverse reaction. Of these patients, six

(5.3%) of 113 reported adverse reactions considered by the investigators to be possibly or remotely related to administration of gadopentetate dimeglumine. No adverse reaction was considered to be probably or definitely related to the study drug. Headache, reported by five patients, and vasodilatation, reported by two patients, were the most frequently reported adverse reactions. All other adverse reactions were reported by one patient each. These included dizziness, tiredness, a burning sensation at the injection site, burning sensation in an area surrounding the injection site, phlebitis, diarrhea, thirst, drowsiness, and skin tear from tape (the COSTART term used to code this adverse drug reaction was epidermal

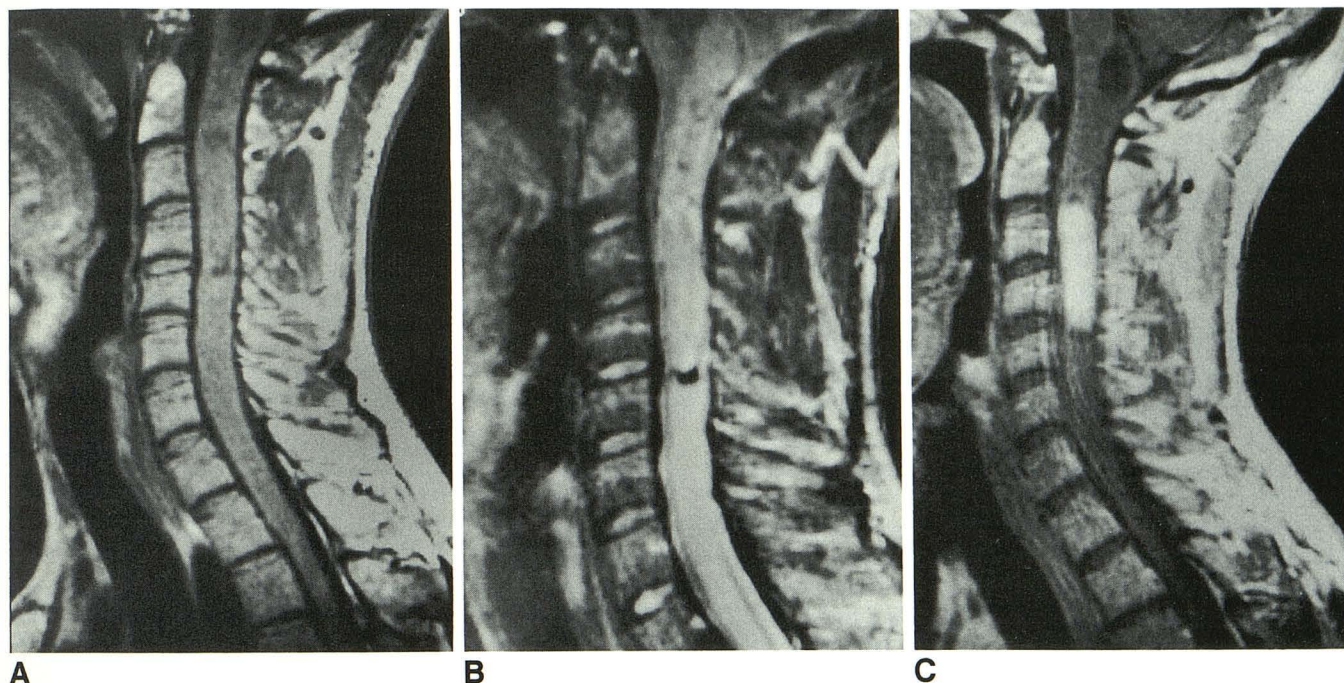


Fig. 3.—Intramedullary tumor (ependymoma).

A and B, Short TR/TE (600/20) and long TR/TE (1933/70) sagittal scans show markedly expanded cord. Superior cyst is seen at cervicomedullary junction. An extensive area of heterogeneous signal extends from below to top of C5. High signal on long TR images occupies remainder of cervical and upper thoracic cord.

C, Postcontrast short TR/TE (600/20) sagittal scan shows focal enhancing lesion, which proved to be tumor nidus at surgery. While tumor undoubtedly extends outside of nidus, enhancement highlights primary area of blood-cord barrier breakdown.

necrosis). One severe adverse reaction (stupor) was reported; this was not considered by the investigator to be related to administration of gadopentetate dimeglumine.

Laboratory evaluations of hematologic and blood chemistry parameters showed no trends or clinically significant changes over baseline values. In general, as noted in earlier clinical trials, the only drug-related laboratory findings were clinically insignificant transient increases in serum iron and bilirubin levels [13]. In our study two patients had elevations in serum iron levels at the 2- to 4-hr postinjection evaluation that were considered clinically significant and drug-related by the investigators. (The patients had no clinical signs or symptoms related to the elevated iron levels, and no treatment was necessary.) In one patient the serum iron level had returned to within normal range at the 24-hr evaluation; in the other patient, although still having an elevated serum iron 24 hr after injection, no baseline evaluation was available for comparison.

Other safety measurements included physical examinations, vital signs, and neurologic examinations, which were evaluated at baseline and at various postinjection times. No clinically significant changes or trends in change from baseline were observed for these parameters.

Discussion

This open-label, multicenter study was designed to evaluate the safety and efficacy of 0.1 mmol/kg of gadopentetate dimeglumine administered IV for MR imaging. The efficacy of gadopentetate dimeglumine as a contrast medium was dem-

onstrated by comparing postinjection images with preinjection images for contrast enhancement and for the facilitation of the visualization of lesions. This was primarily shown in the global evaluation questions concerning contrast enhancement, in the distribution of contrast score differences, and in the numbers of lesions observed. Further evidence of efficacy was demonstrated in these studies by the ability of gadopentetate dimeglumine to provide additional radiologic information on the postinjection scans, by the change in diagnoses made from the pre- to postinjection scans, and by the intensity score results.

The gadopentetate dimeglumine dose of 0.1 mmol/kg demonstrated a high level of safety and tolerance, as evidenced by the absence of any clinically significant trend toward abnormal changes from baseline evaluations for physical and neurologic examinations, vital signs, hematology, and blood chemistry; the absence of abnormal hematology or blood chemistry laboratory values attributed by the investigators to the study drug, with the exception of serum iron elevations in two patients; and the low prevalence and mild nature of adverse reactions.

Just as striking, however, was the obvious difference noted in the complexity of the results found between the head and the spine in the administration of gadopentetate dimeglumine. In previous analyses, including the multicenter double-blind, placebo-controlled study of gadopentetate dimeglumine in patients with cerebral lesions [14], evaluation of gadopentetate dimeglumine in the head had depicted fairly homogeneous results. For example, the use of gadopentetate dimeglumine appeared generally beneficial. Even in those

circumstances in which no enhancement was seen, this information was regarded as useful. However, in the spine, the situation appears far more complex owing to the large amount of fat in the marrow space, which appears as high intensity on T1 images [3, 4].

In general, the results of this multicenter study closely parallel the trends suggested in the early studies with respect to spinal tumors [1–11]. Tumors in the extradural space showed varying degrees of enhancement [3, 4]. This enhancement was not always beneficial, since before injection of gadopentetate dimeglumine these lesions were of low intensity compared with the high intensity of normal bone marrow on T1 images. Enhancement, on occasion, served to decrease the contrast between the lesions and surroundings and thereby obscured the lesions. The extradural space was the only space in which the investigators noted that enhancement did not provide additional information in nearly all cases. Nevertheless, even in the extradural space, contrast material provided additional information in the majority of cases. For example, although on postcontrast T1 scans decreased contrast between the lesion and the surrounding marrow might be seen, increased contrast between the enhancing lesion and the low-intensity adjacent CSF was visualized. Postcontrast T1 scans thus served to increase contrast at the important tumor/CSF interface in some cases. In the intradural extramedullary and intramedullary spaces, enhancement of tumors, whether primary or secondary, was found to be extremely beneficial [1, 2, 4, 6–11]. In nearly all of these cases, investigators found that contrast enhancement provided additional information.

ACKNOWLEDGMENTS

We thank Rosemary Blumetti for editorial assistance, Deborah Ellicks and Karen Wall for assistance in preparing the manuscript,

and Debra Bernstein for assistance in performing the statistical analyses.

REFERENCES

1. Bydder G, Brown J, Niendorf HP, et al. Enhancement of cervical intraspinal tumor in MR imaging with intravenous gadolinium-DTPA. *J Comput Assist Tomogr* 1985;9:847–851
2. Sze G, Abramson A, Krol G, et al. Gadolinium-DTPA/dimeglumine in the MR evaluation of intradural extramedullary spinal disease. *AJNR* 1988;9:153–163, *AJR* 1988;150:911–921
3. Sze G, Krol G, Zimmerman RD, Deck MDF. Gadolinium-DTPA: malignant extradural spinal tumors. *Radiology* 1988;167:217–233
4. Sze G. MR of the spine: contrast agents. *Radiol Clin North Am* 1988;26:1009–1024
5. Hueftle MG, Modic MT, Ross JS, et al. Lumbar spine: postoperative MR imaging with Gd-DTPA. *Radiology* 1988;167:817–824
6. Valk J. Gadolinium-DTPA in MR spinal lesions. *AJNR* 1988;9:345–350
7. Sze G, Krol G, Zimmerman RD, Deck MDF. Intramedullary disease of the spine: diagnosis using gadolinium-DTPA-enhanced MR imaging. *AJNR* 1988;9:847–858, *AJR* 1988;151:1193–1204
8. Stimac GK, Porter BA, Olson DO, et al. Gadolinium-DTPA-enhanced MR imaging of spinal neoplasms: preliminary investigation and comparison with unenhanced spin-echo and STIR sequences. *AJNR* 1988;9:839–846, *AJR* 1988;151:1185–1192
9. Dillon WP, Norman D, Newton TH, Bolla K, Mark A. Intradural spinal cord lesions: Gd-DTPA-enhanced MR imaging. *Radiology* 1989;170:229–237
10. Sze G, Bravo S, Krol G. Spinal lesions: quantitative and qualitative temporal evaluation of gadopentetate dimeglumine enhancement in MR imaging. *Radiology* 1989;170:849–856
11. Parizel PM, Baleriaux D, Rodesch G, et al. Gadolinium-DTPA-enhanced MR imaging of spinal tumors. *AJNR* 1989;10:249–258
12. Grizzle JE, Starmer CF, Koch GG. Analysis of categorical data by linear models. *Biometrics* 1969;25:489–496
13. Goldstein HA, Kashanian F, Blumetti RF, et al. Safety assessment of gadopentetate dimeglumine in United States clinical trials. *Radiology* 1990;174:17–23
14. Russell EJ, Schaible TF, Dillon W, et al. Multicenter double-blind placebo-controlled study of gadopentetate dimeglumine as an MR contrast agent: evaluation in patients with cerebral lesions. *AJNR* 1989;10:53–63