

Generic Contrast Agents

Our portfolio is growing to serve you better. Now you have a *choice*.



FRESENIUS
KABI

[VIEW CATALOG](#)

AJNR

Infantile Alexander disease: MR appearance of a biopsy-proved case.

M Shah and J S Ross

AJNR Am J Neuroradiol 1990, 11 (6) 1105-1106

<http://www.ajnr.org/content/11/6/1105.citation>

This information is current as
of May 17, 2025.

Infantile Alexander Disease: MR Appearance of a Biopsy-Proved Case

Manjul Shah¹ and Jeffrey S. Ross

Alexander disease is a progressive neurodegenerative disorder characterized pathologically by the accumulation of Rosenthal fibers in the subependymal, subpial, and perivascular regions [1]. Enzymatic analyses and histochemical stains of muscle biopsies provide an accurate diagnosis of

nearly all leukodystrophies except Canavan spongy degeneration and Alexander disease [2].

Recent reports have described the CT findings of Alexander disease as low attenuation of the deep cerebral white matter, increased attenuation in the corpus striatum and columns of

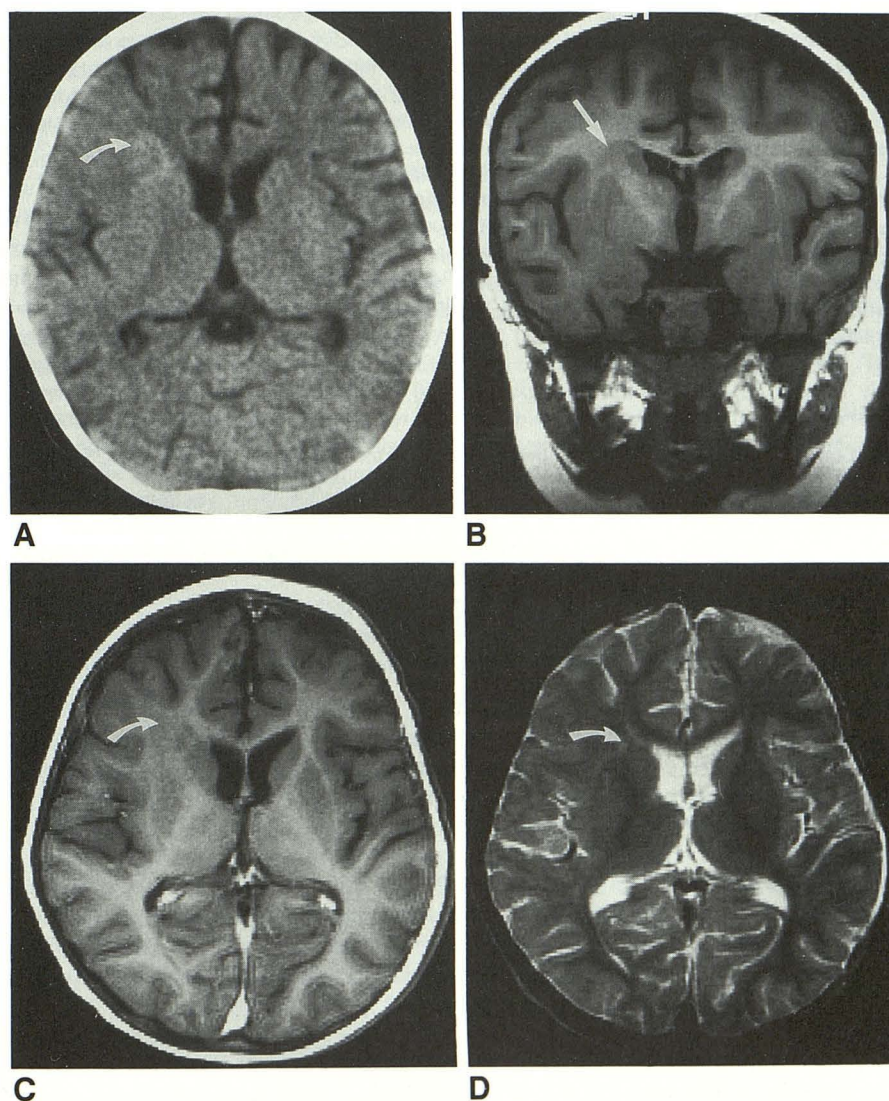


Fig. 1.—A, Noncontrast CT scan shows vague area of increased attenuation adjacent to head of right caudate nucleus (arrow).

B, Coronal T1-weighted (700/20/4) MR image shows area of decreased signal in white matter adjacent to, and extending into, head of right caudate nucleus (arrow).

C, Axial T1-weighted (600/20) postcontrast MR image shows no significant contrast enhancement (arrow).

D, Axial T2-weighted (2500/90) MR image shows subtle area of hyperintensity (arrow).

Received January 26, 1990; revision requested April 16, 1990; revision received July 5, 1990; accepted July 10, 1990.

¹ Both authors: Department of Radiology, Cleveland Clinic Foundation, 9500 Euclid Ave., Cleveland, OH 44195. Address reprint requests to J. S. Ross.

the fornices, and contrast-enhancing lesions in the periventricular frontal, caudate nuclei, and thalamic regions [2-4].

This article details the MR findings in a case of biopsy-proved Alexander disease.

Case Report

The patient is an 11-month-old boy with normal birth history and developmental milestones. He presented with recent-onset seizures that consisted of tonic-clonic movements of the extremities, which became so frequent that the patient was admitted to the ICU and treated with IV Valium, phenobarbital, Tegretol, and Dilantin.

A noncontrast head CT scan at the time of admission demonstrated a vague area of increased density adjacent to the right frontal horn in the region of the head of the caudate nucleus. There was no mass effect, shift, edema, or abnormal contrast enhancement noted (Fig. 1A).

The patient continued to have intractable seizures. An EEG demonstrated epileptogenic discharge in the right frontal area. Subsequently, a contrast-enhanced MR study was performed. T1-weighted images demonstrated an abnormal area of decreased signal in the white matter adjacent to, and extending into, the head of the right caudate nucleus (Fig. 1B). There was no contrast enhancement noted (Fig. 1C). The left side was completely normal. T2-weighted images demonstrated a subtle area of increased signal intensity in the same area (Fig. 1D).

The differential diagnoses for this unusual appearance included a white matter dysmyelinating process or heterotopic gray matter.

Stereotaxic biopsy of the head of the right caudate and adjacent white matter was performed. Pathologic examination demonstrated marked astrocytic proliferation with abundant Rosenthal fibers especially concentrated around blood vessels, leading to a diagnosis of Alexander disease.

Discussion

Alexander disease is a progressive neurodegenerative disorder with three clinical subgroups. The infantile group is characterized by early onset of megalencephaly, psychomotor retardation, spasticity, and seizures. The illness is invariably fatal, with an average duration of 2½ years.

In the juvenile group, onset of symptoms occurs between 7 and 14 years of age. Seizures are less prominent, and progressive bulbar symptoms with spasticity are common. The average duration of illness is 8 years.

In the adult group, onset occurs between the second and seventh decades and the disease may have a course consistent with classical multiple sclerosis, or it may be asymptomatic.

The pathologic hallmark of all subgroups is the diffuse accumulation of Rosenthal fibers, particularly in the subependymal, subpial, and perivascular regions. Demyelination is extensive in the infantile cases, less severe in the juvenile group, and variable in adults. Neurons are invariably well preserved [1].

The cause of Alexander disease is unknown. Despite the fact that there is no specific treatment, a positive diagnosis is important for the exclusion of a treatable condition and to establish the prognosis. A primary nonneoplastic disease of astrocytes rather than a primary demyelinating process has been proposed [1].

The CT findings in this case are somewhat atypical of Alexander disease because of the striking asymmetry of findings and lack of white matter hypodensity. Hyperdensity in the caudate nucleus has been described in Alexander disease. Previous reports have noted variable contrast enhancement on CT, with speculation that it is present early in the process and disappears with progression of the disease.

This is the first report describing the contrast-enhanced MR findings, which are remarkable for the striking asymmetry of the abnormal white matter hypointensity (which correlated pathologically with deposition of Rosenthal fibers) and lack of contrast enhancement.

In summary, infantile Alexander disease needs to be considered in the clinical context of intractable seizures with predominantly frontal lobe white matter findings on CT and MR examinations.

REFERENCES

1. Borrett D, Becker LE. Alexander's disease: a disease of astrocytes. *Brain* 1985;108:367-385
2. Holland IM, Kendall BE. Computed tomography in Alexander's disease. *Neuroradiology* 1980;20:103-106
3. Trammer BL, Naidich TP, CalCanto MC, Malone DC, Carsen MB. Noninvasive CT diagnosis of infantile Alexander's disease: pathologic correlation. *J Comput Assist Tomogr* 1983;7:509-516
4. Farrell K, Chuang S, Becker LE. Computed tomography in Alexander's disease. *Ann Neurol* 1984;15:605-607