

# Generic Contrast Agents

Our portfolio is growing to serve you better. Now you have a *choice*.



FRESENIUS  
KABI

[VIEW CATALOG](#)

# AJNR

## **Paranasal Sinuses on MR Images of the Brain: Significance of Mucosal Thickening**

Kevin M. Rak, John D. Newell II, Wayne F. Yakes, Melissa A. Damiano and James M. Luethke

*AJNR Am J Neuroradiol* 1990, 11 (6) 1211-1214

<http://www.ajnr.org/content/11/6/1211>

This information is current as  
of May 15, 2025.

# Paranasal Sinuses on MR Images of the Brain: Significance of Mucosal Thickening

Kevin M. Rak<sup>1</sup>  
John D. Newell II<sup>2</sup>  
Wayne F. Yakes<sup>1</sup>  
Melissa A. Damiano<sup>1</sup>  
James M. Luethke<sup>1</sup>

One hundred twenty-eight patients were examined prospectively to determine the significance of mucosal thickening seen in the paranasal sinuses during routine MR imaging of the brain. On the basis of responses to a questionnaire, each patient was categorized as symptomatic ( $n = 60$ ) or asymptomatic ( $n = 68$ ) for paranasal sinus disease. Patients were categorized further on the basis of the maximal mucosal thickening seen by MR in any paranasal sinus. A modified  $t$  test was used to compare the prevalence of various degrees of mucosal thickening between symptomatic and asymptomatic groups. Statistically significant differences between the groups were seen only in those patients with normal sinuses and in those with 4 mm or more of mucosal thickening.

We conclude that mucosal thickening of up to 3 mm is common and lacks clinical significance in asymptomatic patients. An ancillary finding is that 1- to 2-mm areas of mucosal thickening in the ethmoidal sinuses occur in 63% of asymptomatic patients. This minimal mucosal thickening in the ethmoidal sinuses is thought to be a normal variant, possibly a function of the physiologic nasal cycle.

*AJNR* 11:1211-1214, November/December 1990; *AJR* 156: February 1991

MR imaging is sensitive for detecting inflammation of the mucosa that occurs with sinusitis. In a prospective study of 128 patients, we attempted to determine the clinical significance of mucosal abnormalities seen in the paranasal sinuses during routine MR imaging of the brain.

## Subjects and Methods

We prospectively examined 128 random patients (age range, 15-85 years) who had MR imaging for intracranial disease. All patients were scanned on a 1.5-T unit (Signa, General Electric; Milwaukee, WI). Spin-echo axial MR images, 2800/45,90 (TR/TE), were obtained through the paranasal sinuses in all patients. T1-weighted sagittal images (600/20) also were obtained in all patients.

With the assistance of an otolaryngologist, we developed a questionnaire to delineate common presentations of paranasal sinus disease. Before the MR examination, each patient completed this questionnaire, commenting on the presence or absence of (1) facial or retroorbital pain, (2) rhinorrhea, (3) current symptoms of allergy/hay fever or of the common cold, and (4) current use of medications such as antihistamines. Patients with one or more positive responses to these questions were categorized as symptomatic for sinus disease, whereas patients with all negative responses were classified as asymptomatic. The MR examinations were blindly reviewed without knowledge of the questionnaires' results. Each paranasal sinus was evaluated for mucosal thickness, presence or absence of air/fluid level, and evidence of retention cyst/polyp. High signal intensity on the T2-weighted images was used to distinguish inflamed mucosa from the lower signal of bone in the sinus wall. Retention cysts and polyps could not be consistently distinguished from each other, but were reported as lobular intrasinus lesions of high signal intensity on T2-weighted images.

Each patient was categorized according to the maximal mucosal thickening present in any paranasal sinus. Thus, categories included normal, 1 mm of thickening, 2 mm, 3 mm, and 4

Received March 12, 1990; revision requested May 20, 1990; revision received June 11, 1990; accepted July 13, 1990.

The opinions or assertions contained herein are the private views of the authors and are not to be construed as official or as reflecting the views of the Department of the Army or Department of Defense.

<sup>1</sup>Department of Radiology, Fitzsimons Army Medical Center, Aurora, CO 80045-5001. Address reprint requests to K. M. Rak.

<sup>2</sup>Radiology Imaging Associates, Porter Memorial Hospital, Denver, CO 80210.



mm or more of mucosal thickening. Data from the asymptomatic and symptomatic groups were compared by using a modified *t* test. Significant differences were indicated by a two-tailed probability of .05 or less.

## Results

In our initial analysis (Table 1), only two MR categories showed statistically significant differences between asymptomatic and symptomatic patients. Normal paranasal sinuses were more prevalent in the asymptomatic population, and 4 mm or greater mucosal thickening in any sinus was more common in the symptomatic group (Figs. 1 and 2). An interesting finding was that 63% of the asymptomatic patients (43 of 68) and 69% of all patients (88 of 128) had minimal, 1- to 2-mm, mucosal thickening in the ethmoidal sinuses. A second analysis was performed with this minimal ethmoidal thickening considered as normal. Ethmoidal abnormality was then categorized only if 3 mm or more of mucosal thickening was present. The results again showed statistical significance only in those patients with normal sinuses and in those with 4 mm or more of mucosal thickening (Table 2).

The prevalence of retention cysts/polyps was not significantly different between the symptomatic and asymptomatic patient groups. Four instances of air/fluid level or complete sinus opacification were seen in the symptomatic population; however, the absence of any cases in the asymptomatic

population precludes performance of statistical tests on this variable.

## Discussion

MR imaging is highly sensitive for detecting mucosal thickening of the paranasal sinuses [1]. It has previously been reported with CT that abnormalities in one or more paranasal sinuses are seen in 42% of asymptomatic adults [2]. Similarly, various degrees of mucosal thickening in the paranasal sinuses are commonly seen during routine MR of the brain. Our goal was to delineate the significance of these abnormalities and to determine if there is a degree of mucosal thickening that helps distinguish a symptomatic from an asymptomatic population. Such a finding would be of obvious clinical importance regarding further medical workup and therapy.

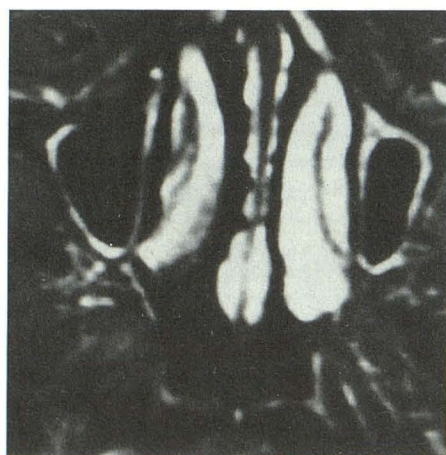
An understanding of the normal nasal cycle is essential for interpreting our data. Zinreich et al. [3] report that, in a normal adult, changes in the nasal mucosal volume occur cyclically, alternating from side to side. The time course of each cycle varies from 50 min to 6 hr. Mucosal volume changes are observed in the mucosa of the turbinates, the nasal septum, lateral wall and cavity floor, nasolacrimal ducts, and ethmoidal sinuses. The frontal, maxillary, and sphenoidal sinuses are not affected [3].

Although our patients were scanned at only one time rather

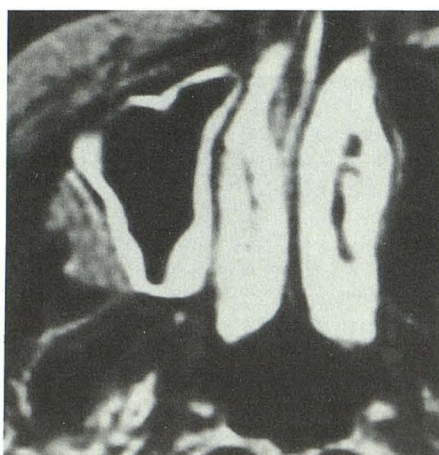
**TABLE 1: Comparison of Asymptomatic and Symptomatic Groups with All Mucosal Disease Reported**

	Normal	Retention Cysts	Air/Fluid Level or Complete Opacification	Maximal Mucosal Thickening			
				1 mm	2 mm	3 mm	≥4 mm
Asymptomatic ( <i>n</i> = 68)	21	8	0	11	30	4	2
Symptomatic ( <i>n</i> = 60)	6	10	4	13	23	9	9
T value	2.95	0.80	—	0.73	0.69	1.66	2.37
Two-tailed probability	0.004	0.425	—	0.469	0.491	0.100	0.019

Note.—Absence of air/fluid level or complete opacification in asymptomatic group precluded statistical comparison of that factor.



1



2

Fig. 1.—MR image, SE 2800/90, shows typical appearance of diffuse 2-mm rim of mucosal thickening bilaterally in maxillary sinuses in an asymptomatic patient.

Fig. 2.—MR image, SE 2800/90, shows maximum of 5 mm mucosal thickening in right maxillary sinus in a clinically symptomatic patient.



than cyclically, we think that our findings corroborate those of Zinreich et al. We have found that in the asymptomatic group, 63% of patients had minimal ethmoidal "abnormality," with 1–2 mm of mucosal thickening. That this finding was limited to the ethmoidal sinuses and that the ethmoidal sinuses are the only paranasal sinuses to undergo cyclical mucosal volume changes suggests a direct relationship between these points. Furthermore, Zinreich et al. [3] reported that on T2-weighted images, the hyperintensity of the nasal cycle was similar to that shown by inflammatory mucosa. Given these facts and the prevalence of this mucosal thickening in the asymptomatic population, we postulate that minimal, 1- to 2-mm areas of high T2 signal in the ethmoidal sinuses are a physiologically normal variant, a function of mucosal volume changes occurring in the nasal cycle. Conversely, only two (3%) of 68 asymptomatic patients had areas of ethmoidal mucosal thickening greater than 2 mm. Thus, this degree of thickening is not thought to be a function of normal physiologic responses. The physiologic ethmoidal mucosal edema may be diffuse or focal (Figs. 3A and 3B). It is commonly bilateral, suggesting that in the nasal cycle, the resolution of mucosal edema may be somewhat delayed, such that edema may persist on one side while the contralateral mucosa has already become edematous.

Sinusitis is a nebulous disease, with subjective symptoms that are commonly vague or nonspecific. Clinical history is essential in the assessment of sinus disease [4], but symptoms may not reflect the true state of the paranasal sinuses

[5]. Our study is limited in that we have relied strictly upon clinical history to categorize patients as symptomatic or asymptomatic. Although such a categorization is not definitive of a pathologic diagnosis, it is certainly clinically relevant because only such symptomatic patients would seek medical attention.

In comparing abnormalities between the asymptomatic and symptomatic groups, statistically significant results were obtained only in those patients with normal sinuses and in those with 4 mm or more of mucosal thickening. We are not suggesting that mucosal disease of 3 mm or less is not clinically significant; however, our results show that up to 3 mm of mucosal thickening may commonly be seen in asymptomatic patients. As such, findings on radiographs and MR images may not match clinical symptoms. Thus, clinical correlation is required rather than blanket medical therapy.

The absence of any cases of air/fluid levels or complete sinus opacification in the asymptomatic group precludes statistical comparison with the symptomatic group. However, on the basis of the four cases in the symptomatic group, we suspect that extrapolation to a larger study population would show this factor to be significant.

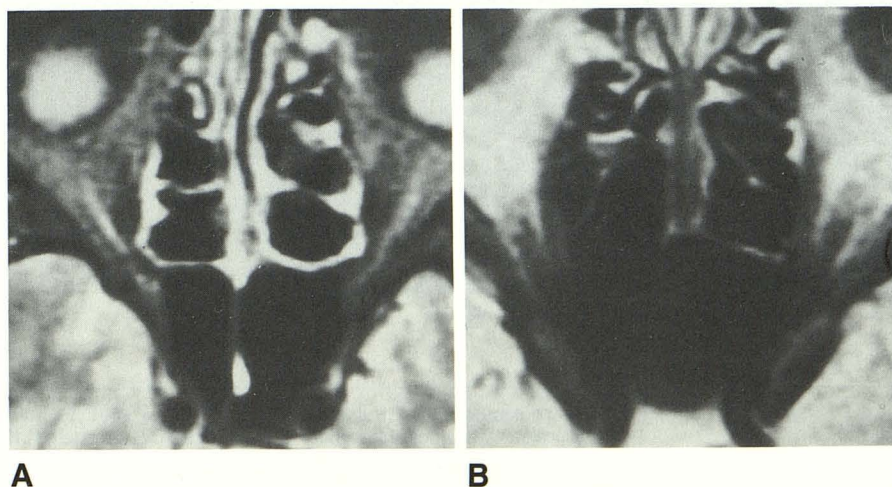
Retention cysts are due to obstruction and dilatation of a duct of a minor seromucinous gland. They are typically asymptomatic [4], and their comparable prevalence in our two populations was expected.

In conclusion, 1- to 2-mm areas of mucosal edema/thickening in the ethmoidal sinuses are thought to be a normal

**TABLE 2: Comparison of Asymptomatic and Symptomatic Groups with 1–2 mm of Mucosal Thickening in Ethmoidal Sinuses Classified as Normal**

	Normal	Maximal Mucosal Thickening			
		1 mm <sup>a</sup>	2 mm <sup>a</sup>	3 mm	≥4 mm
Asymptomatic ( <i>n</i> = 68)	44	11	7	4	2
Symptomatic ( <i>n</i> = 60)	24	5	13	9	9
T value	2.92	1.41	1.85	1.66	2.37
Two-tailed probability	0.004	0.160	0.066	0.100	0.019

<sup>a</sup> Exclusive of ethmoidal sinuses.



**Fig. 3.—A and B, MR images, SE 2800/90, show diffuse (A) and focal (B) mucosal edema in ethmoidal sinuses. Findings of this degree are thought to be physiologic. Both patients were asymptomatic.**

variant, due to the physiologic nasal cycle. With paranasal sinus inflammation, a significant difference in prevalence between symptomatic and asymptomatic patients is seen only with mucosal thickening of 4 mm or more. Although patients with less than 4 mm of mucosal thickening certainly may be symptomatic, our data suggest that this degree of abnormality is commonly not clinically significant. We intend to extend our study to a larger population to evaluate these findings further.

#### ACKNOWLEDGMENT

We acknowledge the advice and assistance of Janice L. Birney in the preparation of the questionnaire used in this study.

#### REFERENCES

1. Shapiro MD, Som PM. MRI of the paranasal sinuses and nasal cavity. *Radiol Clin North Am* **1989**;27:447-475
2. Havas TE, Motbey JA, Gullane PJ. Prevalence of incidental abnormalities on computed tomographic scans of the paranasal sinuses. *Arch Otolaryngol Head Neck Surg* **1988**;114:856-861
3. Zinreich SJ, Kennedy DW, Kumar AJ, Rosenbaum AE, Arrington JA, Johns ME. MR imaging of normal nasal cycle: comparison with sinus pathology. *J Comput Assist Tomogr* **1988**;12:1014-1019
4. Cummings CW, ed. *Otolaryngology—head and neck surgery*. St Louis: Mosby, **1986**:851-852, 1501-1502
5. Middleton E Jr, Reed CE, Ellis EF, Adkinson NF Jr, Yunginger JW, eds. *Allergy: principles and practice*. St. Louis: Mosby, **1989**:1295-1301