

# Generic Contrast Agents

Our portfolio is growing to serve you better. Now you have a *choice*.



FRESENIUS  
KABI

[VIEW CATALOG](#)

# AJNR

## **Evaluation of pachymeningitis by contrast-enhanced MR imaging in a patient with rheumatoid disease.**

W T Yuh, J M Drew, M Rizzo, T J Ryals, Y Sato and W E Bell

*AJNR Am J Neuroradiol* 1990, 11 (6) 1247-1248

<http://www.ajnr.org/content/11/6/1247.citation>

This information is current as  
of May 15, 2025.

## Evaluation of Pachymeningitis by Contrast-Enhanced MR Imaging in a Patient with Rheumatoid Disease

William T. C. Yuh,<sup>1</sup> Jack M. Drew,<sup>1</sup> Matthew Rizzo,<sup>2</sup> Tony J. Ryals,<sup>1</sup> Yutaka Sato,<sup>1</sup> and William E. Bell<sup>3</sup>

Symptomatic rheumatoid pachymeningitis is a rare extraarticular manifestation of rheumatoid arthritis. Clinical symptoms are nonspecific and diagnosis is frequently made by exclusion [1]. In a search of the literature we found only three cases diagnosed with radiologic examinations, including gallium scintigraphy, technetium scintigraphy, and CT [1–3]. We report a case of rheumatoid pachymeningitis evaluated by gadopentetate-dimeglumine-enhanced MR imaging.

### Case Report

A 57-year-old right-handed woman presented 6 weeks after the abrupt onset of a left frontal headache. The pain was characterized as daily, throbbing, and worse in the upright position; it was associated with nausea and vomiting. Her medical history was positive for rheumatoid arthritis (for more than 15 years) and hypercholesterolemia, and negative for problematic headaches. The patient was treated with antibiotics, for a presumed sinus infection, and Midrin, which produced no relief.

A lumbar puncture revealed an elevated protein level of 84 mg/dl, a glucose level within normal limits, no neoplastic cells, and 10 white blood cells—all mononuclear. EEG was normal. Plain films of both hands and cervical spine were consistent with changes of rheumatoid arthritis. CT evaluation showed a white matter lesion of the left frontal lobe of uncertain significance. MR demonstrated an old infarction consistent with the CT lesion.

The patient was referred to our institution for further diagnosis and treatment of continuing headaches. Physical examination was remarkable only for rheumatoid changes in the hands. Laboratory studies revealed an erythrocyte sedimentation rate of 8 mm/hr, normal levels of serum electrolytes, and an unremarkable chemistry profile including CSF, with the exception of a random cholesterol of 275 mg/dl. A repeat lumbar puncture again showed a mononuclear pleocytosis, no malignant cells, and no detectable  $\beta_2$  microglobulins. An angiogram to exclude cerebrovascular angitis was normal.

Gadopentetate-dimeglumine-enhanced MR scans (Figs. 1–3) revealed marked and uniform enhancement suggesting thickening and inflammation of dura.

Because of persistent symptoms and to further exclude the possibility of a vasculitis or meningeal tumor, the patient underwent a

right frontal craniotomy and biopsy, which revealed a thin layer of granulation tissue on the inner surface of the dura with a mild lymphocytic infiltration compatible with rheumatoid pachymeningitis. There was no histologic evidence of rheumatoid nodules. The diagnosis was rheumatoid pachymeningitis.

### Discussion

The frequency of rheumatoid arthritis in the general population of the United States is reported to be as high as 1.3% for men and 3.8% for women [4]. Although the extraarticular manifestations of rheumatoid arthritis are not uncommon, CNS involvement is rare [3]. Documented CNS manifestations of rheumatoid arthritis include spinal cord compression due to subluxation of the cervical vertebrae [3]; cerebral hemorrhage and papilledema possibly due to serum hyperviscosity associated with the elevated titers of circulating rheumatoid factors [3]; vasculitis [3]; and pachymeningitis [3] caused by both fibrinoid deposits and rheumatoid nodules [2]. The typical clinical course is one of long-standing, erosive, and seropositive disease with prominent extraarticular features [5]. While neurologic dysfunction accompanies a substantial number of these cases, the specific number of occurrences of rheumatoid pachymeningitis is difficult to determine owing to a lack of specific markers, short of biopsy [5]. In short, the diagnosis of rheumatoid pachymeningitis is one of exclusion. The delineation of useful radiologic markers depends on the correlation of pathologic and clinical data with the radiologic findings [1].

In a case reported by Beck and Corbett [3], a technetium-99m radionuclide brain scan demonstrated increased uptake over the convexities of both frontal lobes, and contrast CT showed abnormal meningeal enhancement and diffuse enhancement of the anterior frontal lobes. Biopsy demonstrated chronic inflammatory involvement of both the meninges and cortex.

Higgins and Marano [2] reported a case in which gallium imaging revealed abnormal, diffuse uptake at 24 hr in the

Received August 16, 1989; revision requested October 16, 1989; revision received November 16, 1989; accepted December 3, 1989.

<sup>1</sup> Department of Radiology, The University of Iowa College of Medicine, The University of Iowa Hospitals and Clinics, Iowa City, IA 52242. Address reprint requests to W. T. C. Yuh.

<sup>2</sup> Department of Neurology, The University of Iowa College of Medicine, Iowa City, IA 52242.

<sup>3</sup> Department of Pediatrics, The University of Iowa College of Medicine, Iowa City, IA 52242.



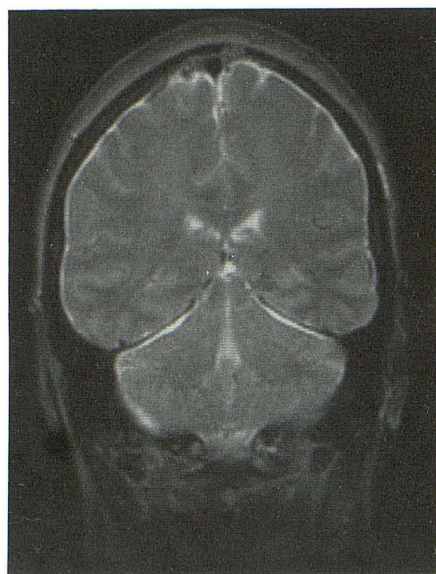


Fig. 1.—Coronal T2-weighted (2000/100) MR image shows diffuse meningeal abnormal signal throughout calvarium, including the tentorium.

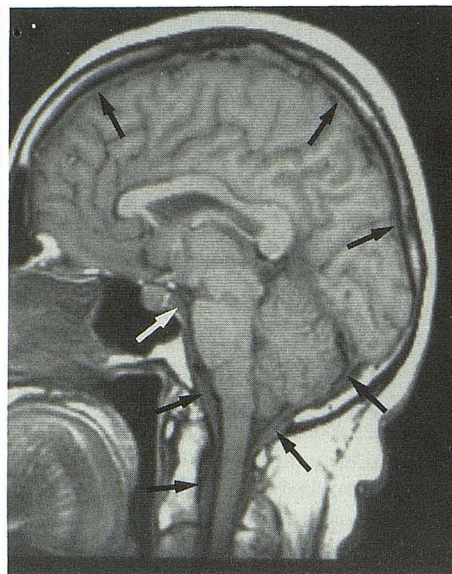


Fig. 2.—Sagittal T1-weighted (400/20) MR image shows diffuse thickening of dura and meninges (arrows) extending to preptine cistern, craniovertebral junction, and cervical region.

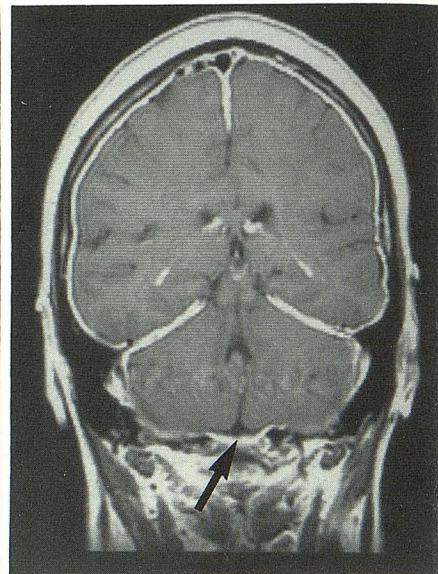


Fig. 3.—Coronal T1-weighted (600/20) gadopentetate-dimeglumine-enhanced MR image corresponding to Figure 1 shows diffuse enhancement of meninges. The abnormality is better demonstrated by contrast MR than by non-contrast MR (Figs. 1 and 2). Note enhancement near base of craniovertebral junction (arrow).

region of the tentorium cerebelli and the posterior aspect of the superior sagittal sinus. Abnormal gallium uptake is non-specific and can be seen in any inflammatory process. Thus, their results must be interpreted in light of both clinical and pathologic data. Studying the same patient, Allison and Marano [1] reported their CT findings, which included enhancement of the leptomeninges in the region of the tentorium. This enhancement was thought to be caused by increased vascularity, which may result from an inflammatory reaction or tumor [1].

Rheumatoid involvement of the dura mater is extremely rare, with only 14 cases documented in the 1984 literature review by Jackson et al. [5]. Although all these cases of dural involvement demonstrated rheumatoid nodules, these were autopsy studies in which the entire dura was examined [5]. The failure to discover rheumatoid nodules in our case may be explained by the limited specimen provided by dural biopsy.

In spite of the fact that rheumatoid nodules were not found in the dural biopsy, the clinical presentation and pathologic specimens were most consistent with rheumatoid pachymeningitis.

Recently, Martin et al. [6] reported CT and MR findings of hypertrophic pachymeningitis associated with various pathologic entities, which did not include rheumatoid arthritis. In our case, there was no evidence of the diseases mentioned by Martin et al.

In the three cases reported by Martin et al., the MR findings were nonspecific. The lesions were large and focal and, therefore, easily depicted by both noncontrast MR and contrast CT. Gadopentetate dimeglumine was not used in their MR studies. In our case, diffuse dural-meningeal enhancement was clearly demonstrated by contrast MR, whereas CT failed to show the abnormality. The beam-hardening artifact on CT most likely caused the poor visualization of the meningeal involvement.

In summary, rheumatoid pachymeningitis should be considered as a diagnostic possibility in the proper clinical setting when thickened dura with diffuse enhancement is found on contrast-enhanced MR images.

#### REFERENCES

1. Allison DJ, Marano GD. Computed tomography of rheumatoid pachymeningitis. *AJNR* 1985;6:976-977
2. Higgins WL, Marano GD. Gallium imaging of rheumatoid pachymeningitis. *Clin Nucl Med* 1985;5:350-351
3. Beck DO, Corbett JJ. Seizures due to central nervous system rheumatoid meningovascularitis. *Neurology* 1983;33:1058-1061
4. Robbins L, Cotran RS, Kumar V. *Pathologic basis of disease*, 3rd ed. Philadelphia: Saunders, 1984:1351
5. Jackson CG, Chess RL, Ward JR. A case of rheumatoid nodule formation within the central nervous system and review of the literature. *J Rheumatol* 1984;11:237-240
6. Martin N, Masson C, Henin D, Mompont D, Marsault C, Nahum H. Hypertrophic cranial pachymeningitis: assessment with CT and MR imaging. *AJNR* 1989;10:477-484