

Generic Contrast Agents

Our portfolio is growing to serve you better. Now you have a *choice*.



FRESENIUS
KABI

[VIEW CATALOG](#)

AJNR

Rare subependymal giant-cell astrocytoma in a neonate with tuberous sclerosis.

R D Tien, J R Hesselink and A Duberg

AJNR Am J Neuroradiol 1990, 11 (6) 1251-1252

<http://www.ajnr.org/content/11/6/1251.citation>

This information is current as
of May 14, 2025.

Rare Subependymal Giant-Cell Astrocytoma in a Neonate with Tuberous Sclerosis

The most common neonatal brain tumors are neuroectodermal tumors, mesenchymal tumors, and medulloblastomas [1]. Giant-cell astrocytomas associated with tuberous sclerosis in neonates have been reported only once before in the English literature [2]. We report the CT and MR findings in a neonate with tuberous sclerosis who had a large giant-cell astrocytoma.

Case Report

The patient was a full-term 3-day-old male infant. From birth, he had been lethargic and had had seizures. CT showed a large left frontal horn and mass in the foramen of Monro with left unilateral hydrocephalus and both subependymal and parenchymal nodules. The tumor and these nodules were hyperdense on unenhanced CT scans, and contrast-enhanced scans showed mild enhancement (Figs. 1A and 1B). MR the next day showed that the large intraventricular mass and subependymal and parenchymal nodules were hyperintense on T1-weighted images and hypointense on T2-weighted images (Figs. 1C and 1D). Stereotactic biopsy of the mass performed the next day showed a subependymal giant-cell astrocytoma (Fig. 1E). An echocardiogram performed later revealed an irregular mass attached to the intraventricular septum. A rhabdomyoma of myocardium (a common feature of tuberous sclerosis) was considered to be present even though no biopsy was performed. Clinical diagnosis of tuberous sclerosis was established. The patient's seizures have been well controlled. The most recent CT scan, done

3 months after the first scan, showed hydrocephalus; the size of the mass was unchanged. No shunting or further surgery has been planned at this time.

Discussion

Subependymal giant-cell astrocytoma is a common tumor in patients with tuberous sclerosis. This tumor usually is discovered in childhood; the average age of the patient at the time of diagnosis is 13 years. Although this tumor can be seen in early childhood, to our knowledge, only two neonates with tuberous sclerosis and giant-cell astrocytomas diagnosed soon after birth have been reported in the English literature [2]. Both infants reportedly died of cardiac arrhythmias associated with cardiac rhabdomyomas. The congenital onset of this tumor attests to the early embryonic origin of this disorder [2, 3].

In our patient, CT showed a high-density mass in the foramen of Monro and subependymal and parenchymal nodules that enhanced mildly after administration of contrast material. The mass and nodules had high signal intensity on T1-weighted MR images and low signal intensity on T2-weighted images. Hence, the differential diagnosis based on the MR signal intensities could include fat, intracellular methemoglobin [4, 5] and melanin [6]. The high-density mass seen on unenhanced CT scans essentially excludes a fatty tumor.

Microscopic examination showed large astrocytic cells with abundant cytoplasm and moderate, diffuse interstitial microscopic calcifi-

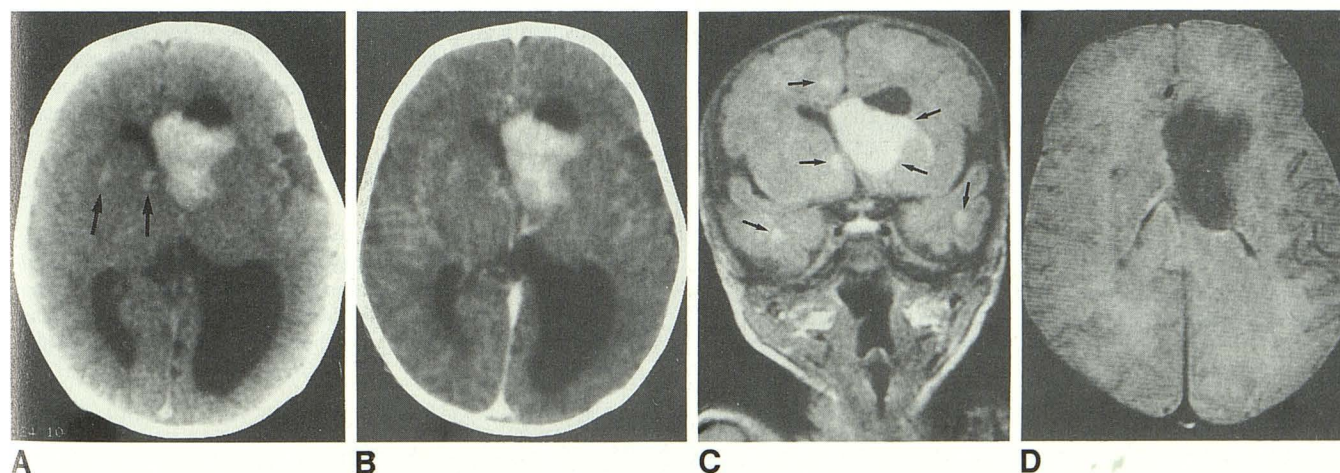


Fig. 1.—Subependymal giant-cell astrocytoma in a neonate with tuberous sclerosis.

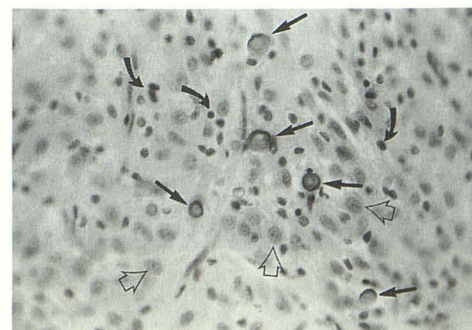
A, Unenhanced CT scan shows large, irregular, inhomogeneous high-density mass in region of left frontal horn and foramen of Monro with unilateral left-sided obstructive hydrocephalus. Small high-density nodules can be seen in right frontal subependymal and basal ganglion regions (arrows).

B, CT scan obtained after administration of contrast material shows mild enhancement of tumor but no significant enhancement of nodules.

C, Coronal T1-weighted MR image, 600/20, shows mass in foramen of Monro, right subependymal nodule, and right frontal and bilateral temporal lesions are hyperintense to brain tissue (arrows).

D, Axial T2-weighted MR image, 3000/80, shows mass in foramen of Monro is hypointense to brain tissue.

E, Photomicrograph of histologic section shows proliferation of large astrocytic cells with oval nuclei and abundant cytoplasm (open arrows). These cells are eosinophilic and stained positive for both glial fibrillary acidic protein and neurofilament. They lie within an eosinophilic fibrillary matrix that contains multiple microscopic calcifications (straight solid arrows) and small, round cells with rounded to oval nuclei and scanty cytoplasm (curved arrows), consistent with lymphocytes or neuroblasts. Diagnosis was subependymal giant-cell astrocytoma.



E

cations. No evidence of hemorrhage or melanin was present. The intensity of the tumor on unenhanced CT (range, 43–48 H) was not in the range of calcification, presumably because the tumor is not heavily calcified. Experimentally, different concentrations of calcium salt suspensions, varied states of hydration of the salts, and diverse constituents of the calcium salts in calcified tissues have given a range of MR signals [7] (Momoshima, unpublished data). The reasons are not fully understood, but possible explanations include hydration effects and a magnetic susceptibility gradient across the areas of calcification. We think the unusual shortened T1 and T2 relaxation times in this tumor most likely should be attributed to its calcium component.

Robert D. Tien
John R. Hesselink
Arthur Duberg
University of California, San Diego, School of Medicine
La Jolla, CA 92093

REFERENCES

1. Jellinger K, Sunder-Plossmann M. Congenital intracranial tumors. *Neuropädiatrie* 1973;4:46–63
2. Painter MJ, Pang D, Ahdab-Barmada M, et al. Congenital brain tumors in patient with tuberous sclerosis. *Neurosurgery* 1984;14:570–573
3. Russell DS, Rubinstein LJ, eds. *Pathology of tumors of the nervous system*. Baltimore: Williams & Wilkins, 1977:40–42
4. Gomori JM, Grossman RI, Goldberg HI, et al. Intracranial hematomas: imaging by high-field MR. *Radiology* 1985;157:87–93
5. Gomori JM, Grossman RI, Hackney DB, et al. Variable appearances of subacute intracranial hematomas on high-field spin-echo MR. *AJNR* 1987;8:1019–1026
6. Gomori JM, Grossman RI, Shields JA, et al. Choroidal melanomas: correlation of NMR spectroscopy and MR imaging. *Radiology* 1986;158:443–445
7. Dell LA, Brown MS, Orrison WW, et al. Physiologic intracranial calcification with hyperintensity on MR imaging: case report and experimental model. *AJNR* 1988;9:1145–1148