

Generic Contrast Agents

Our portfolio is growing to serve you better. Now you have a *choice*.



FRESENIUS
KABI

[VIEW CATALOG](#)

AJNR

Foix-Alajouanine syndrome.

G Di Chiro

AJNR Am J Neuroradiol 1990, 11 (6) 1286

<http://www.ajnr.org/content/11/6/1286.1.citation>

This information is current as
of May 14, 2025.

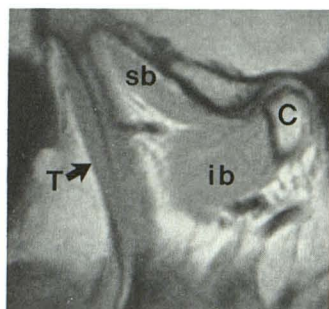


Fig. 1.—Correctly labeled masticatory muscles through medial aspect of temporomandibular joint. Sagittal, cephalometrically corrected, 3-mm-thick, proton-density MR image, 2200/20, through medial pole of mandibular condyle (C). Most medial aspect of temporalis muscle (T and arrow) is seen anterior to superior belly (sb) and inferior belly (ib) of lateral pterygoid muscle.

Journal of Roentgenology. Figure 1 with this reply shows the correct labeling.

Kurt P. Schellhas
Center for Diagnostic Imaging
Minneapolis, MN 55416

REFERENCES

- Schellhas KP. MR imaging of muscles of mastication. *AJNR* 1989;10:829-837, *AJR* 1989;153:847-855
- Schellhas KP, Wilkes CH, Fritts HM, Omlie MR, Heithoff KB, Jahn JA. Temporomandibular joint: diagnosis of internal derangements and post-operative changes. *AJNR* 1987;8:1093-1101, *AJR* 1988;150:381-389
- Harms SE, Wilk RM, Wolford LM, et al. The temporomandibular joint: magnetic resonance imaging using surface coils. *Radiology* 1985;157:133-136

Foix-Alajouanine Syndrome

The paper "Arteriovenous Fistulas of the Cervicomedullary Junction as a Cause of Myelopathy: Radiographic Findings in Two Cases" [1] states, "One [misprinted as once] possibility is that the dilated vessels have spontaneously thrombosed (Foix-Alajouanine syndrome)." The reader is left with the impression that Foix and Alajouanine described a syndrome characterized by thrombosis of the spinal cord vessels. Because no citation accompanies the statement, its origin remains in doubt. Possibly, the source is one of my articles on spinal cord arteriovenous malformations. For instance, a 1973 paper [2] written by Wener and me states, "Angiography has offered the definitive proof that the syndrome of Foix-Alajouanine . . . is merely an AV malformation in which the complication of bleeding or thrombosis has occurred." Similar statements are included in other articles by me on the subject.

Whether or not the account by Gaensler et al. [1] was based on one of my past "pronouncements," I think that the matter needs to be clarified. In their original report [3], Foix and Alajouanine emphasize that in their two cases no thrombosis was present: "Nous avons souligné enfin que . . . il n'y a pas thrombose dans nos cas . . ." Foix and Alajouanine considered the vascular component of the entity they reported to be a wall thickening, without luminal narrowing or obliteration of the cord vessels (arteries as well as veins). They addressed, and ruled out, the possibility of vascular malformations. Noting, however, that spinal dural arteriovenous fistulas were unknown then, this possibility remains sub judice.

Only quite recently, I actually read the Foix and Alajouanine contribution and found that these authors did not observe thrombosis or bleeding in the meticulous anatomopathologic studies of their two cases. I have been left wondering whether my misconception about the Foix-Alajouanine report was imparted by a teacher or some of my other readings. The lesson, for all of us, is that firsthand knowl-

edge of what was written by our predecessors should be a mandatory prerequisite of scientific reporting.

Giovanni Di Chiro
National Institutes of Health
Bethesda, MD 20892

REFERENCES

- Gaensler EHL, Jackson DE Jr, Halbach VV. Arteriovenous fistulas of the cervicomedullary junction as a cause of myelopathy: radiographic findings in two cases. *AJNR* 1990;11:518-521
- Di Chiro G, Wener L. Angiography of the spinal cord: a review of contemporary techniques and applications. *J Neurosurg* 1973;39:1-29
- Foix C, Alajouanine T. La myélite nécrotique subaiguë. *Rev Neurol* 1926:1-42

Editor's Note.—Dr. Di Chiro indeed has pointed out the pitfalls in quoting secondary sources. I think the following reply by Drs. Gaensler, Jackson, and Halbach not only is gracious but also points out enjoyable aspects of being able to consult original sources. Dr. Di Chiro obviously has been aware of these rewards for some time.

Reply

Dr. Di Chiro is correct in his assumption that we had depended on his [1, 2] and other more recent work, rather than Foix and Alajouanine's 1926 article [3]. We appreciate his efforts to finally set the record straight, as well his many notable contributions to the understanding of spinal vascular malformations. Although we share in his dismay over failing to consult the original source, the aim of our report was to highlight the need for thorough angiographic searches for spinal arteriovenous malformations rather than to clarify their pathophysiology. Dr. Di Chiro's observations nevertheless highlight the importance of reviewing both original and foreign-language sources.

It was an education to review Foix and Alajouanine's original 1926 description, with its painstaking clinical and pathologic correlation of two cases, which covers 42 pages. The level of understanding they achieved without the benefit of angiography and other tools developed subsequently is remarkable.

Erik H. L. Gaensler
Donald E. Jackson, Jr.
Van V. Halbach
University of California, San Francisco
San Francisco, CA 94143

REFERENCES

- Di Chiro G, Wener L. Angiography of the spinal cord: a review of contemporary techniques and applications. *J Neurosurg* 1973;39:1-29
- Wirth FP, Post KD, Di Chiro G, et al. Foix-Alajouanine disease: spontaneous thrombosis of a spinal cord arteriovenous malformation: a case report. *Neurology* 1970;20:1114-1118
- Foix C, Alajouanine T. La myélite nécrotique subaiguë. *Rev Neurol* 1926:1-42

Distance Between the Optic Chiasm and the Tuberculum Sellae

I would like to comment on the paper by A. J. Doyle [1] in the May/June 1990 issue of *AJNR* on the MR measurement of the distance between the optic chiasm and the tuberculum sellae. When MR imaging is used to make precise measurements of small anatomic structures, the use of thin sections is imperative. In my experience, the posterior limit of the normal optic chiasm between the anterior

inferior recesses of the third ventricle is a constant and reproducible finding both on MR and with previous methods of ventriculography and pneumoencephalography. Dr. Doyle comments that it was difficult using MR to define the chiasmatic point as described by Bull [2]. On routine sagittal series in which 3-mm sections and four signal averages are used, the chiasmatic point is well defined in nearly every patient who has no abnormalities in this area. The different experience of Dr. Doyle may be related to his use of 5-mm sections and only one excitation. When sagittal sections 3 mm thick are used, the chiasm is defined most accurately by looking at the three sections around the midline and selecting for measurement the section that shows the shortest distance between the chiasmatic point and the anterior border of the chiasm. On the other sections, both the optic nerve as it reaches the chiasm and the chiasm itself will be included, so measurement of the anteroposterior diameter of the chiasm would be falsely high. If the patient's head is not positioned perfectly, any obliquity in the sections will accentuate this difficulty further. The inaccuracy of this partial-volume effect will be much greater if 5-mm rather than 3-mm sections are used.

The observations of Dr. Bull are a valuable contribution that showed, for the first time in in vivo studies, that the optic chiasm is some distance above the osseous chiasmatic sulcus. The chiasm is positioned, in an age-dependent fashion, even higher and more anteriorly in children [3]. In 12 children less than 10 years old, Dr. Doyle found a mean chiasmal tuberculum distance of 3.3 mm, which was less than that of the mean distance for the adult male population and the mean distance of 3.8 mm for the combined male-female population. I think that measurements in a larger number of children might reveal both a significant difference between infancy and late childhood and a mean childhood measurement (in children less than 10 years old) that exceeds the measurement of the adult male and female population.

Taher El Gammal

*The University of Alabama at Birmingham
Birmingham, AL 35233*

REFERENCES

1. Doyle AJ. Optic chiasm position on MR images. *AJNR* 1990;11:553-555
2. Bull J. The normal variations in the position of the optic recess of the third

ventricle. *Acta Radiol* 1956;46:72-80

3. El Gammal T, Allen MB. *An atlas of polytome pneumography*. Springfield, IL: Charles C Thomas, 1977:29-142

Reply

Dr. El Gammal's points are well taken. Certainly, better anatomic definition would be expected when sections 3 mm thick are used, and I would have preferred to use this method if it had been possible in the situation in which I was working. One finding that encouraged me to think that my measurements of the chiasm were reasonably accurate was the similarity to Zander's anatomic measurements [1]. Furthermore, partial-volume effects would be expected to result in overestimation of the distance between the chiasmal point and the tuberculum sellae on MR. In the series I looked at, this distance was underestimated compared with Bull's results [2]. This further supports the presumption that radiologic magnification may have caused a consistent overestimation of the distance in Bull's study.

It certainly would be of value to perform more studies on children. As Dr. El Gammal mentions, I found a somewhat shorter distance between the optic chiasm and the tuberculum sellae in children less than 10 years old, but the number of subjects available to me in this age group was limited, making further analysis of the finding statistically dubious. It was my initial impression that the chiasm-tuberculum separation is proportionately greater in children and possibly varies in a systematic way with development. However, an adequate study of the age group would require larger numbers of subjects and higher resolution techniques than I was able to use.

Anthony J. Doyle

*University of Utah, School of Medicine
Salt Lake City, UT 84132*

REFERENCES

1. Zander R. Beitrage zur Kenntnis der mittleren Schadelgrube mit besonderer Berucksichtigung der Lage des Chiasma opticum. *Anat Anz* 1896;12:457
2. Bull J. The normal variations in the position of the optic recess of the third ventricle. *Acta Radiol* 1956;46:72-80

Letters are published at the discretion of the Editor and are subject to editing.

Letters to the Editor must not be more than two *double-spaced*, typewritten pages. One or two figures may be included. Abbreviations should not be used.

Material being submitted or published elsewhere should not be duplicated in letters, and authors of letters must disclose financial associations or other possible conflicts of interest.

Letters concerning a paper published in the *AJNR* will be sent to the authors of the paper for a reply to be published in the same issue. Opinions expressed in the Letters to the Editor do not necessarily reflect the opinions of the Editor.