



## Discover Generics

Cost-Effective CT & MRI Contrast Agents



FRESENIUS  
KABI

WATCH VIDEO

# AJNR

## Letters

*AJNR Am J Neuroradiol* 1991, 12 (5) 1023-1027  
<http://www.ajnr.org/content/12/5/1023.2.citation>

This information is current as  
of June 22, 2025.

## Letters

### Treatment of Arteriovenous Malformations

We read with great interest the paper by Dawson et al. [1] on combined treatment of arteriovenous malformations (AVMs) by embolization and stereotactic radiosurgery, and we would like to congratulate them for their efforts in the therapeutic approach to these lesions. Although we agree with the concept of using a combined approach, we do not recommend the same technical procedure. As discussed previously [2–4], embolization with particles is used optimally in the preoperative stage and mainly in neoplastic conditions that have a capillary barrier [3, 4]. Furthermore, permanent occlusion of the affected vessel cannot be expected with particles, and recanalization, even after dense packing with this material, is an almost constant finding on long-term follow-up [4]. Stable occlusion is being obtained now by using liquid agents such as *N*-butyl-2-cyanoacrylate (NBCA). These can be used in arteriovenous fistulas or malformations, and their use, although perhaps more challenging than the use of particles, is associated with low morbidity when administered by an experienced team.

If complementary treatment is mandatory and radiosurgery is chosen, the remaining target must be as small as possible, preferably less than 2.5 cm [5, 6]. It is easy to understand that this "bull's-eye" must be a stable remnant. Any revascularization of the supposed previously totally embolized territories would lead to incomplete treatment with all risks that this carries, especially in AVMs that have bled (cases 3, 6, and 7 in the study by Dawson et al. [1]). Furthermore, embolization with particles is transitory, so changes in the angioarchitecture of the AVM, and even worsening of the lesion, as happened in case 6, can be expected.

In conclusion, we stress that the combination of endovascular techniques and radiosurgery is a method of choice that should be considered for treatment of cerebral AVMs. We would only like to add that, on the basis of 15 years' experience with particle embolization and 10 years' experience with isobutyl-2-cyanoacrylate and NBCA, we think that embolization should be performed with definitive materials (NBCA) in order to obtain the best results, especially if the patient has intracranial bleeding and complete anatomic cure is mandatory. The facts that particles are easier to use and are used more widely do not make them a good agent. So far, in similar series, glue embolization has given the best results.

Georges Rodesch  
Pierre Lasjaunias

Hôpital Bicêtre, Université Paris Sud  
94275 Kremlin Bicêtre Cédex, Paris, France

### REFERENCES

1. Dawson RC III, Tarr RW, Hecht ST, et al. Treatment of arteriovenous malformations of the brain with combined embolization and stereotactic radiosurgery: results after 1 and 2 years. *AJNR* 1990;11:857–864
2. Berenstein A, Kricheff I. Catheter and material selection for transarterial embolization: technical considerations. II. Materials. *Radiology* 1979;132:631–639
3. Berenstein A, Kricheff I. Microembolization techniques of vascular occlusion: radiologic, pathologic, and clinical correlations. *AJNR* 1981;2:261–267
4. Lasjaunias P, Berenstein A. *Surgical neuroangiography*, vol. 2. *Endovascular treatment of craniofacial lesions*. New York: Springer-Verlag, 1987:25–29
5. Steiner L. Radiosurgery in cerebral arteriovenous malformations. In: Flamm E, Fein J, eds. *Textbook of cerebrovascular surgery*, vol. 4. New York: Springer-Verlag, 1986:1161–1215
6. Betti DO, Munari C, Rosler R. Stereotactic radiosurgery with the linear accelerator: treatment of arteriovenous malformations. *Neurosurgery* 1989;24:311–321

### Reply

We thank Drs. Rodesch and Lasjaunias for their kind attention to our paper [1] and for giving us the opportunity to discuss the relative efficacy of various embolic agents. Our paper's intent was to show the usefulness of a combined approach for treatment of intracranial arteriovenous malformations that are too large to be treated by radiosurgery alone. We did not intend this publication to advocate any one particular technique of embolization. In fact, it would be helpful to know the results obtained by colleagues who have used other embolic agents in conjunction with radiosurgery.

Some of the terminology in our colleagues' letter is confusing and potentially misleading. They state that "permanent occlusion" cannot be achieved with particles and that "stable occlusion" can be obtained with liquid agents. They also state that *N*-butyl-2-cyanoacrylate (NBCA) is a "definitive" material. In what sense is NBCA definitive? If Rodesch and Lasjaunias wish to imply that permanent occlusion of blood vessels can be reliably obtained with liquid adhesives, we refer them to several papers [2–4], including one [2] of which they are coauthors, on recanalization of vessels embolized with liquid adhesives. There is no question that all currently used embolic agents may fail, with subsequent recanalization.

No controlled clinical trial has been done that compares the relative efficacies of liquid adhesives vs particles with regard to occlusion of



cerebral vessels. Until such a trial has been performed, any statements about the relative usefulness of the two agents must be regarded as anecdotal (i.e., based on personal experience) and should not be construed as scientifically proved fact.

Robert C. Dawson III  
Vanderbilt University  
Nashville, TN 37232-2675

Robert W. Tarr  
Case Western Reserve University  
Cleveland, OH 44106

Stephen T. Hecht  
University of California, Davis  
Sacramento, CA 95817

Joseph A. Horton  
Charles A. Jungreis  
University of Pittsburgh  
Pittsburgh, PA 15213

that, with the history of interventional neuroradiology in the Soviet Union, scientists there have been involved in this area as well. Perhaps some of this work will be translated into English and become available to us to examine as to territories dilated, angiographic results, technical factors, and so forth. We might thus all benefit from Dr. Kadish's experiences. On the basis of Dr. Vitek's summary, I judge that such would be the case. Thanks to Dr. Vitek for pointing this out.

Phillip Purdy  
Southwestern Medical Center at Dallas  
Dallas, TX 75235-8896

*Editor's Note.*—The *American Journal of Neuroradiology* is a forum of international scope in neuroradiology. I certainly hope the thaw in East-West relations will prompt Dr. Kadish to share his experience in this emerging technology with his colleagues in Western Europe and North America. The Journal would welcome submission of such articles.

## REFERENCES

1. Dawson RC III, Tarr RW, Hecht ST, et al. Treatment of arteriovenous malformations of the brain with combined embolization and stereotactic radiosurgery: results after 1 and 2 years. *AJNR* 1990;11:857-864
2. Fournier D, Terbrugge K, Rodesch G, Lasjaunias P. Revascularization of brain arteriovenous malformations after embolization with bucrylate. *Neuroradiology* 1990;32:497-501
3. Rao VRK, Mandalam K, Gupta A, Kumar S, Joseph S. Dissolution of isobutyl 2-cyanoacrylate on long-term follow-up. *AJNR* 1989;10:135-141
4. Vinters HV, Lundie MJ, Kaufmann JCE. Long-term pathological follow-up of cerebral arteriovenous malformations treated by embolization with bucrylate. *N Engl J Med* 1986;314:477-483

## Angioplasty of Arteries in the Carotid Territory

With regard to the article by Purdy et al. [1], for historical accuracy, I want to point out that S. A. Kadish, the head of endovascular surgery at the Latvian Medical Institute, Riga, U. S. S. R., has published many articles and presented numerous lectures on percutaneous transluminal angioplasty of the intracranial segment of the internal carotid artery and its branches. Dr. Kadish has performed more than 100 of these interventions, most of them on the internal and middle cerebral arteries. He uses special balloon angioplasty catheters of different sizes and shapes that he makes himself. He has had approximately 5% complications in a series of 100 patients.

His first articles on intracranial percutaneous transluminal angioplasty date back to 1982. Unfortunately, none of his papers were published outside the Soviet Union, and only a few of his lectures were presented in Western Europe or the United States. I have identified six of Dr. Kadish's publications related to intracranial percutaneous transluminal angioplasty, all of which were published in 1987-1990 in Riga (Latvia), Tallin (Estonia), Jerevan (Armenia), or Leningrad.

Jiri J. Vitek  
University of Alabama at Birmingham  
Birmingham, AL 35233

## REFERENCE

1. Purdy PD, Devous MD Sr, Unwin DH, Giller CA, Batjer HH. Angioplasty of an atherosclerotic middle cerebral artery associated with improvement in regional cerebral blood flow. *AJNR* 1990;11:878-880

## Reply

I read with interest the letter from Dr. Vitek about the contribution of Dr. Kadish in the Soviet Union to the development of angioplasty techniques in arteries in the carotid territory. It comes as no surprise

## Xenon CT Scanning for Measurements of Cerebral Blood Flow

I read with interest the recent article by Good and Gur [1], who used computer simulations to evaluate the accuracy of cerebral blood flow (CBF) measurements made with xenon CT scanning. With the awareness that xenon itself alters CBF, the authors showed that for the particular protocol used in the computer model, the flow values calculated on the basis of a 5-min inhalation are not substantially affected by a 30-40% augmentation of CBF as long as the augmentation begins 1.5 min after the start of the study. Although this is certainly a step in the right direction, significant questions remain about the effect of xenon itself on flow values.

That xenon alters CBF has long been known, and recent work [2] has shown that velocities measured by using transcranial Doppler sonography change dramatically during the inhalation of xenon in concentrations commonly used for CT scanning. The velocities increased in 85% of a normal group 1.9 min after the onset of inhalation, rising to 38% above baseline levels. An augmentation of CBF induced by xenon has recently been confirmed by xenon-133 regional CBF studies [3]. In the computer simulation of Good and Gur, a corresponding behavior of CBF would not substantially affect the calculated flow values.

A problem with computer simulations is that specific simplifications must be assumed that ignore biological variability. For example, in the transcranial Doppler sonography study [2], 15% of the normal population showed a significant decrease in velocities in the middle cerebral arteries during xenon inhalation, in accordance with the known anesthetic effect of xenon. If xenon flow values are affected in a way suggested by these changes in blood-flow velocity, some subjects will show a small increase and some will show a small decrease in calculated flow values. The variability in these flow values that are due to the vasoactive effects of xenon can thereby be greatly magnified. Furthermore, the high variability of the time to onset of xenon flow activation ( $1.9 \pm 0.56$  min [SD]) implies an earlier activation for some patients than the 1.5-min constraint, which is critical in the computer model. The effects of the variability from either of these sources is not measured by the computer simulation of Good and Gur.

The situation is even worse for flow values of tissues that have pathologic changes. Although xenon reactivity and flow values of infarcted tissue are clearly zero, neither the magnitude nor the time course of xenon reactivity is known for living tissues with pathologic changes in the human brain. The amount of error due to xenon activation in these notoriously heterogeneous tissues is therefore completely unknown, and any xenon CT study of human tissue that



may seem to reflect pathophysiologic changes must be interpreted with great caution.

The numerous animal studies designed to correlate the results of xenon CT with the results of other techniques have not settled the issue. Many of these studies have used significantly higher concentrations of xenon or longer inhalation times than found in human protocols, so that the effect of xenon in these cases is unclear and, in fact, may decrease CBF. Furthermore, most of these studies have used only a handful of animals and have shown only a statistical correlation between xenon CT and other methods without addressing any actual agreement between the flow values. Systematic bias and high variability are therefore not reflected in the results, and many studies have reported a low correlation coefficient, which reflects a high variability. For example, analysis of graphic data found in a recent correlation study showed that 17 (57%) of 30 of the data points corresponded to xenon flow errors of more than 30%, despite good statistical correlation [4].

Animal studies are also confounded by the high variability in xenon reactivity between species, and results do not apply to human tissue. Unfortunately, despite tremendous anecdotal experience, we have no rigorous data that address the issue of flow value agreement in humans both for normal and for diseased brain.

Xenon CT scanning is a method of measuring CBF that itself changes flow, and so its quantitative use must be scrutinized. No computer simulation can capture the biological variability seen in the response times and magnitudes in a population, and no amount of parameter testing in a mathematical model can re-create the heterogeneous and largely unknown responses of diseased tissues to xenon. Although Good and Gur have shown a minimal effect of xenon in a restrictive computer model, they do not address these variabilities, nor do they address the significant proportion of xenon studies in which flow decreases. We have little knowledge of the effects of xenon on flow in human tissues with pathologic changes, and most of the correlative data are derived from small numbers of animals and show statistical correlation only. Because small changes in CBF in response to pharmacologic or physiologic changes are considered significant in clinical practice and in research, statistical correlation alone cannot suffice for clinical use. What is clearly needed is a quantitative comparison of flow values between xenon CT and a standard technique for both normal and abnormal tissue in humans. Although the xenon investigators should be applauded for having advanced xenon CT to a qualitative method for measuring CBF, the uncertainties mentioned here should prevent the acceptance of xenon CT as quantitative until such studies are performed.

Cole A. Giller  
Southwestern Medical Center at Dallas  
Dallas, TX 75235-8855

#### REFERENCES

1. Good WF, Gur D. Xenon-enhanced CT of the brain: effect of flow activation on derived cerebral blood flow measurements. *AJNR* 1991;12:83-85
2. Giller CA, Purdy P, Lindstrom WW. Effects of inhaled stable xenon on cerebral blood flow velocity. *AJNR* 1990;11:177-182
3. Hartman A, Dettmers C, Schuier FJ, Wassman HD, Schumacher HW. Effect of stable xenon on regional cerebral blood flow and the electroencephalogram in normal volunteers. *Stroke* 1991;22:182-189
4. Wolfson SK, Clark J, Greenberg JH. Xenon-enhanced computer tomography compared with [ $^{14}\text{C}$ ]iodoantipyrine for normal and low cerebral blood flow states in baboons. *Stroke* 1990;21:751-757

#### Reply

For several years, investigators and clinicians who used the xenon CT cerebral blood flow (CBF) washin protocol were puzzled by the

fact that consistent, robust, and reasonable flow values were routinely derived in such studies despite findings reported in the literature on CBF activation or deactivation during xenon inhalation [1]. The article by Giller et al. [1] states that "preliminary computer simulations assuming a rise in CBF during inhalation have confirmed the calculation of both significantly falsely high and low flow values for various choices of scanning times." Our results do not support this statement, nor did the results presented by Dr. Lindstrom, one of the coauthors of that article [1], during the International Conference on Stable Xenon/CT CBF in Orlando, FL, February 8-11, 1990 [2, 3].

We agree that significant alterations in flow may occur when xenon is inhaled at concentrations typically used in such studies. More importantly, these changes are likely to be patient-specific both in the time course and the amount of activation or deactivation. However, when appropriately selected scanning protocols are used for derivation of flow estimates, the resulting flow values quite accurately represent CBF at the time the study was started. We think that all three types of experiments—simulations, animal studies, and human studies—are important in this regard, and all three support the results we published based on simulation.

Walter F. Good  
David Gur  
University of Pittsburgh  
Pittsburgh, PA 15261-0001

#### REFERENCES

1. Giller CA, Purdy P, Lindstrom WW. Effects of inhaled stable xenon on cerebral blood flow velocity. *AJNR* 1990;11:177-182
2. Good WF, Gur D. Xenon-enhanced CT of the brain: effect of flow activation on derived cerebral blood flow measurements. *AJNR* 1991;12:83-85
3. Stringer WA. Commentary. Accuracy of xenon CT measurement of cerebral blood flow. *AJNR* 1991;12:86-87

#### Gadopentetate Dimeglumine-Enhanced MR Imaging of Spinal Dermal Sinus Tract

We read with interest the excellent article by Barkovich et al. [1] on MR evaluation of spinal dermal tracts in children. Recently, we saw a case of a spinal sinus dermal tract in which gadopentetate dimeglumine-enhanced MR imaging enabled us to make the correct diagnosis.

A 2-year-old boy had thoracic aplasia cutis congenita. Moving the head had always been painful. From the age of 16 months, the patient had had progressive neck pain and stiffness. He had had several episodes of high fever, and a subcutaneous abscess had developed at the level of T2, which had been treated surgically. Neurologic examination showed meningeal irritation and spasticity of both legs. Bladder and bowel functions were normal. Fever had abated, and CSF cultures were negative at this time.

Plain radiographs (not shown) of the thoracic spine showed fusion of the lamina of T1 and T2. MR imaging showed a dermal sinus tract at T3, seen as a linear structure of low signal intensity on sagittal T1-weighted images (Fig. 1A). The tract could be followed through the subcutaneous fat and posterior elements of the spine to the dura. The intraspinal portion of the tract was not visible. Gadopentetate dimeglumine-enhanced MR showed that the spinal tract ended in a soft-tissue mass with marked enhancement of signal intensity on T1-weighted images (Figs. 1B-1D). This soft-tissue mass extended caudally to the level of T5. Further MR examination of the entire spine did not show additional lesions, such as intra- or extradural tumors, thickened filum terminale, or abnormal position of the conus medullaris on images obtained before and after administration of gadopentetate dimeglumine.

The patient had dorsal laminectomy at the levels of T1 to T3. The



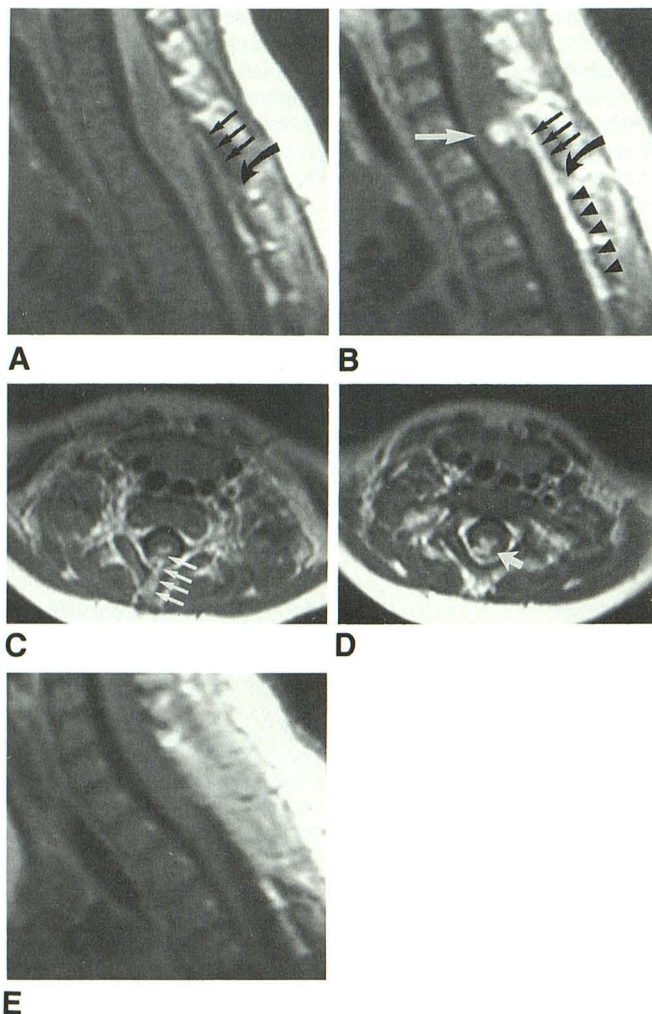


Fig. 1.—Spinal dermal sinus tract.

A, Sagittal T1-weighted MR image (500/30) of thoracic spine shows marked enlargement and low signal intensity of cervical cord from C4 to T1. Linear structure of low signal intensity extends cranially (straight arrows) from level of entrance of dermal sinus (curved arrow).

B–D, Sagittal (B) and transverse (C and D) contrast-enhanced T1-weighted MR images (500/30) show intradural part of dermal sinus tract as high-signal-intensity structure (B, small black arrows). Linear structure of high signal intensity originating from level of entrance of tract (B, curved arrow) and descending caudally represents adhesions (B, arrowheads). Tract ends in intramedullary dermoid tumor (B, white arrow). Transverse images show tract traversing the dura (C, arrows) and confirm intramedullary extension of dermal sinus tract into intramedullary dermoid (D, arrow).

E, Postoperative sagittal contrast-enhanced T1-weighted MR image (500/30) shows subtle residual enlargement of thoracic cord. Hyperintense intradural and intramedullary masses have been resected.

tract could be followed from the cutaneous lesion across the dura to the thoracic cord between the dorsal columns. The tract was removed totally with some difficulty because of adhesions caused by previous infections. On histologic examination, the diagnoses of sinus tract and dermoid tissue were confirmed. On postoperative MR examination, the diameter of the thoracic cord was normal, and there were no signs of enhancing dura or intramedullary lesions (Fig. 1E).

This case illustrates the advantages of gadopentetate dimeglumine-enhanced images in the detection of concomitant infection in

this type of dysraphy. As infection often occurs as a complication of spinal dermal sinus tracts, and these infections might occur without clinical signs and symptoms of meningitis, we suggest routine administration of gadopentetate dimeglumine in preoperative evaluation of spinal dermal sinus tracts.

Paul R. Algra  
Loes M. Hageman  
Free University Hospital  
Amsterdam, the Netherlands

#### REFERENCE

1. Barkovich AJ, Edwards MSB, Cogen PH. MR evaluation of spinal dermal sinus tracts in children. *AJNR* 1991;12:123–129, *AJR* 1991;156:791–797

#### Reply

I would like to compliment Drs. Algra and Hageman on their enlightened use of a paramagnetic contrast agent in the detection of a dermal sinus tract with associated infection. Indeed, it is well known that inflammation, such as that from repeated infections, induces the formation of granulation tissue [1]. It is equally well known that granulation tissue enhances significantly after administration of IV contrast material, because of considerable vascularity and lack of a blood-tissue barrier [2, 3]. Therefore, an infected dermal sinus tract, particularly a repeatedly infected one, will enhance dramatically after infusion of IV contrast material, as shown in the case reported by Drs. Algra and Hageman. However, I think it is premature to suggest that IV paramagnetic contrast agent should be administered to all patients with suspected dermal sinus tracts. Those patients who have not had infections as a result of bacteria seeping through the dermal sinus tract will not necessarily have contrast enhancement. Ideally, someone should perform a blinded study in which some patients with dermal sinus tracts are given paramagnetic contrast material and others are not. Only after a controlled study will we know whether the added expense of the paramagnetic contrast material is justified in patients with dermal sinus tracts.

A. James Barkovich  
University of California, San Francisco  
San Francisco, CA 94143-0628

#### REFERENCES

1. Harriman D. Bacterial infections of the central nervous system. In: Adams J, Corsellis J, Duchen L, eds. *Greenfield's neuropathology*, 4th ed. New York: Wiley, 1984:236–259
2. Enzmann D, Britt R, Yeager A. Experimental brain abscess evolution: CT and neuropathologic correlation. *Radiology* 1979;133:113–120
3. Enzmann D, Britt R, Placone R. Staging of human brain abscess by computed tomography. *Radiology* 1983;146:703–708

#### Hartnup Disease: MR Findings

Recently, we have examined a 6-year-old boy who 3 years earlier had had growth failure, hyperactivity, chronic diarrhea, intermittent ataxia, and weakness. Height and weight at that time were below the third percentile for his age, and developmental delay was present. The results of a muscle biopsy and a urine amino acid profile were consistent with Hartnup disease. MR of the brain (Figs. 1A and 1B) when the patient was 3 years old showed atrophy, delayed myelination, and dysgenesis of the corpus callosum. Follow-up MR when he



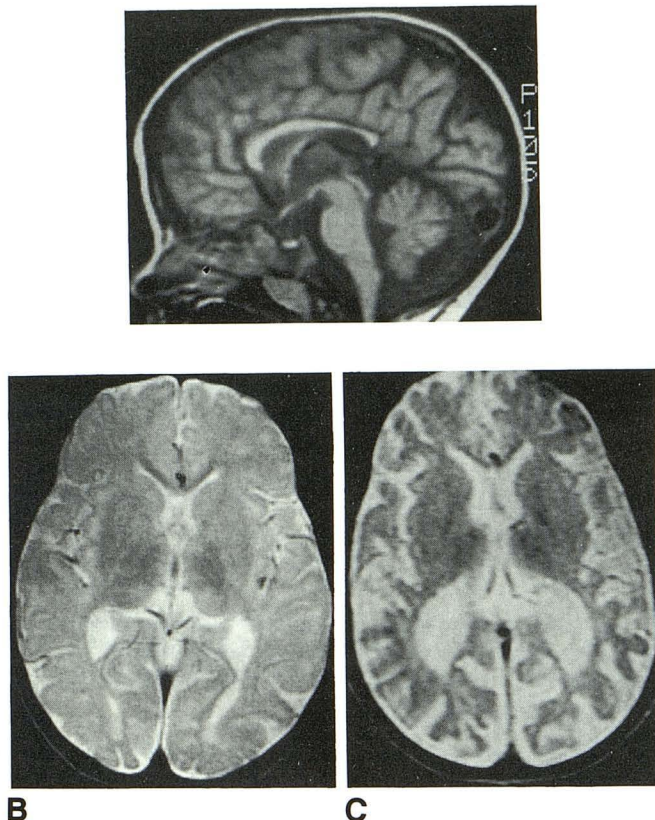


Fig. 1.—Hartnup disease.

A, Midline sagittal MR image (800/25/2) obtained when patient was 3 years old shows generalized atrophy. Corpus callosum is dysgenetic, rostrum is not seen, and splenium is thinned.

B, Axial MR image (2000/80/1) obtained at same time as A shows prominent extraxial spaces throughout brain. On this image, mature myelin is present in posterior limbs of internal capsules and in rostrum of corpus callosum. However, signal intensity of subcortical white matter is slightly increased with respect to gray matter, indicating delayed myelination. Fine arborization of subcortical white matter normally should be present by 24 months of age. Although cortical sulci appear somewhat flat in both posterior temporal regions, these findings were not present in any other image, and therefore a neuronal migration anomaly was not considered likely.

C, Axial MR image (2000/80/1) obtained 3 years after A and B shows progressive diffuse atrophy, which is slightly more prominent in both occipital regions. Lack of fine arborization of subcortical white matter is seen again, indicating delayed myelination.

was 6 years old showed progressive atrophy (Fig. 1C) despite adequate clinical response to treatment (oral tryptophan ethyl ester).

Hartnup disease occurs in approximately 1 in 30,000 live births [1]. Increased excretion of serin, alanine, valine, leucine, isoleucine, phenylalanine, tyrosine, tryptophan, and histidine in urine and feces is characteristic [2]. The affected persons may be asymptomatic (Hartnup disorder) or may have a wide range of signs and symptoms, including chronic diarrhea, ataxia, and generalized neuropsychiatric dysfunctions (Hartnup disease) [1]. Most patients with Hartnup disease also have a pellagralike illness. Because of this similarity, it has been postulated that the signs and symptoms of Hartnup disease are due mainly to tryptophan deficiency [1]. The reasons for the variability in the expression of the Hartnup genotype are unknown. Except for the absence of the pellagralike skin disorder, our patient's signs and symptoms fit the standard description. Pathologic examination in Hartnup disease shows brain atrophy, most prominent in the occipital lobes and cerebellum. The lateral geniculate ganglia may show gliosis, and wallerian degeneration can involve the optic nerves and tracts [2].

According to anecdotal reports [3], in one case of Hartnup disease, MR of the brain was normal. In our case, the late MR findings, although nonspecific, correlated well with the pathologic descriptions of this disease. However, to our knowledge, delayed myelination in Hartnup disease has not been reported. We think that differentiation from other metabolic and mitochondrial disorders is not possible on the basis of the MR findings alone. Despite satisfactory clinical response to treatment, our patient showed progressive atrophy on follow-up MR.

William Erly  
Mauricio Castillo  
David Foosaner  
Carmen Bonmati

University of Texas Medical School at Houston  
Houston, TX 77030

## REFERENCES

1. Scriver CR. Hartnup disease: a genetic modification of intestinal and renal transport of certain neutral amino acids. *N Engl J Med* 1965;273:530-535
2. Tahmoush AJ, Alpers DH, Feigin RD, et al. Hartnup disease: clinical, pathological, and biochemical observations. *Arch Neurol* 1976;33:797-807
3. Pomeranz SJ. *Craniospinal magnetic resonance imaging*. Philadelphia: Saunders, 1989:479

Letters are published at the discretion of the Editor and are subject to editing.

Letters to the Editor must not be more than two *double-spaced*, typewritten pages. One or two figures may be included. Abbreviations should not be used.

Material being submitted or published elsewhere should not be duplicated in letters, and authors of letters must disclose financial associations or other possible conflicts of interest.

Letters concerning a paper published in the *AJNR* will be sent to the authors of the paper for a reply to be published in the same issue. Opinions expressed in the Letters to the Editor do not necessarily reflect the opinions of the Editor.