



## Discover Generics

Cost-Effective CT & MRI Contrast Agents



FRESENIUS  
KABI

WATCH VIDEO

# AJNR

## Angiographic complications during stereotactic radiosurgery for cerebral arteriovenous malformations.

C A Jungreis, L D Lunsford and D Barker

*AJNR Am J Neuroradiol* 1992, 13 (3) 946-948

<http://www.ajnr.org/content/13/3/946.citation>

This information is current as  
of June 22, 2025.

# Angiographic Complications during Stereotactic Radiosurgery for Cerebral Arteriovenous Malformations

Charles A. Jungreis,<sup>1,2</sup> L. Dade Lunsford,<sup>1,2</sup> and David Barker<sup>1</sup>

**Summary:** The authors assess the complications and risks associated with stereotactic angiography compared with those encountered in routine cerebral angiography and judge them to be no greater.

**Index terms:** Angiography, complications; Arteriovenous malformations; Iatrogenic disease

During the past 20 years, stereotactic radiosurgery in the form of a multisource cobalt-60 gamma knife has been used to treat more than 1500 selected cases of intracranial arteriovenous malformations (AVMs) worldwide (1–5). Precise three-dimensional localization of the target volume is required for computer planning and radiation dose determination (6). Although either computed tomography (CT) or magnetic resonance (MR) imaging can be used for tumors, angiography is necessary for AVMs. Neither the stereotactic frame attached to each patient's head nor the adapter used for fixation of the headframe to the angiographic table is completely radiolucent (Fig. 1). Thus, at times during fluoroscopy the catheters and guidewires can be obscured, potentially increasing the complications. In order to assess this risk, we reviewed our 3-year experience in stereotactic angiography and compared it to our experience with routine diagnostic cerebral angiography performed over the same time period.

## Materials and Methods

We reviewed the records of 290 consecutive AVM patients who had cerebral angiography while in a headframe for the purpose of subsequent gamma knife radiosurgery. Ages ranged from 2 to 76 years (median age 34). We define cerebral angiography as any angiogram that has included a selective injection of at least one carotid or vertebral artery. Staff neuroradiologists, neuroradiology fellows, and closely supervised residents performed the studies. The angiographic technique has been described in detail (7).

Briefly, the patient is placed in a rectilinear stereotactic coordinate frame (Elekta Instruments, Tucker, GA) that is fixed to the outer table of the calvaria. A metal adapter interfaces the frame to the table. Angiography is performed in a standard fashion via femoral artery catheterization. Commercially available catheters and guidewires are used. Imaging is performed with a GE Biplane L-U Fluoroscopy unit with an MX-125 x-ray tube (GE Medical Systems, Milwaukee, WI).

In order to compare the stereotactic angiography complication rate to nonstereotactic cases, we also reviewed the records of 2141 patients having routine cerebral angiography during the same time period (July 1987 to October 1990).

## Results

During stereotactic angiography ( $n = 290$ ), three patients (1.03%) had vascular dissections (two internal carotid arteries and one vertebral artery). Two (0.69%) of the dissection patients remained asymptomatic and radiosurgery proceeded as planned. The third patient (carotid dissection) immediately became hemiplegic and aphasic (Fig. 2). Some recovery occurred over several minutes but significant deficits persisted. CT demonstrated the AVM, but no hemorrhage or edema was apparent. Conservative management resulted in resolution of the hemiparesis over the following week. At 2 months follow-up, no residual clinical deficit was detectable, although MR images demonstrated a small capsular infarct. The radiosurgery was not performed and the AVM remains untreated. No deaths have occurred in this series.

Over the same time period, we performed 2141 nonstereotactic diagnostic cerebral angiograms. In 10 patients (0.47%), arterial dissection of a craniocervical vessel occurred. These dissections ranged from a small subintimal contrast collection to complete vessel occlusion. One dissection re-

Received May 3, 1991; accepted and revision requested July 29; revision received August 14.

<sup>1</sup> Departments of Radiology and <sup>2</sup> Neurological Surgery, University of Pittsburgh School of Medicine, Presbyterian University Hospital, Pittsburgh, PA 15213. Address reprint requests to C. A. Jungreis, MD.

AJNR 13:946–948, May/June 1992 0195-6108/92/1303-0946 © American Society of Neuroradiology



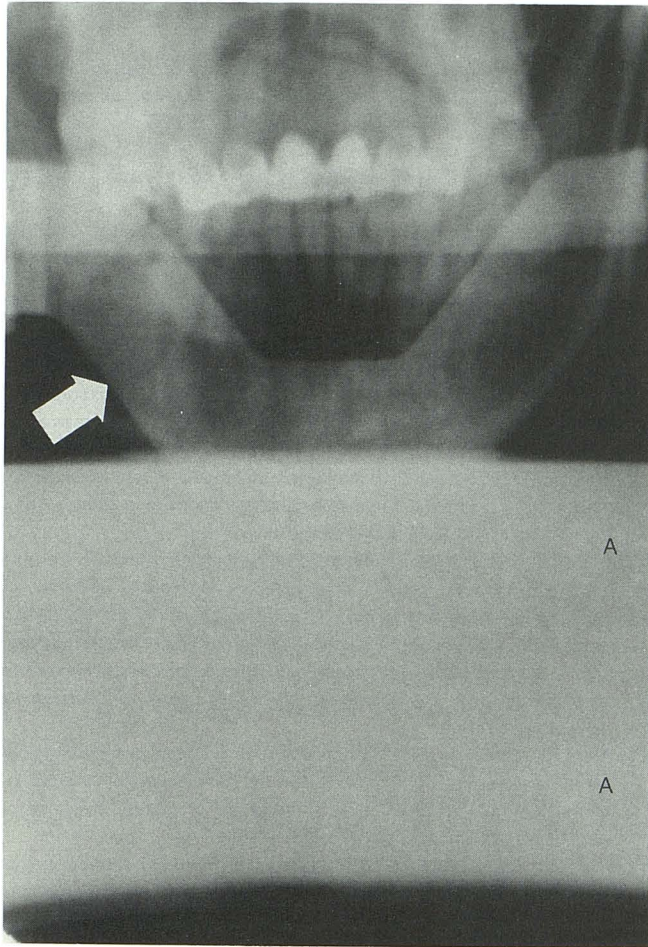


Fig. 1. Anteroposterior fluoroscopic image of a patient in a stereotactic headframe. The broad horizontal band of density (A) is the adapter used to secure the headframe to the angiography table. As a result, the catheter and guidewire may be obscured at times during fluoroscopy. Other dense bands (arrow) are parts of the headframe.

sulted in a transient neurologic deficit, one in a permanent deficit, and eight had no neurologic sequelae. Neurologic events occurred in patients without recognized dissections 12 times (0.56%). Eight (0.37%) had transient ischemic attacks. Two (0.09%) had reversible ischemic neurologic deficits, and two (0.09%) had permanent strokes. The total number of neurologic events whether or not a dissection was observed was 14 (0.65%). There have been no deaths. No peripheral vascular injuries or groin hematomas were significant enough to require surgical intervention. The overall incidence of neurovascular injury was 1.03%.

## Discussion

Complications of cerebral angiography include stroke, transient neurologic events, death, and

peripheral vascular injuries at the puncture site (8–13). Despite technical advances, risks still remain in the range of 5% or less. Any evaluation or procedure that includes angiography must include its risks as a component of the overall morbidity and mortality. As part of our quality control program, we periodically inspect our angiographic morbidity in order to identify factors responsible for unfavorable outcomes. In our experience, arterial dissection has been the most frequent complication from stereotactic angiography. In future cases, we will minimize fluoroscopic “blind spots” related to the headframe and fixation device by changing the angle of the tube, even though realignment of the tube with the headframe will require several extra minutes. If new frames and fixation devices could be constructed with radiolucent materials, they would offer an advantage in future cases. Also on the horizon is the refinement of MR angiography which might eliminate the risks of catheterization altogether. Currently, neither MR angiography nor standard MR imaging consistently provides sufficient anatomic detail to replace conventional angiography for stereotactic radiosurgery (recall that only the nidus of a vascular malformation, not feeding arteries or draining veins, is targeted).

The actual incidence of neurovascular complications is probably higher than we have observed

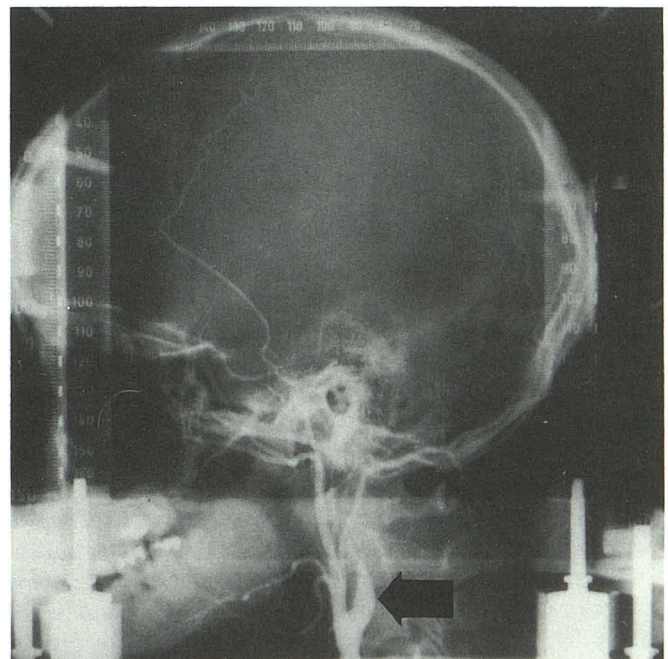


Fig. 2. Lateral view of a left common carotid artery angiogram with the patient in a stereotactic headframe. The internal carotid artery (arrow) has been dissected and is occluded 2 cm above its origin.



since dissections and intimal flaps may be asymptomatic. Also, some authors have observed small new foci of abnormal signal on MR images of the cerebral hemispheres obtained in patients immediately following angiography, the changes presumably representing subclinical infarcts from microemboli (14). We have had similar observations in two patients but these are not included in our data.

An interesting dilemma has been encountered in the management of the patients with neurologic sequelae from angiography in whom an AVM is also present, namely the benefit versus risk of systemic anticoagulation. We have not routinely anticoagulated patients suffering a vascular injury or neurologic deficit from angiography whether or not they have an AVM.

In conclusion, cerebral angiography performed as part of stereotactic radiosurgery poses no greater risk of neurovascular injury than does conventional angiography despite the visual limitations during fluoroscopy caused by the radioopaque portions of the headframe. Patients undergoing stereotactic radiosurgery for treatment of an AVM must understand there are relatively low acute risks inherent in angiography in addition to the delayed risks associated with the radiosurgery itself.

## References

1. Steiner L, Leksell L, Greitz T, et al. Stereotactic radiosurgery for cerebral arteriovenous malformations: report of a case. *Acta Chir Scand* 1972;138:459-464
2. Leksell L. Stereotactic radiosurgery. *J Neurol Neurosurg Psychiatry* 1983;46:797-803
3. Steiner L. Treatment of arteriovenous malformations by radiosurgery. In: Wilson CB, Stein BM, eds. *Intracranial arteriovenous malformations*. Baltimore: Williams and Wilkins, 1984:295-313
4. Steiner L. Radiosurgery in cerebral arteriovenous malformations. In: Fein JM, Flamm ES, eds. *Cerebrovascular surgery, vol IV*. New York: Springer-Verlag, 1985:1161-1251
5. Walton L, Bomflord CK, Bomflord CK, Remsden D. The Sheffield stereotactic radiosurgery unit: physical characteristics and principles of operation. *Br J Radiol* 1987;60:897-906
6. Lunsford LD, Flickinger J, Linder G, Maitz A. Stereotactic radiosurgery of the brain using the first United States 201 cobalt-60 source gamma knife. *Neurosurgery* 1989;24:151-159
7. Sadler LR, Jungreis CA, Lunsford LD, Trapanotto MM. Angiographic technique to precede gamma knife radiosurgery for intracranial arteriovenous malformations. *AJNR* 1990;11:1157-1161
8. Kerber CW, Cromwell LD, Drayer BP, Bank WO. Cerebral ischemia. I. Current angiographic techniques, complications, and safety. *Am J Roentgenol* 1978;130:1097-1103
9. Mani RL, Eisenberg RL, McDonald EJ, Pollock JA, Mani JR. Complications of catheter cerebral arteriography: analysis of 5000 procedures. I. Criteria and incidence. *Am J Roentgenol* 1978;131:861-865
10. Mani RL, Eisenberg RL. Complications of catheter cerebral angiography: analysis of 5000 procedures. II. Relation of complication rates to clinical and arteriographic diagnoses. *Am J Roentgenol* 1978;131:867-869
11. Mani RL, Eisenberg RL. Complications of catheter cerebral angiography: analysis of 5000 procedures. III. Assessment of arteries injected, contrast medium used, duration of procedure, and age of patient. *Am J Roentgenol* 1978;131:871-874
12. Dion JE, Gates PC, Fox AJ, Barnett HJM, Blom RJ. Clinical events following neuroangiography: a prospective study. *Stroke* 1987;18:997-1004
13. Grzyska U, Freitag J, Zeumer H. Selective cerebral intraarterial DSA: complication rate and control of risk factors. *Neuroradiology* 1990;32:296-299
14. Mamourian A, Drayer BP. Clinically silent infarcts shown by MR after cerebral angiography. *AJNR* 1990;11:1084