

Generic Contrast Agents

Our portfolio is growing to serve you better. Now you have a *choice*.



FRESENIUS
KABI

[VIEW CATALOG](#)

AJNR

Amaurosis fugax caused by a dural arteriovenous fistula from the ophthalmic artery.

L Xiong, J Li and J R Jenkins

AJNR Am J Neuroradiol 1993, 14 (1) 191-192

<http://www.ajnr.org/content/14/1/191>

This information is current as
of May 5, 2025.

Amaurosis Fugax Caused by a Dural Arteriovenous Fistula from the Ophthalmic Artery

L. Xiong,¹ J. Li,¹ and J. R. Jenkins^{1,2}

Summary: A 52-year-old man presented with transient monocular blindness that was both spontaneous and exacerbated by exertion. Dynamic orbital CT revealed a delay in the perfusion of the left optic nerve head suggestive of a steal phenomenon. Subsequent selective arteriography demonstrated an arteriovenous fistula between the falx artery originating from the ophthalmic artery and the superior sagittal venous sinus. In the proper clinical setting, a hemodynamic steal should be considered in the differential diagnosis of amaurosis fugax.

Index terms: Amaurosis Fugax; Arteries, ophthalmic; Fistula, arteriovenous

A variety of lesions interfering with the circulation of the orbit and causing transient monocular blindness have been reported (1–8). We report a case of vision loss secondary to an arteriovenous (AV) fistula involving the ophthalmic artery.

Case Report

A 52-year-old man presented with recurrent episodes of transient monocular left-sided incomplete vision loss of approximately 1 year's duration. The episodes occurred once or twice a week and were either spontaneous or exacerbated by exertion. No prior history of head trauma could be elicited. No absolute vision loss could be detected on formal vision testing, and the eye grounds were normal and symmetric in appearance on direct visual inspection. The remainder of the physical examination was normal. No bruits could be auscultated over the orbit.

Static orbital computed tomography (CT) scan showed that both optic nerves were of normal density and size. However, bolus intravenous contrast-enhanced dynamic CT revealed that the peak of the time-density curve acquired over the left optic nerve head area was delayed with reference to the right side (Fig. 1). Subsequent selective left internal carotid arteriography demonstrated a fistula between the ophthalmic artery and the rostral aspect of the superior sagittal sinus. The anterior falx artery, origi-

nating from the ophthalmic artery, emptied into the venous sinus and represented the site of the AV fistula (Fig. 2). The origins of the common carotid arteries, bifurcation, and siphons were angiographically normal. The patient refused surgical therapy and continued to be followed in clinic without further alteration of signs or symptoms in the short term.

Discussion

Amaurosis fugax affecting one eye has been reported in a variety of diseases such as migraine, Raynaud's disease, nonspecific arteritis, papilledema, optic disk protrusion, arteriovenous malformation, and atherosclerotic vascular disease. The pathophysiologic mechanism is a reduction in carotid perfusion pressure such as occurs from either occlusive carotid artery disease, anomalous origin of the ophthalmic artery, cranial arteriovenous shunts, or localized ischemic change such as that seen in carotid or ophthalmic artery stenosis/occlusion (1–8).

Normally, the ophthalmic artery arises as the first major intracranial branch of the internal carotid artery and pierces the dura from its anteromedial surface (9–11). The ophthalmic artery has a close relationship with the optic nerve and gives off numerous branches during its course. The falx artery arises from an anterior ethmoidal branch of the ophthalmic artery. It is a paired, slightly sinuous vessel running parallel to the inner table of the skull to supply the anterior portion of the falx cerebri (10, 12, 13).

Anastomoses of the ophthalmic artery have great significance in regard to function of the eye in pathologic states of the internal carotid artery (1, 12). Aberrant collateral pathways can result in reduced orbital blood flow. In the present case, hypothetically, there was a steal of blood from

Received February 20, 1992; accepted April 22, 1992.

¹ Neuroradiology Section, The University of Texas Health Science Center at San Antonio, San Antonio, Texas.

² Address reprint requests to J. Randy Jenkins, MD, Director of Neuroradiology, The University of Texas Health Science Center, 7703 F Curl Drive, San Antonio, TX 78284-7800.

AJNR 14:191–192, Jan/Feb 1993 0195-6108/93/1401-0191 © American Society of Neuroradiology

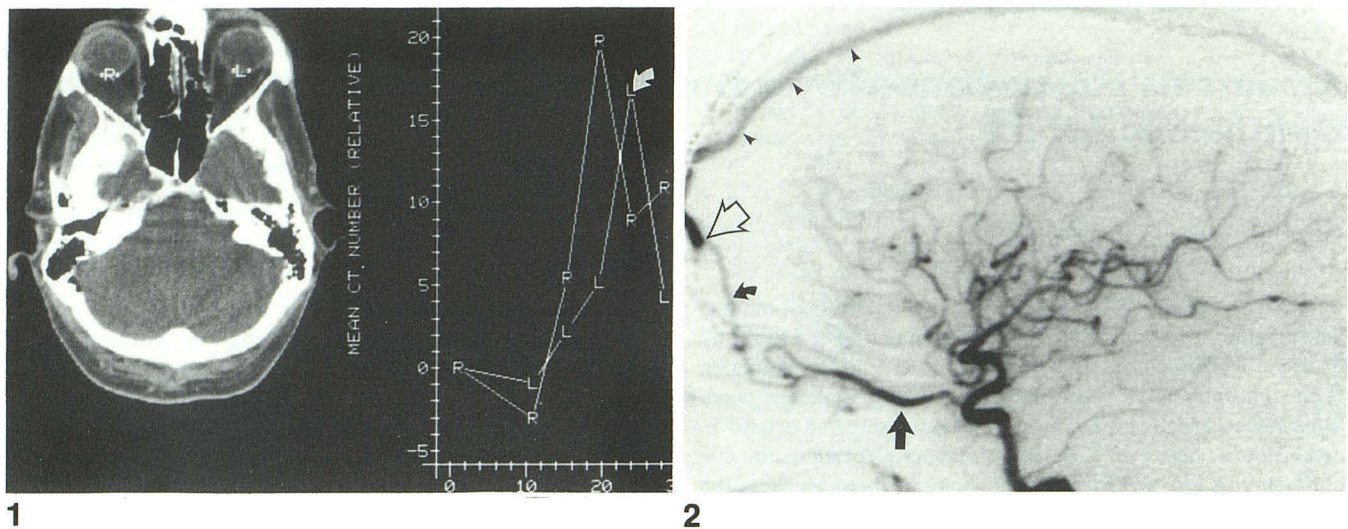


Fig. 1. Intravenous bolus contrast-enhanced dynamic orbital CT revealing a delay in the peak (arrow) of the time-density curve of the left optic head (L) as compared with the right (R).

Fig. 2. Lateral projection from arterial digital subtraction angiography of the left common carotid artery showing a slightly enlarged ophthalmic artery (straight arrow) feeding the prominent anterior falx artery (curved arrow). The point of the arteriovenous fistula (open arrow) is identified as well as the prominent early opacification of the anterior superior sagittal sinus (arrowheads).

the ophthalmic artery through the AV fistula that reduced the normal blood supply to the ocular tissues (Fig. 2). Amaurosis fugax as a result of an orbital hemodynamic steal in the face of an otherwise normal internal carotid artery is not common. Dural AV fistulae of the anterior cranial fossa are unusual (4), and blood supply to such fistulae from the anterior falx artery is rare. Pollock and Newton report that the anterior falx artery is normally visualized in 8.7% of subjects undergoing selective carotid arteriography, and might be enlarged in a variety of pathologic states including neoplasia, Paget disease, abnormal collateral circulation, meningitis, and arteriovenous malformations (12). As the current case represents an AV fistula emanating from a small branch of the internal carotid artery serving a clinically sensitive circulation, it represents a condition amenable primarily, if not solely, to direct surgical therapy.

Acknowledgment

We thank Joanne Murray for her help in preparation of the manuscript.

References

1. Grossman RI, Davis KR, Taveras JM. Circulatory variations of the ophthalmic artery. *AJNR* 1982;3:327-329
2. Weinberger J, Bender AN, Yang WC. Amaurosis fugax associated with ophthalmic artery stenosis: clinical simulation of carotid artery disease. *Stroke* 1980;11:290-293
3. Young LHY, Appen RE. Ischemic oculopathy: a manifestation of carotid artery disease. *Arch Neurol* 1981;38:358-361
4. Martin NA, King WA, Wilson CB, et al. Management of dural arteriovenous malformations of the anterior cranial fossa. *J Neurosurg* 1990;72:692-697
5. Weinberg PE, Patronas NJ, Kim KS, Melen O. Anomalous origin of the ophthalmic artery in a patient with amaurosis fugax. *Arch Neurol* 1981;38:315-317
6. Ehrenfeld WK, Lord RSA. Transient monocular blindness through collateral pathways. *Surgery* 1969;65:911-915
7. Levy JV, Zemek L. Ophthalmic arteriovenous malformation. *Am J Ophthalmol* 1966;62:971-974
8. Jinkins JR. "Papilledema": neuroradiologic evaluation of optic disk protrusion with dynamic orbital CT. *AJNR* 1987;8:681-690
9. Hayreh SS. Arteries of the orbit in the human being. *Br J Surg* 1963;50:938-953
10. Osborn AG. *Introduction to cerebral angiography*. Hagerstown, MD: Harper & Row, 1980:114-141
11. Hayreh SS, deRaad R. The ophthalmic artery. In: Newton TH, Potts DG, eds. *Radiology of the skull and brain: angiography*. St. Louis: Mosby, 1974:1333-1390
12. Pollock JA, Newton TH. The anterior falx artery: normal and pathologic anatomy. *Radiology* 1968;91:1089-1095
13. Kuru Y. Meningeal branches of the ophthalmic artery. *Acta Radiol Diagn* 1967;6:241-251