

Generic Contrast Agents

Our portfolio is growing to serve you better. Now you have a *choice*.



FRESENIUS
KABI

[VIEW CATALOG](#)

AJNR

Gadolinium enhancement of the leptomeninges caused by hydrocephalus: a potential mimic of leptomeningeal metastasis.

D J Schumacher, R D Tien and H Friedman

AJNR Am J Neuroradiol 1994, 15 (4) 639-641

<http://www.ajnr.org/content/15/4/639>

This information is current as
of May 15, 2025.

Gadolinium Enhancement of the Leptomeninges Caused by Hydrocephalus: A Potential Mimic of Leptomeningeal Metastasis

D. James Schumacher, Robert D. Tien, Henry Friedman

Summary: A patient had severe hydrocephalus and diffuse leptomeningeal enhancement on MR which mimicked leptomeningeal spread of a primary brain tumor. The leptomeningeal enhancement resolved completely after decompression of the hydrocephalus. Data suggest that the leptomeningeal enhancement is caused by vascular stasis induced by the hydrocephalus.

Index terms: Meninges, magnetic resonance; Hydrocephalus; Brain, magnetic resonance; Neoplasms, metastasis

Magnetic resonance (MR) with gadopentetate dimeglumine has been shown to be effective in delineating leptomeningeal spread of primary brain tumors and disseminated malignancies (1–3). Nevertheless, the finding of leptomeningeal enhancement is not specific for metastatic disease and can be found in other conditions, such as viral meningitis (2, 4), bacterial meningitis (2, 4), granulomatous meningitis (ie, fungal, tubercular, or sarcoid) (2, 4, 5), chemical meningitis (2), rheumatoid arthritis (6), eosinophilic granuloma (2), cerebral infarction (7–8), radiation necrosis (2), lymphoproliferative disorders (1, 3, 9, 10), subarachnoid hemorrhage (11), and agammaglobulinemia (12), and as a normal sequela of intracranial surgery (13). Thus, the radiographic diagnosis of leptomeningeal spread of tumor can be difficult and should always be corroborated with cerebrospinal fluid cytology and clinical history.

Case Report

A 20-year-old man presented with headaches and progressively blurry vision in his left eye. He denied seizures, nausea, vomiting, and focal neurologic symptoms and was treated for migraines. Ten months later he applied for a job which required an eye exam and at that time was found to have papilledema. MR imaging on a 1.5-T system revealed a large enhancing suprasellar mass (not shown) causing pronounced obstructive hydrocephalus. T1-weighted im-

ages (Fig 1) (700/15/1 [repetition time/echo time/excitations]), performed without flow compensation and after the administration of gadopentetate dimeglumine (0.1 mmol/kg), revealed subtle, diffuse leptomeningeal enhancement for which the patient had no known cause (ie, no history of surgery, shunt procedure, subarachnoid hemorrhage, or meningitis). Thus, the MR was interpreted as depicting a primary malignant brain neoplasm with leptomeningeal enhancement suggesting spread of tumor. Of note, however, is that the leptomeningeal enhancement pattern was linear and segmented.

A ventricular shunt procedure was performed 5 days later. At that time the intracranial pressure was noted to be increased (although not measured), and a subsequent biopsy of the suprasellar mass yielded a diagnosis of juvenile pilocytic astrocytoma. In the absence of further tumor-specific treatment, such as chemotherapy or radiation, two follow-up MR examinations performed 8 and 9 weeks later revealed complete resolution of the leptomeningeal enhancement (Fig 2). Cerebrospinal fluid cytologies were negative on two occasions, and after 8 months of follow-up there is still no evidence of leptomeningeal tumor.

Discussion

We believe the leptomeningeal enhancement in this case represents enhancement of meningeal blood vessels secondary to vascular stasis caused by the patient's hydrocephalus. Vascular stasis in the leptomeningeal microcirculation during hydrocephalus has been documented experimentally. Using direct visualization of the pial vasculature through calvarial windows, several investigators have shown dilatation of pial vessels and slowing of venous blood flow during periods of intracranial hypertension caused by hydrocephalus (14–17). Radionuclide blood flow experiments of intracranial hypertension have confirmed these results by showing a steady increase in cerebral blood volume with a constant net cerebral blood flow, thus indicating a stasis of

Received December 22, 1992; accepted pending revision February 19, 1993; revision received April 23.

From the Departments of Radiology (D.J.S., R.D.T.) and Pediatrics (H.F.), Duke University Medical Center, Durham, NC.

Address reprint requests to Robert D. Tien, MD, Department of Radiology, Duke University Medical Center, Box 3808, Durham, NC 27710.

AJNR 15:639–641, Apr 1994 0195-6108/94/1504-0639 © American Society of Neuroradiology

Fig. 1. *A and B*, Axial T1-weighted images (700/15/1), after the administration of gadopentetate dimeglumine (0.1 mmol/kg), demonstrate hydrocephalus (dilated lateral ventricles) and diffuse linear enhancement of the leptomeninges within the cortical sulci (arrowheads). (Precontrast T1-weighted images failed to reveal high signal intensity within the cortical sulci.) Flow compensation gradients, which can augment vascular signal, especially after contrast administration, were not used during image acquisition.

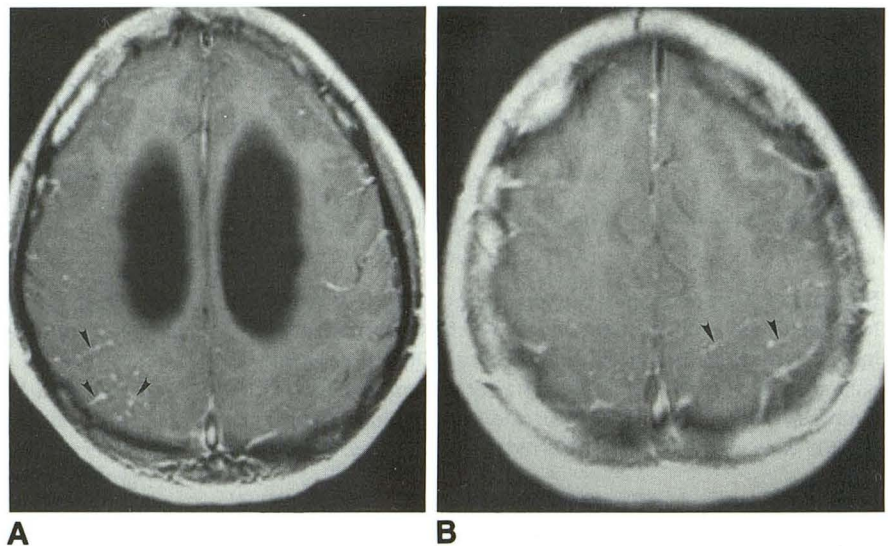
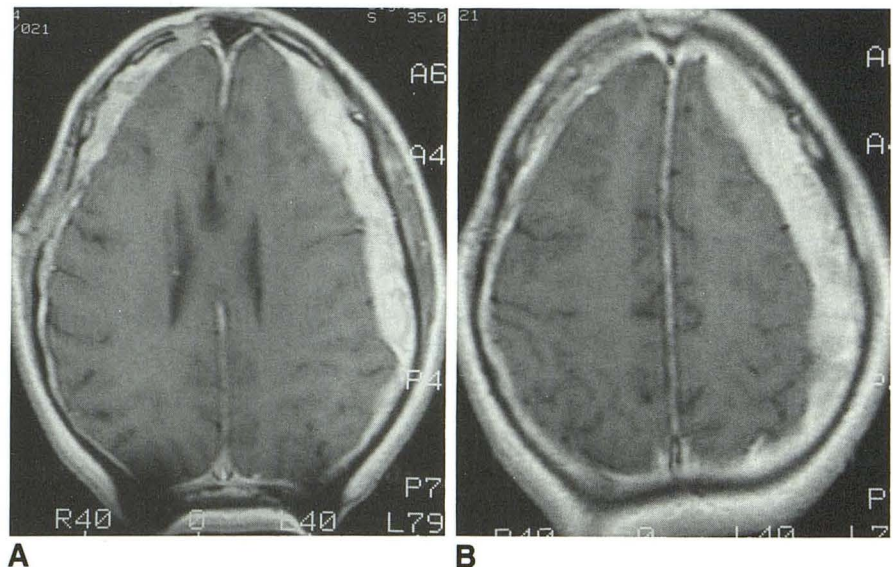


Fig. 2. *A and B*, Two months after shunting of the patient's hydrocephalus, and in the absence of tumor-specific therapy, repeat MR imaging (500/20/1) with the same dose of gadolinium as in Figure 1 reveals decompression of the lateral ventricles and resolution of leptomeningeal enhancement. Incidentally noted is the interval development of bilateral (left greater than right) subdural hematomas containing high-signal intensity methemoglobin.



blood within the cranium (18). In humans, the angiographic cerebral circulation time can be prolonged in patients with hydrocephalus, also suggesting vascular stasis (19).

If hydrocephalus can cause vascular stasis, how does this phenomenon lead to leptomeningeal enhancement? On spin-echo MR images, cerebral blood vessels typically appear as signal voids because of two dominant effects: the wash-out of saturated spins from the imaging section, and the dephasing of blood protons caused by turbulence (20). Elster and Moody (7) have postulated that, in the setting of slow flow, the T1-shortening characteristics of gadolinium, which increase net signal, predominate over the flow-related factors responsible for signal drop-out. As

an example, gadopentetate dimeglumine has been shown to enhance the arteries distal to occluded vessels during acute cerebral infarction (7-8). This enhancement coincides temporally with slowing of arterial blood flow (arteriolar-capillary block) and postinfarction vasodilatation. This same phenomenon of gadolinium enhancement of arteries has also been observed in focal cerebral arterial ectasia, in which slow flow has been documented angiographically (21).

Several arguments support our hypothesis that the leptomeningeal enhancement in the current case was caused by the patient's hydrocephalus. First, the enhancement resolved spontaneously after relief of hydrocephalus, in the absence of tumor-specific therapy. Second, two cerebrospi-

nal fluid cytologies and 8 months of follow-up have failed to reveal any evidence of leptomeningeal tumor. Third, the patient had no history to suggest one of the other known causes for non-malignant leptomeningeal enhancement, such as prior intracranial surgery, subarachnoid hemorrhage, or meningitis. Finally, the enhancing leptomeninges in this patient were not nodular, but rather appeared curvilinear as blood vessels do.

It is unclear why the phenomenon of leptomeningeal enhancement induced by hydrocephalus is not seen more frequently. Perhaps the degree of leptomeningeal enhancement is influenced by the duration, cause, or severity of the hydrocephalus. Certainly, one unusual feature of the case presented here is the long duration of the patient's symptoms, which suggested that the hydrocephalus was also long standing. Unfortunately, in this case the cerebrospinal fluid pressure was not measured, and the severity of the hydrocephalus is not known. It is also possible that certain patients with brain neoplasm, hydrocephalus, and leptomeningeal enhancement are presumed to have leptomeningeal tumor and are treated accordingly. If these patients are reimaged only after the ventriculostomy and tumor-specific therapy (ie, chemotherapy or radiation) have cured the leptomeningeal disease, then the credit for this might be falsely given to the tumor-specific therapy.

In patients undergoing MR examination for possible leptomeningeal spread of tumor, leptomeningeal enhancement does not always indicate tumor. In the presence of hydrocephalus, the finding of subtle, curvilinear, leptomeningeal enhancement without nodularity should be interpreted with extreme caution, because this finding may indicate vascular stasis. Therefore, it is prudent to repeat scanning in these patients after decompression of the hydrocephalus.

References

1. Sze G, Soletsky S, Bronen R, Krol G. MR imaging of the cranial meninges with emphasis on contrast enhancement and meningeal carcinomatosis. *AJNR Am J Neuroradiol* 1989;10:965-975
2. Phillips ME, Ryals TJ, Kambhu SA, Yuh WT. Neoplastic vs inflammatory meningeal enhancement with Gd-DTPA. *J Comput Assist Tomogr* 14:536-541
3. Lee Y-Y, Glass PJ, Geoffray A, Wallace S. Cranial computed tomographic abnormalities in leptomeningeal metastasis. *AJNR Am J Neuroradiol* 1984;5:559-563
4. Chang KH, Han MH, Roh JK, et al. Gd-DTPA enhanced MR imaging of the brain in patients with meningitis: comparison with CT. *AJNR Am J Neuroradiol* 1990;11:69-76
5. Sherman JL, Stern BJ. Sarcoidosis of the CNS: comparison of unenhanced and enhanced MR images. *AJNR Am J Neuroradiol* 1990;11:915-923
6. Bathon JM, Moreland LW, DiBartolomeo AG. Inflammatory central nervous system involvement in rheumatoid arthritis. *Semin Arthritis Rheum* 1989;18:258-266
7. Elster AD, Moody DM. Early cerebral infarction: gadopentetate dimeglumine enhancement. *Neuroradiology* 1990;177:627-632
8. Crain MR, Yuh WT, Greene GM, et al. Cerebral ischemia: evaluation with contrast-enhanced MR imaging. *AJNR Am J Neuroradiol* 1991;12:631-639
9. Schuknect B, Huber P, Bueller B, Nadjmi M. Spinal leptomeningeal Neoplastic disease. *Eur Neurol* 1992;32:11-16
10. Berns DH, Blaser S, Ross JS, Masaryk TJ, Modic MT. MR Imaging with Gd-DTPA in leptomeningeal spread of lymphoma. *J Comput Assist Tomogr* 1988;12:499-500
11. Sobel D, Li CF, Norman D, Norman TH. Cisternal enhancement after subarachnoid hemorrhage. *AJNR Am J Neuroradiol* 1981;2:549-552
12. Lerner EJ, Bilaniuk LT. Bruton-type (congenital X-linked) agammaglobulinemia: MR imaging of unusual intracranial complications. *AJNR Am J Neuroradiol* 1992;13:976-980
13. Burke JW, Podrasky AE, Bradley WG Jr. Meninges: benign postoperative enhancement on MR images. *Radiology* 1990;174:99-102
14. Wolffe HG, Forbes HS. The cerebral circulation: V. Observations of the pial circulation during changes in intracranial pressure. *Arch Neurol Psychiatry* 1928;20:1035-1047
15. Wright D. Experimental observations of increased intracranial pressure. *Aust N Z J Surg* 1938;7:215-235
16. Fog M. Influence of intracranial hypertension upon the cerebral circulation. *Acta Psychiatr Neurol Scand* 1933;8:191-198
17. Weinstein JD. Responses of cortical vessels to brain compression: observations through a transparent calvarium. *Surg Forum* 1967;18:430-432
18. Grubb RL, Raichle ME, Phelps ME, Ratcheson RA. Effects of increased intracranial pressure on cerebral blood volume, blood flow, and oxygen utilization in monkeys. *J Neurosurg* 1975;43:385-398
19. Greitz T. Cerebral blood flow in occult hydrocephalus studied with angiography and the xenon 133 clearance method. *Acta Radiol* 1969;8:376-384
20. Bradley WG Jr, Waluch V, Lai K-S, Fernandez EJ, Spalter C. Appearance of rapidly flowing blood on magnetic resonance images. *AJR Am J Roentgenol* 1984;143:1167-1174
21. Lazar EB, Russell EJ, Cohen BA, Brody B, Levy RM. Contrast-enhanced MR of cerebral arteritis: intravascular enhancement related to flow stasis within areas of focal arterial ectasia. *AJNR Am J Roentgenol* 1992;13:271-276