

Generic Contrast Agents

Our portfolio is growing to serve you better. Now you have a *choice*.



FRESENIUS
KABI

[VIEW CATALOG](#)

AJNR

Sinonasal esthesioneuroblastoma with intracranial extension: marginal tumor cysts as a diagnostic MR finding.

P M Som, M Lidov, M Brandwein, P Catalano and H F Biller

AJNR Am J Neuroradiol 1994, 15 (7) 1259-1262

<http://www.ajnr.org/content/15/7/1259>

This information is current as
of May 7, 2025.

Sinonasal Esthesioneuroblastoma with Intracranial Extension: Marginal Tumor Cysts as a Diagnostic MR Finding

Peter M. Som, Mika Lidov, Margaret Brandwein, Peter Catalano, and Hugh F. Biller

PURPOSE: To determine whether the MR finding of cysts along the intracranial margin of sinonasal esthesioneuroblastomas can be considered to suggest this tumor. **METHODS:** MR scans of 54 patients who had sinonasal lesions with intracranial extension were examined specifically for cysts along the intracranial margins of the lesions. **RESULTS:** Only 3 of the 54 patients had these cysts, and all 3 of these patients had esthesioneuroblastoma. Surgical pathologic findings of one specimen showed the cyst to be marginally located within the tumor. **CONCLUSION:** If cysts are seen on MR along the intracranial margin of a sinonasal mass, this finding highly suggests esthesioneuroblastoma.

Index terms: Esthesioneuroblastoma; Nose, magnetic resonance

AJNR Am J Neuroradiol 15:1259-1262, Aug 1994

Radiologists often seem on a constant quest to give histologic diagnosis for disease seen on sectional imaging studies. Rarely can this be accomplished. However, sometimes the presence of one or more imaging findings can allow the radiologist to offer a histologic diagnosis that has a very high degree of reliability. With this aim in mind, we examined the imaging studies of 54 patients who had sinonasal masses with extension into the anterior cranial fossa. Specifically, we were interested in a group of patients who had esthesioneuroblastoma, or olfactory neuroblastoma, an uncommon tumor that arises primarily in the nasal fossa. Extension of this tumor into the paranasal sinuses occurs in about 40% of patients, and gross intracranial spread occurs in about 30% of cases (1). In adults, some of these tumors are histologically confused with anaplastic carcinomas, large-cell lymphomas, extramedullary plasmacytomas,

amelanotic melanomas, and embryonal rhabdomyosarcomas (2). All of these neoplasms are undifferentiated, small-cell tumors, and like esthesioneuroblastoma can occur in the nasal fossa, with spread to the paranasal sinuses and anterior cranial fossa. Electron microscopy and histochemical testing are required to establish a definitive diagnosis (3).

Initially, there was hope that radiologists could differentiate these lesions on sectional imaging. Unfortunately, both the computed tomographic and magnetic resonance (MR) findings of the malignant tumors are usually nonspecific and rarely can be used to establish a definitive diagnosis (4, 5). The only finding that has been reported as suggesting esthesioneuroblastoma is the presence of calcifications within the lesion (6). However, because such calcification frequently cannot be distinguished from residual bone, which may be present in all of these lesions, it is difficult to refer to such calcification as being characteristic of this lesion (7).

In addition, all of the noncarcinomatous tumors in this group tend to remodel adjacent bone around them, whereas anaplastic carcinoma usually causes rapid bone destruction (3). However, there is still sufficient overlap in the type of bone reaction that it cannot reliably be used to establish a specific diagnosis.

We have seen three cases of esthesioneuroblastoma that had intracranial extension with

Received August 18, 1993; accepted pending revision October 6; revision received October 14.

From the Departments of Radiology (P.M.S., M.L.), Otolaryngology (P.M.S., P.C., H.F.B.), and Pathology (M.B.), Mount Sinai School of Medicine, City University of New York.

Address reprint requests to Peter M. Som, MD, Department of Radiology, Mount Sinai Hospital, Box 1234, One Gustave Levy Pl, New York, NY 10029.

AJNR 15:1259-1262, Aug 1994 0195-6108/94/1507-1259

© American Society of Neuroradiology

tumoral cysts at the margins of the intracranial disease. These cases are reported and reviewed with regard to these cysts' representing an imaging finding that may be highly suggestive of esthesioneuroblastoma.

Materials and Methods

Our files were searched for MR examinations of patients with sinonasal lesions that had intracranial extension. A total of 54 cases were found representing 25 malignancies (6 different tumors), 16 cases of polyps or fungal disease, 8 cases of benign fibrous lesions, 3 cases of anterior fossa meningiomas that extended into the sinonasal cavities, and 2 cases of angiofibroma. A breakdown of these 54 cases follows.

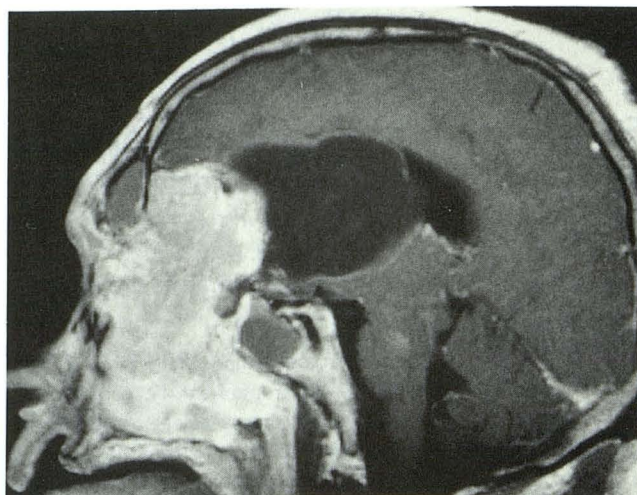
Malignant tumors (n = 25)	
Squamous cell carcinoma	1
Esthesioneuroblastoma	5
Marginal cysts	3
Adenocarcinoma	2
Melanoma	1
Large-cell lymphoma	1
Hemangiopericytoma	1
Polyps and mucocoeles	16
Benign fibrous lesions (n = 8)	
Fibrous dysplasia	4
Ossifying fibroma	3
Cementifying fibroma	1
Meningioma	3
Angiofibroma	2

Because we work at a referral center, many of our patients come for consultation already having been evaluated with sectional imaging studies. As such, there were a number of different MR scanners used, with a variety of scan protocols. The images shown represent this case material (Figs 1–3). All cases had either biopsy or postoperative pathologic confirmation.

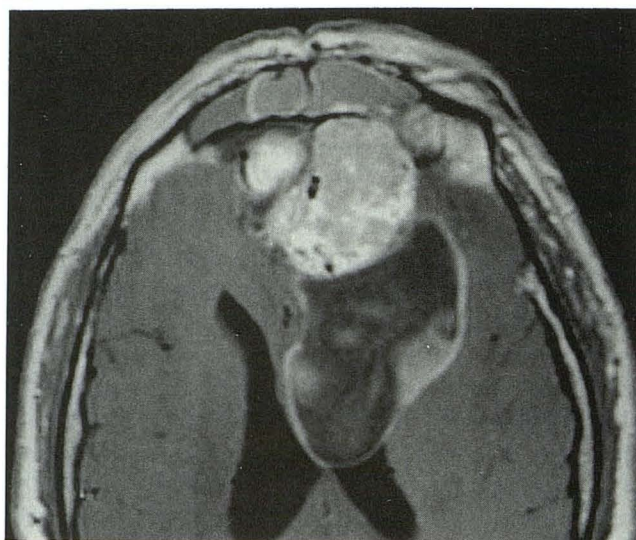Results

The only patients who had cystic lesions at the margins of the intracranial tumor components were three of the five with esthesioneuroblastoma. No other lesions were identified that had such cysts. The broadest base of the cysts was along the tumor margin. With all of the tumors in this study, there was a nonspecific generalized variable enhancement on MR. Elements of bone destruction were present in all cases, although there was also some bone remodeling in the noncarcinomatous cases. Because only MR studies were evaluated, no comment was made regarding the presence of small calcifications within the masses.

Pathologic examination in one case (Fig 1) showed that the tumor was composed of anas-



A



B

Fig 1. A, Sagittal T1-weighted (600/15 [repetition time/echo time]) postcontrast MR scan shows a large enhancing paranasal sinus and nasal cavity mass that has extended into the anterior cranial fossa. The tumor has eroded the floor of the frontal sinuses, entrapping secretions within them. Similarly, the anterior wall of the sphenoid sinuses has been destroyed by the lesion, trapping secretions within these sinuses. There is a 6-cm low-signal-intensity cystic region on the dorsal surface of the intracranial portion of the tumor, which invades the brain and left lateral ventricle. The margin of the cyst adjacent to the tumor is convex inward to the cyst, and there is a thin enhancing cyst rim.

B, Axial T1-weighted (760/20) postcontrast MR scan shows the intracranial portion of the tumor, the dorsally positioned cyst with its thin enhancing rim, and the obstructed frontal sinuses. The cyst contents are nonhomogeneous and of a higher signal intensity than the cerebrospinal fluid.

tomosing islands of "small blue round cells," and numerous rosettes and pseudorosettes were present. Cytologically, the nuclei were grade II, with prominent nucleoli, mild pleomor-

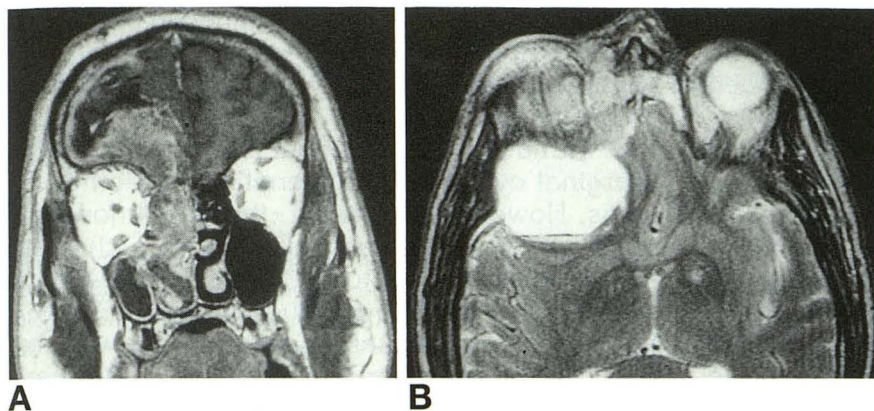


Fig 2. A, Coronal T1-weighted (500/13) postcontrast MR scan shows a recurrent nonhomogeneously enhancing right nasal cavity and ethmoid sinus mass that extends into the right anterior cranial fossa and obstructs the right maxillary sinus. Along the intracranial margin of the lesion, there is a low-signal-intensity cyst that has a thin enhancing rim. The border of the cyst adjacent to the tumor is convex inward to the cyst.

B, Axial T2-weighted (3000/102) MR scan shows the high-signal-intensity cyst with a fluid-fluid/debris level.

phism, and occasional mitoses. Occasional laminated calcifications were also seen. Histologically, the cyst contents consisted of hemorrhage, degenerated mucoid material, and tumor. The cyst wall was not a true cyst lining, but rather was composed of compressed malignant cells and fibrous tissue. The diagnosis was esthesioneuroblastoma with a marginal tumor cyst.

Because a similar appearance of the cyst contents was seen on the MR in one other case (Fig 2), the cyst's contents were most probably similar to those of case 1, and thus were also necrotic tumor. In both of these cases, the tumor had invaded the brain, becoming intraaxial. In the remaining case on MR (Fig 3), the con-

tents of the cysts were closer to cerebrospinal fluid in appearance, and the intracranial mass was also intraaxial.

Discussion

There is a constant desire on the part of both radiologists and clinicians to establish a histologic diagnosis based on the sectional imaging findings. This is especially true with regard to malignancies. Strangely, this desire to make such an "early" diagnosis persists despite general concession that only the pathologist can make the final diagnosis. Unfortunately, each such imaging effort has been met with some degree of frustration, because no one finding is

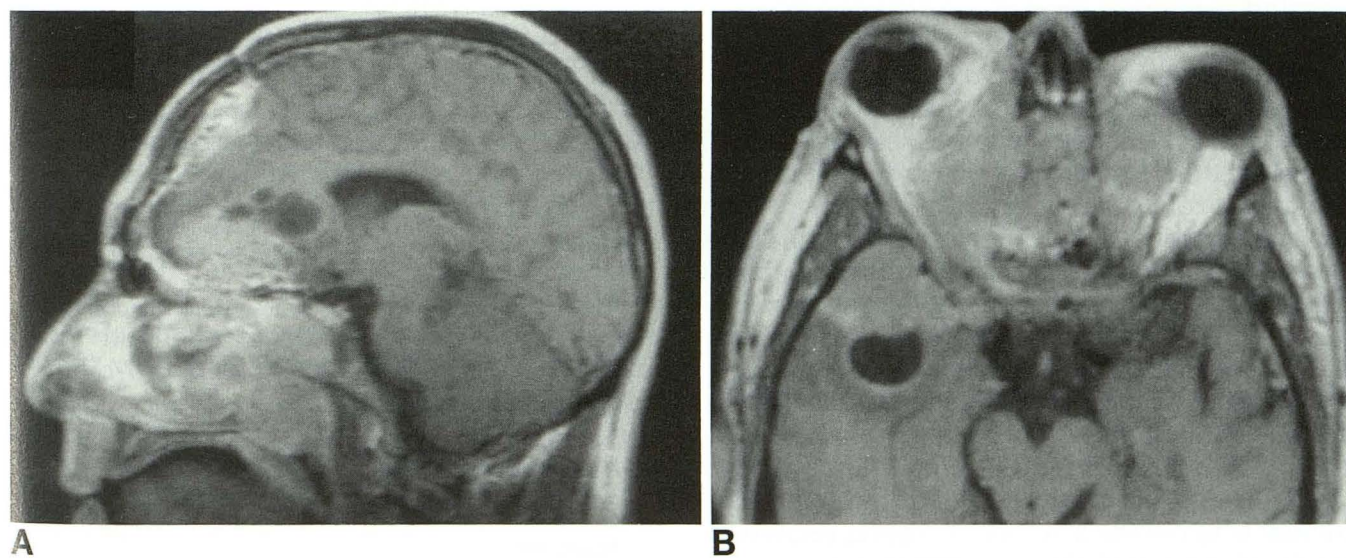


Fig 3. A, Sagittal T1-weighted (350/27) postcontrast MR scan shows a recurrent tumor in the paranasal sinuses, nasal cavity, and anterior cranial fossa. The patient had a prior craniofacial resection. Along the cranial tumor margin, several small low-signal-intensity cysts are present. They have a slightly higher signal intensity than the cerebrospinal fluid.

B, Axial T1-weighted (550/27) postcontrast MR scan shows a low-signal-intensity cyst along the intracranial tumor margin. The border of the cyst adjacent to the tumor is convex inward to the cyst; the cyst has a thin enhancing rim, and its contents have a signal intensity close to that of the cerebrospinal fluid.

unique to a specific tumor (4, 5). Although in this regard the degree of enhancement and the type of adjacent bone involvement have been helpful findings, they still are sufficiently non-specific that a definitive histologic diagnosis is usually not possible based on the images.

Three cases had cysts at the intracranial margins of esthesioneuroblastomas. The major considerations for the tissue composing the walls of these marginal cysts were arachnoid and tumor. In the only case in which a pathologic sample of the cyst wall was obtained, the wall was tumor, and the cyst content was necrotic tumor debris. Because a similar MR appearance was noted in one other case, one might assume that this patient also had marginal tumor cysts. In the third case, either marginal tumor cysts or arachnoid cysts could account for the MR appearance.

An arachnoid cyst associated with an acoustic neuroma has been observed (8). However, the precise reason for this association is not known, and none of the proposed theories clearly addresses the development of an arachnoid cyst adjacent to an extraaxial mass, such as an acoustic neuroma, an esthesioneuroblastoma, a meningioma, and possibly pneumosinus dilatans (9-12).

The only pathologically documented cyst in this study was a marginal tumoral cyst in a patient undergoing surgical resection for attempted cure at the time of initial tumor presentation. A pathologic sample of the intracranial component was not obtained in two cases (Figs 2 and 3), because these patients had large, incurable recurrences. Whatever the cause of the cysts, their occurrence seems to be uncommon.

Another point to consider is that all three of the cases of esthesioneuroblastoma with these cysts were very large lesions. It is thus possible that this tumor had to attain this considerable size before these cysts could develop. However, comparison with the other cases in this study showed that virtually all of the sinonasal masses that invaded the anterior cranial compartment could be considered large lesions. Thus, it is unclear whether the size of the mass is related to the development of these marginal cysts. Comparably sized lesions that were histologically different did not have these cysts.

Although the 54 cases examined in this series are statistically a small sample, the marginal cysts were identified only in the 3 patients with esthesioneuroblastoma. One might theorize that with a very large patient population, similar marginal cysts may be identified with other lesions. However, at present, the only known sinonasal tumor to be associated with such cysts is esthesioneuroblastoma. Thus at present it seems reasonable to conclude that on MR, when a soft-tissue sinonasal mass is present with extension into the anterior cranial fossa and there are associated marginal cysts, the presumptive diagnosis of esthesioneuroblastoma should be made.

Acknowledgment

We thank Dr Barbara Zeifer who supplied the images for case 2.

References

1. Kadish S, Goodman M, Wine CC. Olfactory neuroblastoma: a clinical analysis of 17 cases. *Cancer* 1976;37:1571-1576
2. Barnes L, Peel RL, Verbin SR. Tumors of the nervous system. In: Barnes L, ed. *Surgical Pathology of the Head and Neck*. Vol 1. New York: Marcel Dekker, 1985:675-724
3. Som PM, Shugar JMA. When to question the diagnosis of anaplastic carcinoma. *Mt Sinai J Med* 1981;48:230-235
4. Yousem DM, Fellows DW, Kennedy DW, Bolger WE, Kashima H, Zinreich SJ. Inverted papilloma: evaluation with MR imaging. *Radiology* 1992;185:501-505
5. Som PM, Shapiro MD, Biller HF, Sasaki C, Lawson W. Sinonasal tumors and inflammatory tissues: differentiation with MR. *Radiology* 1988;167:803-808
6. Manelfe C, Bonafe A, Fabre P, Pessey JJ. Computed tomography in olfactory neuroblastoma: one case of esthesioneuroepithelioma and four cases of esthesioneuroblastoma. *J Comput Assist Tomogr* 1978;2:412-420
7. Som PM, Lidov H. The significance of sinonasal radiodensities: ossification, calcification, or residual bone? *AJNR Am J Neuroradiol* 1994;15:917-922
8. Hasso AN, Hinshaw DB, Kief-Garcia ML. Neoplasms of the cranial nerves and skull base. In: Stark DD, Bradley WG Jr, eds. *Magnetic Resonance Imaging*. Vol 1. 2nd ed. St. Louis: Mosby Yearbook, 1992:860-863
9. Starkman SP, Brown TC, Linell EA. Cerebral arachnoid cysts. *J Neuropathol Exp Neurol* 1958;17:484-500
10. Naidich TP, McLone DG, Radkowski MA. Intracranial arachnoid cysts. *Pediatr Neurosci* 1985-1986;12:112-122
11. Robinson RG. The temporal lobe agenesis syndrome. *Brain* 1964;88:87-106
12. Dross PE, Lally JF, Bonier B. Pneumosinus dilatans and arachnoid cyst: a unique association. *AJNR Am J Neuroradiol* 1992;13:209-211