



Discover Generics

Cost-Effective CT & MRI Contrast Agents



FRESENIUS
KABI

WATCH VIDEO

AJNR

Postvaricella basal ganglia infarction in children.

F S Silverstein and J A Brunberg

AJNR Am J Neuroradiol 1995, 16 (3) 449-452

<http://www.ajnr.org/content/16/3/449>

This information is current as
of June 3, 2025.

Postvaricella Basal Ganglia Infarction in Children

Faye S. Silverstein and James A. Brunberg

Summary: Two patients presented with acute neurologic deficits attributable to contralateral basal ganglia infarction 1 to 3 months after episodes of chickenpox. Both presented with hemiparesis with one patient also demonstrating ipsilateral choreo-athetosis. In both patients MR revealed unilateral basal ganglia infarction. Cerebral angiography findings in one patient were normal; in the second, there was unilateral narrowing of the common carotid artery and of proximal branches of the anterior and middle cerebral artery.

Index terms: Basal ganglia, infarction; Children, central nervous system; Viruses

Parainfectious and postinfectious encephalopathies are well-recognized complications of varicella infection and may relate to the viral infection directly or to the autoimmune process (1, 2). Well-recognized sequelae of varicella have included acute disseminated encephalomyelitis, transverse myelitis, polyradiculoneuropathy, optic neuritis and Reye syndrome (1, 2). In children, the most commonly recognized postvaricella encephalopathic syndrome is acute cerebellar ataxia, which has its onset several days to 2 weeks after the exanthem. In patients with acute cerebellar ataxia associated with varicella (13) or other infectious disorders (4–6), magnetic resonance (MR) studies of the brain have on occasion demonstrated mass effect (6) and increased signal intensity on T2-weighted images involving the cerebellum or brain stem (3–7). Ataxia and MR alterations generally resolve over weeks to months (4, 6), although volume loss and foci of altered signal intensity may persist (5). Acute varicella encephalitis involving the cerebellum, another neurologic complication of varicella, has been associated with cerebellar mass effect and increased signal intensity on T2-weighted images (8).

An additional sequela of varicella, characterized by the development of basal ganglia infarction, has recently been identified in pediatric patients (9–12). The major clinical abnormality is the development of hemiparesis, with radiologic studies demonstrating unilateral basal ganglia infarction. We present here two patients who illustrate the major clinical and neuroradiologic features of this syndrome.

Case Histories

Case 1

A 4-year-old girl was initially seen with a 6- to 8-hour history of lethargy and incoordination. She had a history of chickenpox 1 month earlier and had been treated briefly with acyclovir at her parents' request. Examination revealed an awake, but tired child with a mild right hemiparesis. There was mild dysarthria without dysphasia. A computed tomography scan, done less than 8 hours after neurologic symptoms were recognized, demonstrated a nonenhancing region of low attenuation in the posterior portion of the left putamen (Fig 1). MR imaging 4 hours later demonstrated a nonenhancing area of increased signal intensity on T2-weighted images in the same region (Fig 1). Results of a lumbar puncture were normal, as were extensive investigations to exclude other causes of vasculitis. A cerebral angiogram was normal. Her neurologic deficits improved remarkably over 3 to 4 days, and 5 days after the onset of her illness there was only a subtle residual right hemiparesis. A second MR study 5 days later revealed contrast enhancement limited to the left putamen but was otherwise unchanged. Treatment with aspirin, as an antiplatelet agent, was initiated. There has been no recurrence.

Case 2


Right facial droop and slurred speech suddenly developed in a 6-year-old child. Several days later, transient right-sided weakness was noted, which resolved over 1 to

Received January 4, 1993; accepted after revision April 27.

From the Departments of Pediatrics (F.S.S.), Neurology (F.S.S., J.A.B.), and Radiology (J.A.B.), and the Division of Neurosurgery (J.A.B.), University of Michigan Medical Center, Ann Arbor.

Address reprint requests to James A. Brunberg, MD, Department of Radiology, University of Michigan Medical Center, UH B2B311-0030, Ann Arbor, MI 48109-0030.

AJNR 16:449–452, Mar 1995 0195-6108/95/1603-0449 © American Society of Neuroradiology



2 days. A prominent right-sided choreoathetosis then developed. Chickenpox had occurred 2 to 3 months earlier. Initial evaluation at another hospital included an MR scan that revealed a nonenhancing focal region of increased signal intensity on T2-weighted images involving the globus pallidus adjacent to the anterior commissure and the medial aspect of the putamen (Fig 2). The region of altered signal intensity extended into the body of the caudate and adjacent central white matter of the left frontal lobe (Fig 2). Subsequent neurologic examination at our institution was normal except for choreiform movement of the right arm, face, and leg. Complete blood count, coagulation studies, and vasculitis screen were normal. Analysis of cerebrospinal fluid demonstrated 9 white blood cells per cubic millimeter with normal levels of protein and glucose. Cerebral angiography revealed mild narrowing and irregularity of the intimal surface of the distal left internal carotid, the A1 segment of the left anterior cerebral artery, and the M1 segment of the left middle cerebral artery (Fig 2). No changes were seen further to the periphery, and there were no angiographic abnormalities of the right carotid system. Treatment with steroids was initiated. The patient's neurologic deficit improved remarkably, and 1

month after the onset of his movement disorder there was only minimal residual evidence of hemichorea.

Discussion

The two case histories presented in this report are compatible with the clinical syndrome of basal ganglia infarction occurring 1 to 3 months after the occurrence of varicella (9–12). No other cause of cerebrovascular disease was identified in either case, despite extensive investigation.

The clinical course, long-term prognosis, and MR findings of basal ganglia infarction in children has been reviewed recently in a series of 16 patients, 14 of whom presented with acute hemiplegia at a mean age of 46 months (9). In 9 of the 16 patients there was a history of chickenpox, which occurred 1 to 4 months before the onset of hemiplegia. In 5 of 7 patients in whom angiography was done, narrowing of the middle




Fig 2. A and B, Axial MR images (2405/90) demonstrate increased signal intensity at the interface of the globus pallidus and putamen, extending superiorly into the centrum semiovale.

C, Left common carotid angiogram demonstrates narrowing of the lumen and slight irregularity of the intimal surface at the origin of the anterior (*arrowhead*) and middle cerebral (*arrow*) arteries.

cerebral artery was demonstrated. It was unclear from their report whether the 5 patients were all from the postvaricella group.

Other reports have established a causal link between varicella and the occurrence of basal ganglia infarction in patients of pediatric age (10–12). Bodensteiner and colleagues reported five patients seen over a 14-month period in a single clinical practice (10). All presented with hemiplegia 1 to 4 months after varicella infection, and all had similar unilateral basal ganglia abnormalities on MR imaging consistent with regions of infarction. No other causes of stroke were detected. Since varicella infection is so widespread, and other neurologic sequelae are well described, it is surprising that this syndrome has not been more frequently recognized. The possibility that changes in viral characteristics have contributed to this pattern may be considered.

The MR findings in these two patients differ from those expected with postinfectious encephalomyelitis by their unifocal pattern, by the arterial rather than perivenous distribution of the lesions, and by the predominate involvement of gray rather than white matter (13). Although the underlying pathophysiologic

mechanism is most likely that of a focal angiitis, cerebral angiography has previously revealed both normal (9, 10) and abnormal (9–11) findings. Presumably the underlying pathophysiologic mechanism is the same in all cases, and discrepant findings may reflect either the severity and extent of vascular alterations or the sensitivity of specific angiographic techniques. It is unclear whether identification of subtle angiographic abnormalities will justify the use of immunosuppressive therapy, or whether this syndrome may herald the occurrence of progressive cerebrovascular disease.

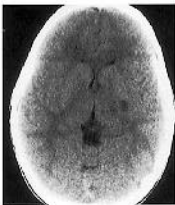Herpes zoster viral infection in adult patients is a well-recognized antecedent of cerebral angiitis and contralateral hemiparesis (14). Stroke after herpes zoster ophthalmicus has been reported in both adults and children, although it is quite uncommon. In this disorder thrombosis of one or more branches of the ipsilateral middle cerebral artery typically occurs several days or weeks after infection. This is usually accompanied by a mild mononuclear cerebrospinal fluid pleocytosis. Narrowing or irregularity of proximal branches of the anterior or middle cerebral arteries are the most common angiographic findings, and multiple cerebral infarcts may be

demonstrated on computed tomography in the basal ganglia and distribution of the middle cerebral arteries. It is postulated that the vasculitis in this disorder results from direct invasion of arterial vessels by the virus, which has traveled along the trigeminal axons that innervate the middle cerebral artery (10). A relationship of the vasculopathy to an immune-mediated process triggered by the herpes zoster infection, or to direct invasion of the vessel wall, has also been postulated (14). Similar processes may be responsible for the vasculopathy associated with varicella (10).

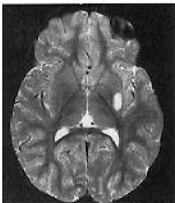
Antecedent varicella infection should be considered in the differential diagnosis of basal ganglia infarction in children. Prospective studies will be essential for better defining the natural history of this disorder and for determining whether patients who have angiographic evidence of postvaricella vasculopathy benefit from treatment with steroids or antiplatelet agents.

References

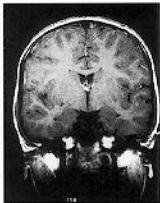
1. Tenorio G, Whitaker JN. Steroid-dependent postvaricella encephalomyelitis. *J Child Neurol* 1991;6:45-48
2. Barnes DW, Whitley RJ. CNS diseases associated with varicella zoster virus and herpes simplex virus infection: pathogenesis and current therapy. *Neurol Clin* 1986;4(1):265-283
3. Trend P, Youl BD, Sanders MD, Kocen RS, McDonald WI. Vertical gaze palsy due to a resolving midbrain lesion. *J Neurol Neurosurg Psychiatry* 1990;53:708-709
4. Hayashi T, Ichiyama T, Kobayashi K. A case of acute cerebellar ataxia with an MRI abnormality. *Brain Dev* 1989;11(6):435-436
5. Horowitz MB, Pang D, Hirsch W. Acute cerebellitis: case report and review. *Pediatr Neurosurg* 1991-92;17:142-145
6. Shoji H, Hirai S, Ishikawa K, et al. CT and MR imaging of acute cerebellar ataxia. *Neuroradiology* 1991;33:360-361
7. Groen RJM, Begeer JH, Wilmink JT, le Coulre R. Acute cerebellar ataxia in a child with transient pontine lesions demonstrated by MRI. *Neuropediatrics* 1991;22:225-227
8. Hurst DL, Mehta S. Acute cerebellar swelling in varicella encephalitis. *Pediatr Neurol* 1988;4(2):122-123
9. Inagaki M, Koeda T, Takeshita K. Prognosis and MRI after ischemic stroke of the basal ganglia. *Pediatr Neurol* 1992;8:104-108
10. Bodensteiner JB, Hille MR, Riggs JE. Clinical features of vascular thrombosis following varicella. *Am J Dis Child* 1992;146:100-102
11. Kamholz J, Tremblay G. Chickenpox with delayed contralateral hemiparesis caused by cerebral angiitis. *Ann Neurol* 1985;18:358-360
12. Liu GT, Holmes GL. Varicella with delayed contralateral hemiparesis detected by MRI. *Pediatr Neurol* 1990;6:131-134
13. Atlas SW, Grossman RI, Goldberg HI, et al. MR diagnosis of acute disseminated encephalomyelitis. *J Comput Assist Tomogr* 1986;10(5):798-801
14. Hilt DC, Buchholz D, Krumholz A, Weiss H, Wolinsky J. Herpes zoster ophthalmicus and delayed contralateral hemiparesis caused by cerebral angiitis: diagnosis and management approaches. *Ann Neurol* 1983;14:543-553



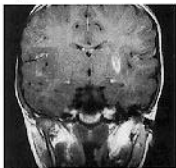
A



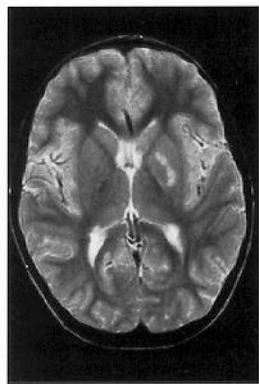
B



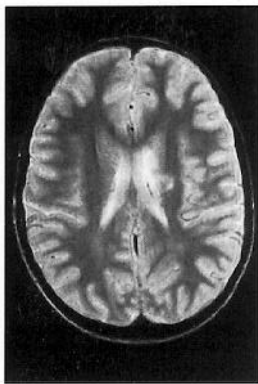
C



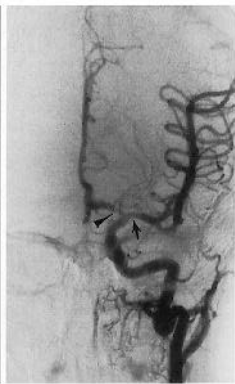D



A



B



C