



Discover Generics

Cost-Effective CT & MRI Contrast Agents



FRESENIUS
KABI

WATCH VIDEO

AJNR

Solitary infantile myofibromatosis of the skull.

J A Queralt and V C Poirier

AJNR Am J Neuroradiol 1995, 16 (3) 476-478

<http://www.ajnr.org/content/16/3/476>

This information is current as
of June 5, 2025.

Solitary Infantile Myofibromatosis of the Skull

John A. Queralt and Virginia C. Poirier

Summary: We describe the CT and plain-film appearance of solitary infantile myofibromatosis of the skull in a 5-year-old boy. This benign lesion closely resembles histiocytosis X on imaging studies.

Index terms: Skull, neoplasms; Children, neoplasms

Infantile myofibromatosis is a rare entity of childhood characterized by benign myofibroblastic tumors in the soft tissues, the bones, and, occasionally, the viscera. These tumors are most commonly solitary but may be multicentric. Solitary skeletal lesions are relatively uncommon; when present, they occur in the craniofacial skeleton. These lesions should be distinguished from other, more aggressive fibrous tumors for appropriate conservative treatment.

Case Report

The patient is a healthy 5-year-old boy who was brought to medical attention for evaluation of a painless lump above the left ear, which had persisted unchanged for 4 weeks. The child was healthy and had no significant medical history. On examination the lesion was noted to be smooth, firm, and nontender. No adenopathy or other masses were found. The family's medical history, including that of a younger sibling, was unremarkable. Plain films of the skull and a subsequent computed tomographic brain scan performed without intravenous contrast demonstrated a 1.5-cm expansile, lytic lesion in the squamous portion of the left temporal bone with destruction of both the inner and outer tables, periosteal new bone formation, and an associated extracranial soft-tissue mass (Fig 1). No intracranial abnormalities were present. A technetium-99m-methylene diphosphonate whole-body bone scan confirmed this lesion as a solitary focus of increased uptake (Fig 2). An excisional biopsy was performed under general anesthesia without complication. A frozen section revealed spindle-cell proliferation with no mitoses, which suggested myofibromatosis. Permanent hematoxylin and

eosin sections confirmed the diagnosis of infantile myofibromatosis.

Discussion

Infantile myofibromatosis, although rare, is the most common fibrous tumor of infancy (1). Originally called *congenital generalized fibromatosis*, it was distinguished as a distinct entity within the group of juvenile fibromatosis by Stout in 1954 (2). It has been referred to in the literature by various terms, including *congenital multiple fibromatosis*, *multiple mesenchymal hamartomas*, *multiple vascular leiomyomas of the newborn*, *diffuse congenital fibromatosis*, *benign mesenchymomas*, and *generalized hamartomatosis*. The disease is characterized by solitary or multiple benign myofibroblastic tumors in the subcutaneous tissue, muscle, bone, and occasionally viscera. It occurs almost exclusively in infants and young children, usually in the first 2 years of life (89%), although an adult counterpart has been described (3, 4).

The disorder has progressed through various classification schemes but is usually divided into two forms, solitary and multicentric (5–8). In a series of 61 cases, Chung and Enzinger found the solitary form to be more common (a three-to-one ratio) and to have a slight male predominance, whereas the multicentric form was slightly more frequent in female patients (3). Solitary lesions are most frequently located in the soft tissues (skin, muscle, and subcutaneous tissue) of the head and neck, followed by the trunk, then extremities. A solitary intraorbital lesion with intracranial extension has recently been reported (9). The multicentric form also predominantly involves the soft tissues; however, approximately one third of these

Received February 2, 1993; accepted after revision May 6.

From the Department of Radiology, University of California Davis Medical Center, Sacramento.

Address reprint requests to Virginia C. Poirier, MD, University of California Davis Medical Center, Department of Radiology, 2516 Stockton Blvd, TICON II, Sacramento, CA 95817.

AJNR 16:476–478, Mar 1995 0195-6108/95/1603-0476 © American Society of Neuroradiology




Fig 1. A, Computed tomographic scan of the brain at a bone window setting demonstrates a solitary lytic lesion of the left temporal bone with destruction of the inner and outer tables of the skull, periosteal new bone formation, and an extracranial soft-tissue mass.

B, Magnified view of the lytic skull lesion.

C, Lateral skull radiograph demonstrates a solitary sharply circumscribed lytic lesion in the squamous portion of the left temporal bone.

D, Tangential view of the lytic skull lesion demonstrates periosteal new bone formation.

cases involve the viscera, typically the lung, heart, and gastrointestinal tract. Multicentric lesions that involve the viscera have a poor prognosis with a 75% mortality. Both autosomal dominant and autosomal recessive modes of inheritance have been suggested, and although in utero estrogen stimulation has been implicated, the cause remains uncertain (10–12).




Fig 2. Technetium-99m-methylene diphosphonate bone scan demonstrates a solitary focus of increased uptake in the squamous portion of left temporal bone.

Skeletal lesions, common in multicentric disease, account for only 10% of the cases of solitary infantile myofibromatosis (1, 3). Solitary bone lesions most commonly involve the craniofacial skeleton, a rare location in multicentric disease (3, 6, 13). The radiographic appearance is of a well-defined lytic lesion with or without a sclerotic rim. Lesions in the calvarium tend to be round, measuring 1 to 3 cm, and may expand the inner and outer tables. The radiographic differential diagnosis includes histiocytosis X, fibrous dysplasia, epidermoid, osteoblastoma, metastatic neuroblastoma, and, less likely, fibrosarcoma. Marked enhancement has been reported on contrast-enhanced computed tomographic scanning of soft-tissue lesions with associated bone destruction (9). The use of magnetic resonance imaging in the detection of soft-tissue and visceral lesions has been reported (14). Magnetic resonance proved useful in following the regression of these lesions as well. The lesions were of moderately low signal intensity on T1-weighted images and of increased signal intensity on T2-weighted images. Regressing lesions were characterized by a central focus of marked T2 prolongation.

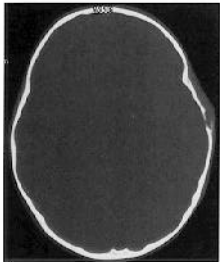
The diagnosis is usually established by excisional biopsy. The use of fine-needle aspiration biopsy has been described but is not well estab-

lished (15). Microscopically the solitary bone lesions are similar to those in the multicentric form and are characterized by fascicles, whorls, and nodules of spindle-shaped cells with myofibroblastic features (13). Hyalin-like areas may be present, and areas of less-differentiated cells arranged in a hemangiopericytoma-like pattern have been reported (8).

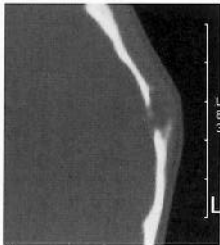
In the absence of visceral involvement, or when only a single visceral lesion is present, the prognosis is excellent (3). Spontaneous regression, especially of bone lesions in multicentric disease, is commonly reported and has led some to recommend surgical excision only in cases of functional impairment (1). Excision of solitary lesions is usually performed for diagnosis and is typically curative. The recurrence rate is low (10%) and usually successfully treated with reexcision (1, 3, 13).

References

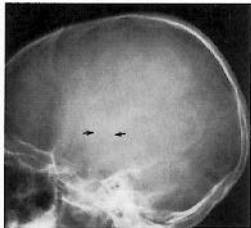
1. Wiswell TE, Davis J, Cunningham BE, Solenberger R, Thomas P. Infantile myofibromatosis: the most common fibrous tumor of infancy. *J Pediatr Surg* 1988;23:314-318
2. Stout AP. Juvenile fibromatosis. *Cancer* 1954;7:953-978
3. Chung EB, Enzinger FM. Infantile myofibromatosis. *Cancer* 1981;48:1807-1818
4. Daimaru Y, Hashimoto H, Enjoji M. Myofibromatosis in adults: adult counterpart of infantile myofibromatosis. *Am J Surg Pathol* 1989;13:859-865
5. Kaufman SL, Stout AP. Congenital mesenchymal tumors. *Cancer* 1965;18:460-476
6. Morettn LB, Mueller E, Schreiber M. Generalized hamartomatosis: congenital generalized fibromatosis. *AJR Am J Roentgenol* 1972;114:722-734
7. Rosenberg HS, Stenback WA, Spjut HJ. The fibromatoses of infancy and childhood. *Perspect Pediatr Pathol* 1978;4:269-343
8. Bolano LE, Yngve DA, Altshuler G. Solitary fibromatosis of bone: a rare variant of congenital generalized fibromatosis. *Clin Orthop* 1991;263:238-241
9. Stautz CC. CT of infantile myofibromatosis of the orbit with intracranial extension: a case report. *AJNR Am J Neuroradiol* 1991;12:184-185
10. Jennings TA, Duray PH, Collins FS, Sabetta J, Enzinger FM. Infantile myofibromatosis: evidence for an autosomal dominant disorder. *Am J Surg Pathol* 1984;8:529-538
11. Baird PA, Worth AJ. Congenital generalized fibromatosis: an autosomal recessive condition? *Clin Genet* 1976;9:488-494
12. Wiswell TE, Sakas EL, Stephenson SR, et al. Infantile myofibromatosis. *Pediatrics* 1985;76:981-984
13. Inwards CY, Unni KK, Beabout JW, Shives TC. Solitary congenital fibromatosis (infantile myofibromatosis) of bone. *Am J Surg Pathol* 1991;15:935-941
14. Moore JB, Waldenmaier N, Potchen EJ. Congenital generalized fibromatosis: a new management strategy provided by magnetic resonance imaging. *Am J Dis Child* 1987;141:714-716
15. Ostrowski ML, Bradshaw J, Garrison D. Infantile myofibromatosis: diagnosis suggested by fine-needle aspiration biopsy. *Diagn Cytopathol* 1990;6:284-288



A



B



C



D

