



Discover Generics

Cost-Effective CT & MRI Contrast Agents



WATCH VIDEO

AJNR

A simple CT method for location of auditory brain stem implant electrodes.

W W Lo, A Tasaka, B Zink and O Harris

AJNR Am J Neuroradiol 1995, 16 (3) 599-601

<http://www.ajnr.org/content/16/3/599>

This information is current as
of June 5, 2025.

A Simple CT Method for Location of Auditory Brain Stem Implant Electrodes

William W. M. Lo, Art Tasaka, Betty Zink, and Olympia Harris

Summary: A method for locating auditory brain stem implant electrodes that have been placed in the lateral recess of the fourth ventricle is described. CT bone window images are "inverted" to black on white, then manually superimposed onto soft-tissue window images to enable identification of electrodes in relation to soft-tissue structures.

Index terms: Brain stem, computed tomography; Computed tomography, artifacts; Computed tomography, technique

Artifacts caused by auditory brain stem implant electrodes on computed tomographic (CT) images hinder assessment of relationship of the electrodes to soft-tissue anatomy. By superimposing the black-white reversed edge-enhanced image of the electrodes on the soft-tissue image of the same CT section, this problem can be reduced.

Equipment and Method

A GE 9800 CT scanner (General Electric, Milwaukee, Wis) is used at our institution. Other scanners with similar capabilities should also suffice.

The patient's head is positioned in such a way that the orbital-meatal line lies as close to the vertical as possible. A lateral digital radiograph is then obtained for location of CT sections and for reference when follow-up CT studies are performed.

Contiguous transverse sections are obtained, 3 mm each in thickness through the posterior fossa and, optionally in addition, 5 and 10 mm from the sella to the vertex. These scans are processed with a standard algorithm and displayed with soft-tissue windows. Intravenous iodinated contrast material is not routinely administered when the study is performed solely for electrode location.

On the basis of the 3-mm sections, several (generally three to six) contiguous 1.5-mm sections (head scan field of view, 140 kV, 170 mA, 2 seconds; display field of view, 14 cm, 512 × 512 matrix) are obtained through the electrodes and processed through: (a) the standard algorithm and displayed for soft tissues (Fig 1A); and (b) an edge-enhancement algorithm for high-contrast objects and dis-

played for metal and bone (Fig 1B). A grid with centimeter units on the x- and y-coordinates is placed on the edge-enhanced images to relate position in the x and y directions for objects lying in different planes of the z-axis.

The key edge-enhanced 1.5-mm section or sections are then black-white reversed (Fig 1C) and manually superimposed on the corresponding soft-tissue sections (Fig 1A) to facilitate locating the electrodes in relation to the relevant anatomy (Fig 1D).

Discussion

An auditory brain stem implant is an electronic device similar to a cochlear implant, designed to stimulate the cochlear nuclei directly, giving the sensation of sound to an otherwise deaf patient (1). The auditory brain stem implant device consists of a set of electrodes (Fig 2) connected by electric wires to a percutaneous plug or a subcutaneous receiver coil, and an external speech processor.

The recipients are patients who have lost integrity of their auditory nerves between the spiral ganglion of the cochlea and the cochlear nuclei in the brain stem bilaterally. They are principally patients undergoing resection of bilateral acoustic schwannomas (neurofibromatosis type 2) or unilateral tumors in their only hearing ears, who are unable to benefit from cochlear implants (1).

The current technique of implantation calls for placement of the electrode assembly in the lateral recess of the fourth ventricle through the foramen of Luschka, to take advantage of the immediate proximity of the cochlear nuclei medial and superior to the lateral recess (2-4). Long-term positional stability is possible for the electrodes in this location (1, 5). More ventral placement of electrodes can produce nonauditory stimulation of the facial, glossopharyngeal,

Received August 12, 1993; accepted after revision December 14.

From the St Vincent Radiological Medical Group, Inc (W.W.M.L., A.T.), and St Vincent Medical Center (B.Z., O.H.), Los Angeles, Calif.

Address reprint requests to William W. M. Lo, MD, 2131 W Third St, Los Angeles, CA 90057.


Fig 1. Triple auditory brain stem implant electrodes fully inserted in a desirable position in lateral recess of fourth ventricle of a patient.

A, A 1.5-mm section, standard algorithm (window level, +35; window width, 150). The artifact in the region of the right lateral recess may be attributed to one or more electrodes or a segment of electrode wire. Note bilateral translabyrinthine surgical defects from removal of acoustic schwannomas.

B, A 1.5-mm section, edge-enhancement algorithm (window level, +1000; window width, 4000). Triple electrodes are clearly resolved but will not be visible when B is superimposed on A.

C, Same 1.5-mm section, edge-enhancement algorithm, black-white reversed (window level, +1500; window width, 2000).

D, C superimposed on A. The relationship of electrodes to the lateral recess is now well demonstrated.



vagus, or spinal accessory nerves or the overlying flocculus of the cerebellum (1, 5).

Documentation of electrode position is therefore obtained by imaging after implantation before stimulation and when patients subsequently experience a change in auditory sensation or side effects on stimulation.

Both CT and magnetic resonance imaging can be used for this purpose. However, only the newer electrodes with nonmagnetic percutaneous plugs or subcutaneous receiver coils have been documented to be magnetic resonance compatible (Portillo F, "Effects of Magnetic Resonance Imaging on Auditory Brainstem Implant," presented at Third International Cochlear Implant Conference, Innsbruck, Austria, April 1993), and, in our experience, only elec-

trodes surrounded by fibrous tissue are visible on magnetic resonance. Therefore in many patients, CT is relied on for monitoring the position of electrodes.

CT processed by standard or soft-tissue algorithm demonstrates the soft-tissue landmarks adequately but does not distinguish the metallic electrodes and wires (Fig 1A). High-resolution CT by bone or edge-enhancement algorithm delineates the electrodes and differentiates them from the electrode wire (Fig 1B) but loses the soft-tissue anatomic references. When an edge-enhanced image is directly superimposed on its corresponding soft-tissue image, the electrodes are obscured by their own artifacts (white on white). Therefore black-white reversal of the edge-enhanced image (Fig 1C) is used so that the electrodes can be superimposed on their corresponding anatomic structures on standard images and remain visible (Fig 1D).

The use of a grid over the assembly on the edge-enhanced images facilitates determination of spatial relationship of electrodes seen on different sections and assessment of tilting of the electrode plate in the superoinferior direction.

We have not found multiplanar reformation to be of sufficient resolution to be helpful.

A pair of ball electrodes were placed in the vicinity of a patient's cochlear nuclei by House




Fig 2. Auditory brain stem implant electrode array. A model used in 1991 and 1992, same as the one shown in Figure 1, consisting of three 0.75×2.5 -mm plates supported by a 2.5×8.5 -mm Dacron (Du Pont, Wilmington, Del) weave (courtesy of House Ear Institute).

and Hitselberger in 1979 (1). Early research spearheaded by the House Ear Institute (Los Angeles, Calif) has led to an eight-electrode device manufactured by the Cochlear Corporation (Englewood, Colo) now pending approval by the Food and Drug Administration for investigational device exemption for clinical trial in the United States and England.

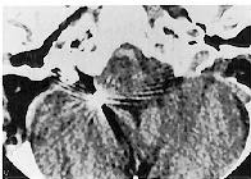
The number of auditory brain stem implant devices used will likely remain relatively small. However, this simple CT method for location of electrodes with standard late-generation CT scanners without sophisticated special algorithms (6, 7) can also be used to facilitate location of other metallic devices or foreign bodies in relation to soft-tissue anatomy in the cranium or other body parts.

Addendum

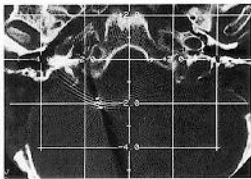
Investigational device exemption for clinical trials was granted for auditory brain stem implants to the Cochlear Corporation by the Food and Drug Administration in June 1994.

References

1. Brackmann DE, Hitselberger WE, Nelson RA, et al. Auditory brainstem implant, I: issues in surgical implantation. *Otolaryngol Head Neck Surg* 1993;108:624-633
2. Haines DE. *Neuroanatomy: An Atlas of Structures, Sections and Systems*. 2nd ed. Baltimore: Urban & Schwarzenberg, 1987:87
3. Solsberg MD, Fournier D, Potts DG. MR imaging of the excised human brain stem: a correlative neuroanatomic study. *AJNR Am J Neuroradiol* 1990;11:1003-1013
4. Kretschmann H-J, Weinrich W. *Cranial Neuroimaging and Clinical Neuroanatomy: Magnetic Resonance Imaging and Computed Tomography*. 2nd ed. New York: Thieme Medical Publishers, 1992:133
5. Shannon RV, Fayad J, Moore J, et al. Auditory brainstem implant, II: postsurgical issues and performance. *Otolaryngol Head Neck Surg* 1993;108:634-642
6. Kalender WA, Hebel R, Ebersberger J. Reduction of CT artifacts caused by metallic implants. *Radiology* 1987;164:576-577
7. Robertson DD, Weiss PJ, Fishman EK, Magid D, Walker PS. Evaluation of CT techniques for reducing artifacts in the presence of metallic orthopedic implants. *J Comput Assist Tomogr* 1988;12:236-241



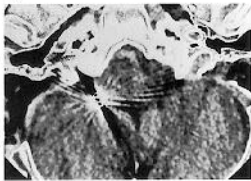
A



B



C



D

