



Discover Generics

Cost-Effective CT & MRI Contrast Agents



FRESENIUS
KABI

WATCH VIDEO

AJNR

MR of parenchymal neurocutaneous melanosis.

A Demirci, Y Kawamura, G Sze and C Duncan

AJNR Am J Neuroradiol 1995, 16 (3) 603-606

<http://www.ajnr.org/content/16/3/603>

This information is current as
of June 5, 2025.

MR of Parenchymal Neurocutaneous Melanosis

Ali Demirci, Yasutaka Kawamura, Gordon Sze, and Charles Duncan

Summary: Two cases of neurocutaneous melanosis are presented. MR showed hyperintense areas in the brain on short-repetition-time/short-echo-time sequences, compatible with intraparenchymal melanin deposits. No leptomeningeal abnormality was seen.

Index terms: Phakomatoses; Melanoma; Brain, magnetic resonance

Neurocutaneous melanosis is a rare nonfamilial disorder generally characterized by congenital intradermal benign pigmented nevi and leptomeningeal melanosis. It is thought to represent an embryonal neuroectodermal dysplasia with excessive proliferation of melanin-producing cells, either focal or diffuse, in both skin and leptomeninges (1, 2). The diagnostic criteria described by Fox (3) are: (a) abnormal skin pigmentation with giant or multiple pigmented nevi, (b) absence of malignant change in any skin lesion, and (c) absence of malignant melanoma in any organ other than the leptomeninges. However, Leaney et al (2) stated that 2% to 13% of cases have malignant degeneration of skin nevi and Kaplan et al (4) reported a case with distant organ metastases from leptomeningeal melanoma.

Magnetic resonance (MR) of neurocutaneous melanosis with temporal lobe pigmentation or temporal lobe malignant melanoma (5, 6), with abnormal leptomeningeal enhancement without malignant degeneration (7), and with intraspinal lipoma (8) have been reported. We present the MR findings in two cases of neurocutaneous melanosis with intraparenchymal melanin deposition without detectable leptomeningeal melanosis.

Case 1

A 5-month-old boy showed multiple pigmented areas of the skin, specifically multiple confluent hairy nevi on the

extremities, back, and most of the anterior trunk. Biopsy disclosed intradermal benign nevi. Although asymptomatic, the patient was referred for evaluation of the central nervous system. MR examination at 1.5 T showed a hyperintense area in the amygdala of the right temporal lobe on all pulse sequences (Fig 1 A–C). No edema, mass effect, or abnormal myelination for age were detected. Postcontrast images showed no abnormal enhancement within the lesion or leptomeninges (Fig 1D). MR findings of the spine were normal. Follow-up MR examination 3 months later did not show any changes.

The patient went to surgery, and the pathologic specimen of the temporal lobe lesion showed prominent perivascular melanocytic and histiocytic infiltration. The melanocytes were moderately to heavily loaded with melanin pigments. The surrounding tissue showed no abnormality other than slightly increased reactive glial cells.

Case 2

A boy was born with multiple pigmented nevi on the extremities, face, and trunk. The nevi were of variable size. Skin biopsies showed benign intradermal nevi. The patient also had pedunculated masses on the sacral and right hip area.

Cranial ultrasound and computed tomographic (CT) examinations showed dilated third and lateral ventricles, hypoplastic cerebellum, and enlarged cisterna magna communicating with the fourth ventricle. MR at 1.5 T confirmed these findings and also showed slight rotation of the vermis, upward displacement of the tentorium, and slight scalloping of the occipital bone. The patient was thought to have a Dandy-Walker variant. No abnormal enhancement or abnormal parenchymal intensity was detected.

When the patient was 1 month of age, a ventriculoperitoneal shunt was placed. CT and MR at this time showed focal hemorrhage near the catheter tip, but no other changes. When he was 3 months of age, the sacral and right hip masses were resected and proved to be common skin nevi. Seizures developed in the postoperative period. Electroencephalography showed right temporal spike and slow waves with nearly normal background.

Received July 6, 1992; accepted after revision April 19, 1993.

From the Departments of Diagnostic Radiology (A.D., Y.K., G.S.) and Neurosurgery (C.D.), Yale University School of Medicine, New Haven, Conn.


Address reprint requests to Gordon Sze, MD, Yale University School of Medicine, Department of Diagnostic Imaging, Section of Neuroradiology, 333 Cedar St, PO Box 3333, New Haven, CT 06510

AJNR 16:603–606, Mar 1995 0195-6108/95/1603-0603 © American Society of Neuroradiology

Fig 1. *A* and *B*, Sagittal and coronal T1-weighted (600/25 and 600/30) images show hyperintense area in the right temporal lobe.

C, T2-weighted (2500/90) image shows slightly hyperintense area in the right temporal lobe.

D, Postcontrast T1-weighted (600/30) image shows no abnormal enhancement.



When the patient was 9 months of age, CT showed slightly increased densities in the temporal lobes bilaterally (Fig 2A). At 15 months of age, MR examination of the brain showed hyperintense areas in the pons, left thalamus, superior cerebellar cortex, and the temporal lobes bilaterally on T1-weighted and spin-density images (Fig 2B–D). The hyperintense areas were nearly normal on T2-weighted images (Fig 2E). Postcontrast images did not show any abnormal enhancement. MR of the cervical and thoracic spine also was normal. Follow-up MR examinations over a 1-year period have not shown any detectable changes.

Discussion

Neurocutaneous melanosis is thought to be an embryonal neuroectodermal dysplasia. In as many as half of the patients leptomeningeal malignant melanoma develops (3). This dysplasia rarely may be associated with other neurocutaneous syndromes such as neurofibromatosis or Sturge-Weber syndrome. Clinically, the patients present with hydrocephalus, seizure, psychiatric disturbance, stillbirth, cranial nerve palsy, meningeal hemorrhage, subdural hemorrhage, intracranial hemorrhage, myelopathy,

and radiculopathy (2, 9, 10). During childhood, patients are often seen with hydrocephalus, most frequently caused by obstruction of flow or decreased absorption of cerebrospinal fluid by the thickened leptomeninges. However, hydrocephalus attributable to Dandy-Walker complex have been reported in six cases (6, 11, 12) and was noted in case 2. Dandy-Walker complex may result from an insult to both the cerebellar hemisphere development and the fourth ventricle. Any failure of incorporation between the choroid plexus and the roof of the fourth ventricle or delayed opening of foramen Magendie may form fourth ventricle–cisterna magna cyst (13). The meningeal cells play a role in cerebellar development. In neurocutaneous melanosis, the abnormal leptomeninges may interfere with the normal effects on the development of the cerebellum (6). Kadonaga et al (6) have proposed that concurrent development of the Dandy-Walker complex and the neurocutaneous melanosis is not an incidental finding. The melanin-containing abnormal leptomeninges may disrupt both the development of the cerebellum and the fourth ventricle. Because of the

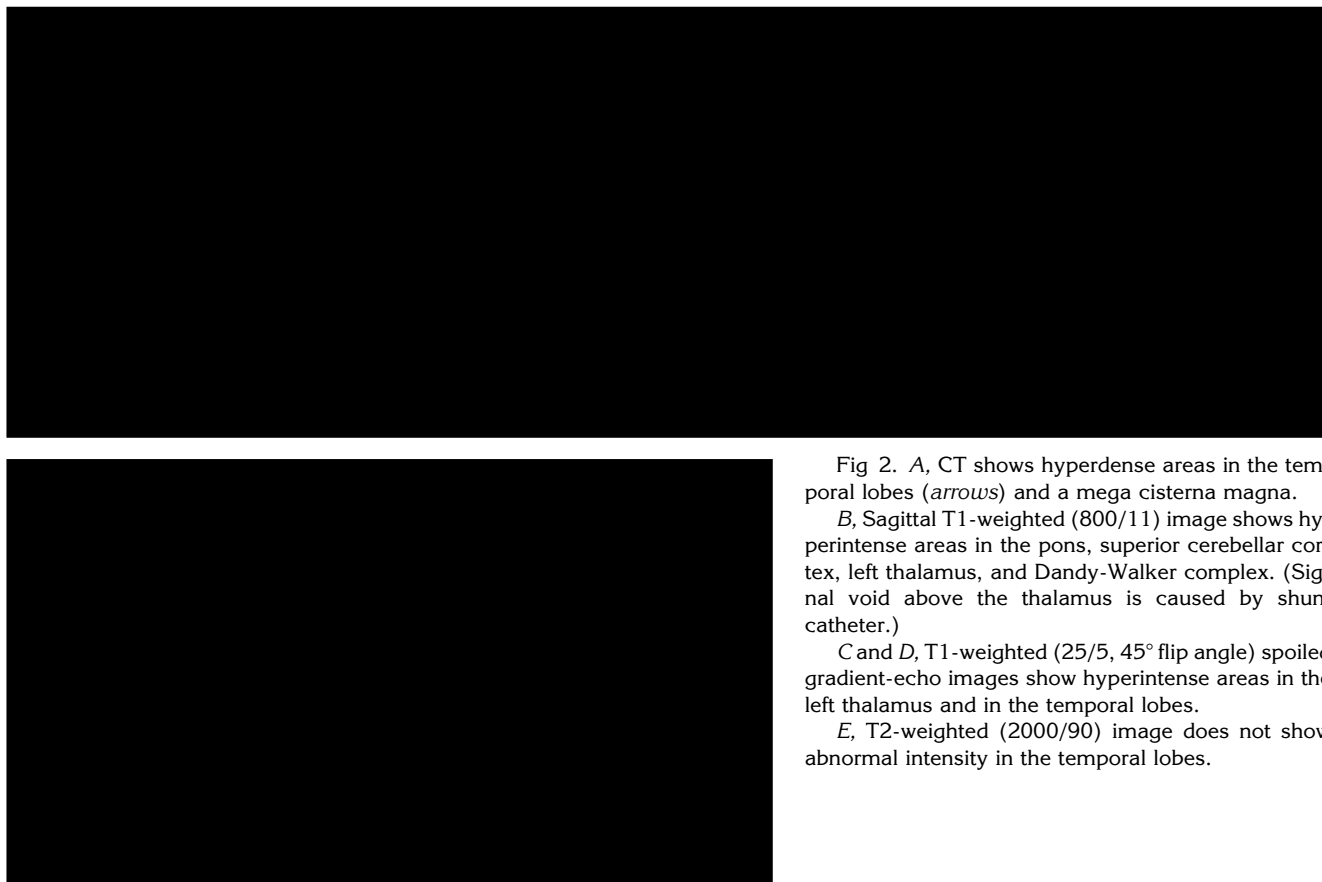


Fig 2. *A*, CT shows hyperdense areas in the temporal lobes (*arrows*) and a mega cisterna magna.

B, Sagittal T1-weighted (800/11) image shows hyperintense areas in the pons, superior cerebellar cortex, left thalamus, and Dandy-Walker complex. (Signal void above the thalamus is caused by shunt catheter.)

C and *D*, T1-weighted (25/5, 45° flip angle) spoiled gradient-echo images show hyperintense areas in the left thalamus and in the temporal lobes.

E, T2-weighted (2000/90) image does not show abnormal intensity in the temporal lobes.

high frequency of malignant melanoma development, if shunt placement is required, a filter is generally placed within the catheter to prevent seeding (10).

Melanocytes that originate from neural crest are normally found within the basal layer of the epidermis, pia mater, reticular formation of the medulla, and substantia nigra (11). The pial melanocytes are more prominent on the inferior surfaces of the cerebellum, frontal, temporal, and occipital lobes, ventral aspect of the medulla, pons, cerebral peduncles, and upper cervical cord (10). Sometimes they may be seen macroscopically, even in healthy patients.

The melanocytes within the pia mater are responsible for the development of leptomeningeal melanosis. The dura is generally spared. Pigmented thickening of the leptomeninges is most frequent in the areas of physiologic melanocytic distribution. Diffuse intracranial leptomeningeal, intraspinal leptomeningeal, ventricular ependymal, and choroid plexus involvement also may occur (2).

The cerebral parenchyma may be primarily or secondarily involved. Primary involvement

may be caused by melanin-containing macrophages and melanocytes. Deposition of macrophages alone, without melanocytes, can be manifest as parenchymal pigmentation and has been described in the pons, basal ganglia, thalami, dentate nuclei, cerebellar hemispheres, and the amygdala (1). However, melanocytic infiltration can also occur. In case 1 and in one previous case (5), the pigmented area of the temporal lobe contained not only melanin-loaded macrophages but also melanocytic cells.

Secondary involvement of the cerebral parenchyma occurs from spread via the Virchow-Robin spaces; the deep cerebral parenchyma is usually spared (1).

Our cases and two previously reported parenchymal neurocutaneous melanosis cases (5, 6) defined by MR showed temporal lobe involvement. This may suggest temporal lobe predilection in parenchymal neurocutaneous melanosis.

Spinal involvement may be seen in as many as 20% of cases (3). Diffuse leptomeningeal thickening, arachnoiditis, and secondary syrinx

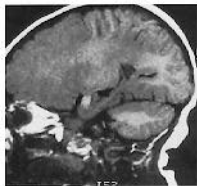gomyelia have been noted (2). Lipoma and arachnoid cyst with leptomeningeal melanosis have also been reported (9, 10).

Abnormal leptomeningeal enhancement has been shown in neurocutaneous melanosis (7). In our two cases abnormal leptomeningeal intensity or enhancement was not detected. Macroscopically negative but microscopically positive melanosis has been reported in 2 cases (2). Our cases appear to be macroscopically free from melanosis based on the absence of abnormal leptomeningeal findings on MR, the absence of any changes on follow-up MR examinations, and the visually normal appearance of the leptomeninges of case 1 during the surgical operation.

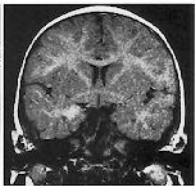
Melanin, which has a paramagnetic effect, shortens T1 and T2 relaxation times, but the cause of this effect is controversial (14, 15). However, some metastatic melanotic melanomas (16) and melanotic neuroectodermal tumors (17) without T1 and T2 shortening have been reported. Leptomeningeal melanosis without detected signal abnormality on precontrast MR have also been reported (7, 8). In our cases, areas of melanin deposition appeared hyperintense on T1-weighted and spin-density images, hyperintense in case 1 and isointense in case 2 on T2-weighted images. The hyperintense appearance on T2-weighted images in case 1 could be caused by reactive gliosis. The isointense appearance on T2-weighted images in case 2 may be attributable to the fact that the T2 shortening effect is less prominent than the T1 effect in lower concentrations. Hypointense appearance on T2-weighted images has been reported in one case (5).

References

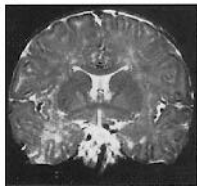
1. Fox H, Emery JL, Goodbody RA, Yates PO. Neuro-cutaneous melanosis. *Arch Dis Child* 1964;39:508-516
2. Leaney BJ, Rowe PW, Klug GL. Neurocutaneous melanosis with hydrocephalus and syringomyelia. *J Neurosurg* 1985;62:148-152
3. Fox H. Neurocutaneous melanosis. In: Vinken PJ, Bruyn GW, eds. *Handbook of Clinical Neurology*. New York: Elsevier, 1972:414-428
4. Kaplan AM, Itabashi HH, Hanelin LG, Lu AT. Neurocutaneous melanosis with malignant leptomeningeal melanoma. *Arch Neurol* 1975;32:669-671
5. Sebag G, Dubois J, Pfister P, Brunelle F, St-Rose C. Neurocutaneous melanosis and temporal lobe tumor in a child: MR study. *AJNR Am J Neuroradiol* 1991;12:699-700
6. Kadonaga JN, Barkovich AJ, Edwards MSB, Frieden IJ. Neurocutaneous melanosis in association with the Dandy-Walker complex. *Pediatr Dermatol* 1992;9:137-143
7. Rhodes RE, Friedman HS, Hatten HP, Hockenberger B, Oakes WJ, Tomita T. Contrast-enhanced MR imaging of neurocutaneous melanosis. *AJNR Am J Neuroradiol* 1991;12:380-382
8. van Heuzen EP, Kaiser MC, de Slegte RGM. Neurocutaneous melanosis associated with intraspinal lipoma. *Neuroradiology* 1989;31:349-351
9. Kasantikul V, Shuangshoti S, Pattanaruenglai A, Kaoroptham S. Intraspinal melanotic arachnoid cyst and lipoma in neurocutaneous melanosis. *Surg Neurol* 1989;138-141
10. Faillace WJ, Okawara S, McDonald JV. Neurocutaneous melanosis with extensive intracerebral and spinal cord involvement: report of two cases. *J Neurosurg* 1984;61:782-785
11. Humes RA, Roskamp J, Eisenbrey AB. Melanosis and hydrocephalus: report of four cases. *J Neurosurg* 1984;61:365-368
12. Narayanan HS, Gandhi DH, Girimaji SR. Neurocutaneous melanosis associated with Dandy-Walker syndrome. *Clin Neurol Neurosurg* 1987;89:197-200
13. Barkovich AJ, Kjos BO, Norman D, Edwards MS. Revised classification of posterior fossa cysts and cystlike malformations based on the results of multiplanar MR imaging. *AJNR Am J Neuroradiol* 1989;10:977-988
14. Enochs WS, Hyslop WB, Bennett HF, Brown RD, Koenig SH, Swartz HM. Sources of the increased longitudinal relaxation rates observed in melanotic melanoma: an in vitro study of synthetic melanins. *Invest Radiol* 1989;24:794-804
15. Atlas SW, Braffman BH, LoBrutto R, Elder DE, Herlyn D. Human malignant melanomas with varying degrees of melanin content in nude mice: MR imaging, histopathology, and electron paramagnetic resonance. *J Comput Assist Tomogr* 1990;14:547-554
16. Woodruff WW, Djang WT, McLendon RE, Heinz ER, Voorhees DR. Intracerebral malignant melanoma: high-field strength MR imaging. *Radiology* 1987;165:209-213
17. Mirich DR, Blaser SI, Harwood-Nash DC, Armstrong DC, Becker LE, Posnick JC. Melanotic neuroectodermal tumor of infancy: clinical, radiologic, and pathologic findings in five cases. *AJNR Am J Neuroradiol* 1991;12:689-697



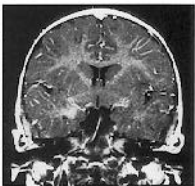
A



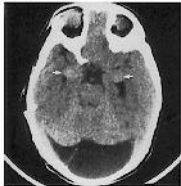B



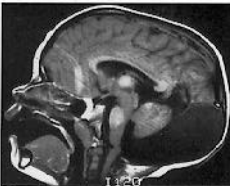
C



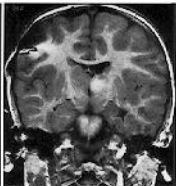
D



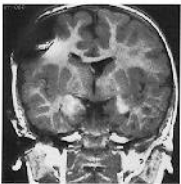
A



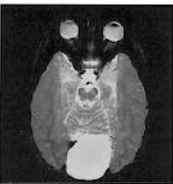B



C



D



E