



Discover Generics

Cost-Effective CT & MRI Contrast Agents



WATCH VIDEO

AJNR

Clinical use of mechanical detachable coils for dural arteriovenous fistula.

T Terada, Y Kinoshita, H Yokote, M Tsuura, Y Tanaka, T Itakura, Y Ryujin, S Hayashi and J Minamikawa

AJNR Am J Neuroradiol 1996, 17 (7) 1343-1348

<http://www.ajnr.org/content/17/7/1343>

This information is current as of June 1, 2025.

Clinical Use of Mechanical Detachable Coils for Dural Arteriovenous Fistula

T. Terada, Y. Kinoshita, H. Yokote, M. Tsuura, Y. Tanaka, T. Itakura, Y. Ryujin, S. Hayashi, and J. Minamikawa

Summary: Seven dural arteriovenous fistulas were successfully embolized with mechanical detachable coils. Two lesions were located in the transverse-sigmoid sinus, four in the cavernous sinus, and one in the marginal sinus. All lesions were completely occluded on postembolization angiography. No recurrent symptoms appeared during a mean follow-up period of 11 months. Owing to the length and retrievability of the mechanical detachable coils, embolization was quicker and safer, and coils were packed more densely, than is possible with conventional coils. Coil migration was avoided because coils of the appropriate size were chosen before they were placed.

Index terms: Fistula, arteriovenous; Interventional instruments, coils

Microcoils are now commonly used for the treatment of intracranial aneurysms and dural arteriovenous fistulas (AVFs) (1). However, conventional microcoils lack retrievability, which sometimes results in coil migration or insufficient coil packing of the involved dural sinuses (2). Guglielmi and coworkers developed an electrolytically detachable coil (the GDC) that is retrievable (3, 4). GDCs have made embolization of intracranial aneurysms safer, but these coils still have two drawbacks. One is the time required for coil detachment (up to 30 minutes [5]), and the other is the possibility of embolic debris resulting from electrolytic coil detachment (Halbach VV, Dowd CF, Higashida RT, et al, "Metallic Fragment Emboli Resulting from Treatment with Electrolytically Detachable Coils [GDC]," presented at the Annual Meeting of the American Society of Neuroradiology, Nashville, Tenn, 1994). Newly developed mechanical detachable coils (MDCs) (Target Therapeutics, Fremont, Calif), which are investigational devices and not approved by the Food and Drug Administration, have several

advantages over conventional microcoils and GDCs: namely, retrievability, quick detachment, and no possibility of metallic embolic debris being created during detachment (6). However, reports concerning the use of MDCs for transvenous embolization of dural AVFs are few (6). We present our experience with the use of MDCs for the embolization of seven dural AVFs.

Methods and Representative Cases

Embolization was performed with MDCs in seven patients with dural AVFs. Five lesions were initially treated by transarterial embolization with polyvinyl alcohol particles (ITC, South San Francisco, Calif) before the transvenous coil embolization. Two dural AVFs were located in the transverse-sigmoid sinus, four in the cavernous sinus, and one in the marginal sinus. One transverse-sigmoid dural AVF had previously been embolized with conventional microcoils (Hilal coils, Cook Inc, Bloomington, Ind), but this resulted in incomplete fistula embolization and migration of the one microcoil to the heart. The patient had repeat embolization with MDCs. A profile of each case is presented in the Table.

All procedures were performed by means of fluoroscopy and digital road-mapping functions. Five AVFs were treated by transarterial embolization (before the transvenous embolization) with polyvinyl alcohol particles, which ranged in diameter from 150 to 500 μm . Transfemoral or transjugular approaches were used for transvenous embolization. A Tracker-18 two-tip marker catheter (Target Therapeutics, Fremont, Calif) was navigated into the affected sinus coaxially through a larger guiding catheter. Various sizes of MDCs, ranging from 2 mm \times 4 cm to 8 mm \times 20 cm, were used for embolization. The retrieval function was examined for all MDCs before they were introduced into the catheter. A total of 113 MDCs were used in our seven cases. The range of applied coils was from 2 mm \times 4 cm to 8 mm \times 20 cm. The average number of coils used for each embolization was 16.

Received July 24, 1995; accepted after revision November 1.

From the Departments of Neurological Surgery at Wakayama Medical College, (T.T., Y.K., M.T., Y.T., H.Y., T.I.), Kokuritsu Minami Wakayama Hospital (Y.R., S.H.), and Kishiwada Municipal Hospital (J.M.), Wakayama City, Japan.

Address reprint requests to Tomoaki Terada, MD, Department of Neurological Surgery, Wakayama Medical College, 7 ban-cho 27, Wakayama City, 640 Japan.

AJNR 17:1343-1348, Aug 1996 0195-6108/96/1707-1343 © American Society of Neuroradiology

Seven patients treated with MDCs for treatment of dural AVFs

Patient	Age, y/Sex	Location of AVF	Embolization Route	No. of MDCs used	Complications
1	65/F	L TS-SS	Transarterial and transvenous	13	...
2	59/F	L CS	Transvenous	18	Unraveling and premature detachment
3	63/M	L CS	Transarterial and transvenous	15	Unraveling
4	60/F	L TS-SS	Transarterial and transvenous	9	...
5	63/M	L CS	Transvenous	23	Unraveling
6	60/F	Bilateral CS	Transarterial and transvenous	27	Unraveling
7	60/F	R MS	Transarterial and transvenous	8	...
Total				113	

Note.—TS indicates transverse sinus; SS, sigmoid sinus; CS, cavernous sinus; and MS, marginal sinus.

Coil embolization was finished when transarterial angiography documented the disappearance of the AVF or when insertion of additional MDCs into the fistulous compartment became impossible.

Case 1

A 65-year-old woman with a left transverse-sigmoid dural AVF with proximal left sigmoid sinus occlusion was admitted to our hospital for treatment (Fig 1A). The AVF was treated by transvenous embolization with conventional microcoils, but the coil migrated to the heart (Fig 1B). A pulmonary embolism occurred on the seventh day, after which the patient was given anticoagulants for 4 months. Subsequent transarterial embolization of the left occipital artery was attempted by using polyvinyl alcohol particles, which resulted in temporary improvement of the patient's tinnitus. The second transvenous embolization was tried by using MDCs and resulted in a complete cure (Fig 1C and D).

Case 4

A 60-year-old woman with pulsatile tinnitus had angiography that showed a left transverse-sigmoid dural AVF with left distal transverse sinus occlusion and stenosis of the distal left internal jugular vein (Fig 2A and B). Transarterial embolization with polyvinyl alcohol particles (diameter range, 500 to 710 μ m) was performed to decrease the shunt flow for the left occipital artery, which is a main feeding artery and safely accessible. A 5F guiding catheter was introduced into the left internal jugular vein and a Tracker-18 microcatheter was introduced into the involved dural sinus segment. The fistulous portion was located at the transverse-sigmoid junction, forming a small venous pouch. This portion was embolized with MDCs that were 2 mm \times 4 cm and 4 mm \times 8 cm in size. An 8-mm \times 20-cm MDC was inserted into the proximal sigmoid sinus before insertion of a 4-mm \times 8-cm coil to prevent migration of the smaller coil. Five 2-mm \times 4-cm coils, one 4-mm \times 8-cm coil, and three 8-mm \times 20-cm coils were

used, resulting in complete embolization of the dural AVF (Fig 2C and D).

Case 6

A 60-year-old woman with a carotid cavernous fistula presented with tinnitus. Bilateral periorbital and posterior auricular bruits were audible. Bilateral cavernous sinus fistulas were present at angiography (Fig 3A and B). A Tracker-18 two-tip marker catheter was navigated into the left cavernous sinus via the right transfemoral and transpetrosal routes. Both cavernous sinuses were packed with variously sized MDCs from left to right. The fistula appeared occluded on angiograms obtained immediately after embolization (Fig 3C and D). One 6-mm \times 20-cm coil unraveled during the retrieval procedure, but was successfully withdrawn.

Results

All dural AVFs were embolized successfully with MDCs. Two lesions were completely occluded immediately after embolization. Complete occlusion of the remaining five AVFs was confirmed by follow-up angiography. Four MDCs unraveled during attempted coil retrieval. Three of these coils were easily retrieved, but one prematurely detached inside the catheter. A snare wire was necessary to retrieve this coil. The particulars for all cases are given in the Table.

Deliverability of MDCs

All MDCs were easily delivered into the fistulous portion of the affected dural sinuses. If the volume of coils was larger than the fistulous space, it was difficult to extrude the entire coil from the catheter. In such cases, coils were retrieved and exchanged for smaller ones.

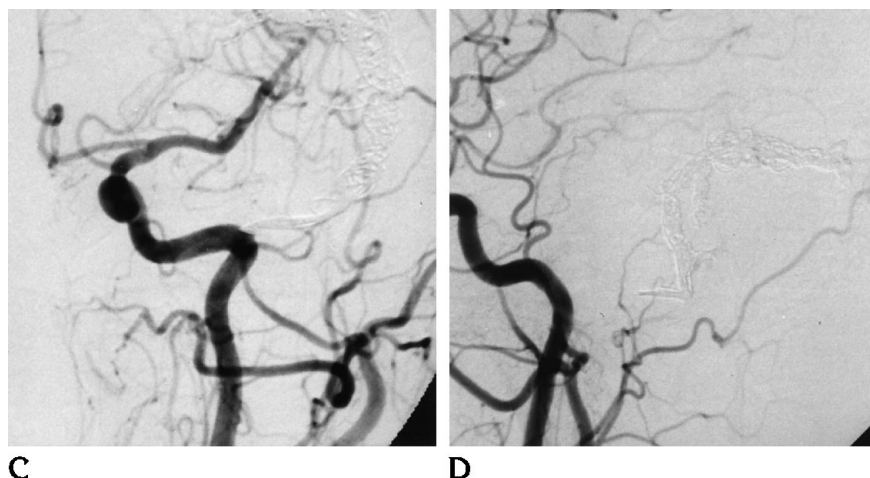
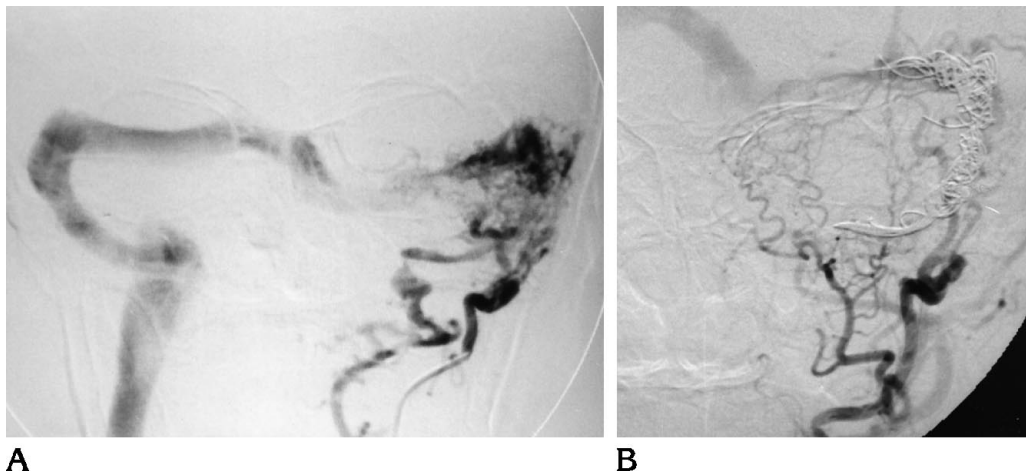


Fig 1. Case 1: 65-year-old woman with a left transverse-sigmoid dural arteriovenous fistula (AVF).

A, Anteroposterior view of left occipital angiogram obtained before embolization shows a dural arteriovenous malformation at the transverse-sigmoid sinus. The main feeding artery is the left occipital artery. The left proximal sigmoid sinus was partially occluded, and shunt flow was directed to the contralateral transverse sinus.

B, Anteroposterior view of left external carotid angiogram after embolization shows the left transverse-sigmoid sinus was occluded by microcoils, although the dural AVF was still patent.

C, Anteroposterior view of left common

carotid angiogram after embolization with mechanical detachable coils (MDCs) show that the dural AVF has completely disappeared.

D, Lateral view of left common carotid angiogram after embolization with MDCs.

When coils were detached, the distal end (interlocking portion) of the pusher sometimes hooked previously detached coils. In these instances, the pusher was easily retrieved by gently pushing and rotating this device.

Coil Positioning

Each coil was positioned accurately to obliterate the involved dural sinus segment fully. Because of their retrievability, coils were repositioned until they were in the optimal location. In cases of dural AVFs of the cavernous sinus, venous drainage channels—including the sphenoparietal sinus, the ophthalmic vein, and the entire cavernous sinus—were packed with MDCs. These procedures were finished more quickly than those involving conventional microcoils, owing to the longer length of the MDCs.

Coil Stability

None of the MDCs changed their position, and all demonstrated good stability at the fistulous sites. In two cases of transverse-sigmoid dural AVFs, MDCs of an appropriate size were first partially deployed and then examined for stability. We judged a coil to be stable if its diameter was slightly larger than the sinus and it did not move after a few minutes' observation before detachment. If a coil was stable in an appropriate portion of the fistula, it was detached. Larger coils served as a nest for smaller MDCs, allowing denser coil packing of the involved dural sinus.

Complications

Four MDCs unraveled during repeated insertion and retrieval. Three of them were easily

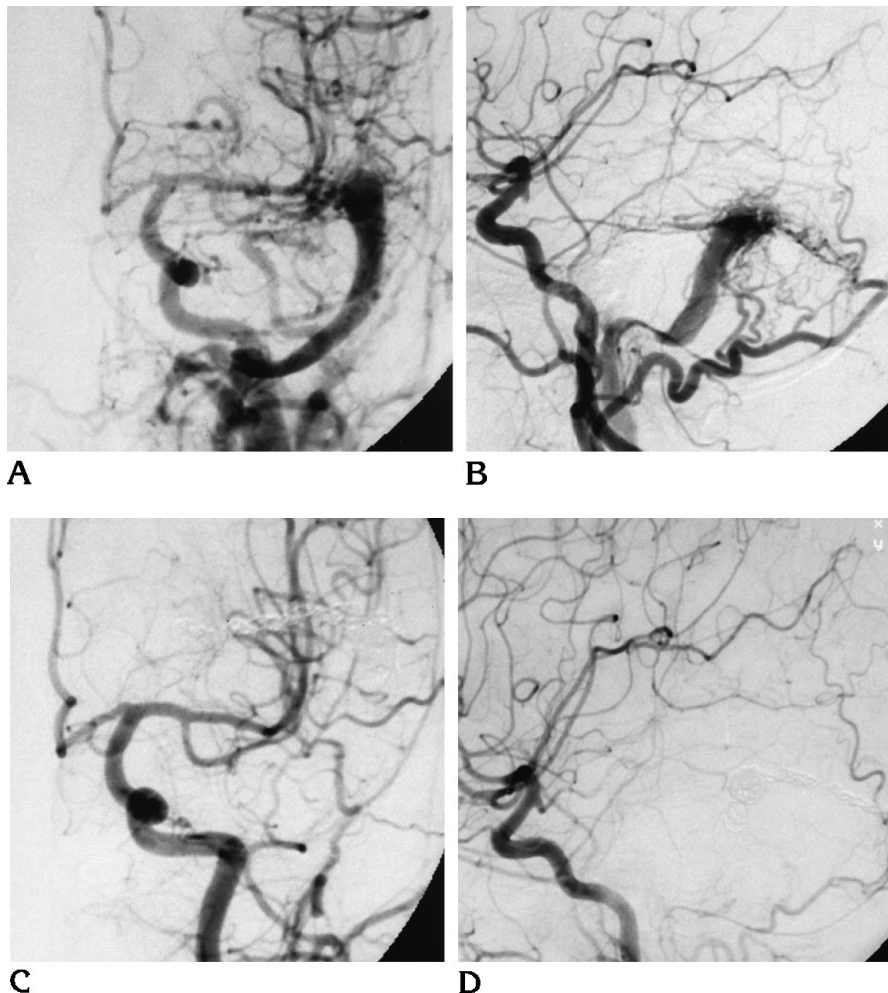
Fig 2. Case 4: 60-year-old woman with a left transverse-sigmoid dural arteriovenous fistula (AVF).

A, Anteroposterior view of left common carotid angiogram shows a left transverse-sigmoid dural AVF. The left distal transverse sinus is occluded and the distal internal jugular vein is stenosed.

B, Lateral view of left common carotid angiogram.

C, Anteroposterior view of left common carotid angiogram after embolization shows that the dural AVF has completely disappeared.

D, Lateral view of left common carotid angiogram after embolization.



retrieved, but one detached inside the catheter. A snare wire was necessary to retrieve this prematurely detached coil.

Follow-up Results

The average follow-up period for the seven patients was 11 months (range, 5 to 15 months). Angiographic disappearance of an AVF was confirmed immediately after embolization in two patients, 1 week after embolization in three patients, 7 months after embolization in one patient, and 5 months after embolization in one patient. No recurrence of symptoms was noted in any of these cases.

Discussion

The transvenous approach for the treatment of dural AVFs was described by Halbach et al (7); it is now accepted as the standard treat-

ment for these lesions. Coils are normally used for the occlusion of venous outflow, and micro-coils with or without fibers are used for the transvenous embolization of dural AVFs. Ordinarily, these coils work well to occlude AVFs (7). However, one of the pitfalls of these devices is coil migration (2), especially in the case of high-flow dural AVFs, as in our case 1. Another pitfall is inaccurate coil positioning distant from the fistulous site. In this regard, MDCs have several advantages over conventional micro-coils (6), the most important being their retrievability. This feature allows accurate and tight coil packing with less chance of coil migration. Also, because of the longer length of MDCs, complete occlusion of a target venous space can be achieved more rapidly.

Fibered platinum coils are believed to be more thrombogenic than bare platinum coils (5). And although MDCs are composed of bare platinum coils and may be less thrombogenic,

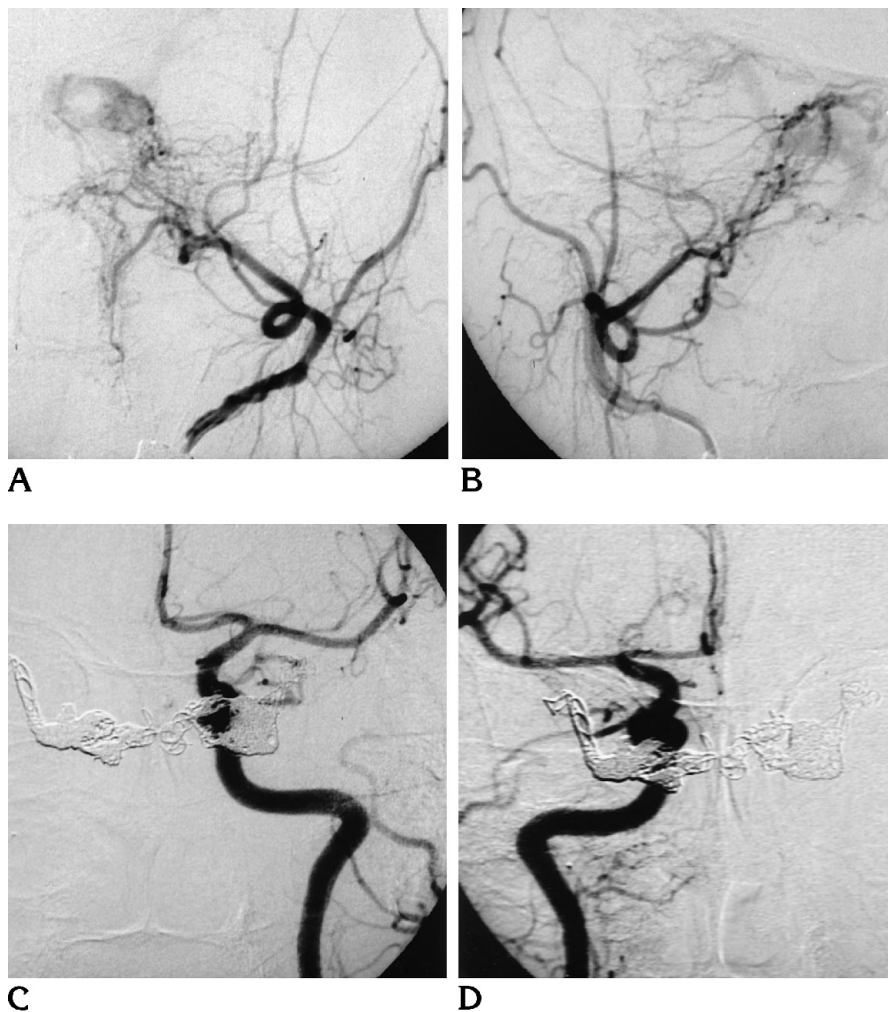


Fig 3. Case 6: 60-year-old woman with a carotid cavernous fistula.

A, Anteroposterior view of left external carotid angiogram obtained before embolization shows the left cavernous sinus is opacified in the arterial phase.

B, Anteroposterior view of right external carotid angiogram before embolization shows the right cavernous sinus is opacified in the arterial phase.

C, Anteroposterior view of left common carotid angiogram after embolization shows the carotid cavernous fistula has completely disappeared.

D, Anteroposterior view of right common carotid angiogram after embolization shows the carotid cavernous fistula has completely disappeared.

accurate and compact packing allows complete obliteration of fistulas, as demonstrated in our cases, which were all completely occluded after embolization.

As compared with GDCs, MDCs have both advantages and disadvantages. The advantages are their rapid detachment and lack of generation of metal emboli during detachment (Halbach VV et al, "Metallic Fragment Emboli"). The disadvantages are their possible premature detachment and unraveling during deployment (although the latter complication also occurs with GDCs). In our cases, unraveling of MDCs occurred when coils were already inserted into the sinus, when a coil was resistant to being introduced into the lesion, when a coil was resistant to retrieval, and when large coils (6 mm \times 20 cm to 8 mm \times 20 cm) were used. We think that newly introduced coils may become tangled with other coils, making them difficult to retrieve and susceptible to unraveling. The

longer coils are more likely to become tangled and to unravel. If coils do unravel, fixation of their interlocking portion becomes unstable. Premature detachment is thought to happen when unraveled MDCs pass through a sharp vascular bend. It is important to change to shorter coils to prevent unraveling when coil insertion becomes difficult and always to be prepared for this eventuality. Another disadvantage of MDCs is the hard interlocking joint located at the end of the coil that may potentially injure a vessel wall during coil detachment. This is a major drawback in the use of MDCs for the treatment of cerebral aneurysms.

We treated seven cases of dural AVFs using only MDCs except for one case previously embolized with Hilal coils. For cases of carotid cavernous fistulas, MDCs do not seem to be more effective than conventional microcoils, except for reducing the duration of the embolization procedure by virtue of the longer length

of the MDCs. However, for cases of high-flow fistulas with large sinus spaces, such as dural AVFs of the transverse-sigmoid or marginal sinus, MDCs, because of their retrievability, were effective for stabilizing the initial coil and for ascertaining correct coil size.

References

1. Hodes JE, Aymard A, Gobin YP, et al. Endovascular occlusion of intracranial vessels for curative treatment of unclippable aneurysms: report of 16 cases. *J Neurosurg* 1992;75:694-701
2. Numaguchi Y, Pevsner PH, Rigamonti D, Ragheb J. Platinum coil treatment of complex aneurysms of the vertebrobasilar circulation. *Neuroradiology* 1992;34:252-255
3. Guglielmi G, Vinuela F, Duckwiler G, et al. Endovascular treatment of posterior circulation aneurysms by electrothrombosis using electrically detachable coils. *J Neurosurg* 1992;77:515-524
4. Sadato A, Taki W, Nishi S, Yamashita K, Kikuchi H, Ikada Y. Treatment of spontaneous carotid cavernous fistula using an electrodetachable microcoil. *AJNR Am J Neuroradiol* 1993;14:334-336
5. Graves VB, Strother CM, Rappe AH. Treatment of experimental canine carotid aneurysms with platinum coils. *AJNR Am J Neuroradiol* 1993;14:787-793
6. Yoshimura S, Hashimoto N, Kazekawa K, Nishi S, Sampei K. Embolization of dural arteriovenous fistulas with interlocking detachable coils. *AJNR Am J Neuroradiol* 1995;16:322-324
7. Halbach VV, Higashida RT, Hieshima GB, Mehringer CM, Hardin CW. Transvenous embolization of dural fistulas involving the transverse and sigmoid sinuses. *AJNR Am J Neuroradiol* 1989;10:385-392