



Discover Generics

Cost-Effective CT & MRI Contrast Agents

 FRESENIUS
KABI

[WATCH VIDEO](#)

AJNR

CT in adult supraglottitis.

M M Smith, S K Mukherji, J E Thompson and M Castillo

AJNR Am J Neuroradiol 1996, 17 (7) 1355-1358

<http://www.ajnr.org/content/17/7/1355>

This information is current as
of June 1, 2025.

CT in Adult Supraglottitis

Michelle M. Smith, Suresh K. Mukherji, Jill E. Thompson, and Mauricio Castillo

Summary: We describe the CT appearance of supraglottitis and its complications in three adults. The most common CT findings were thickening of the epiglottis, aryepiglottic folds, false and true vocal cords, obliteration of the preepiglottic fat, thickening of the platysma muscle, and reticulation of the subcutaneous fat. Multiple loculated fluid-density collections consistent with abscesses were seen in one patient. Although the diagnosis of supraglottitis is generally made on the basis of the patient's history and by direct endoscopy, CT may be used to confirm the diagnosis when an adequate laryngoscopic examination cannot be performed. CT is also useful in evaluating the complications of this disorder.

Index terms: Larynx, epiglottitis; Neck, inflammation

Adult epiglottitis, more appropriately referred to as *supraglottitis*, should be considered in the differential diagnosis of any adult patient who presents with sore throat and dysphagia. Supraglottitis is relatively uncommon, but it may be potentially life-threatening. In the majority of patients, the diagnosis is based on the clinical history and physical examination, and occasionally with the help of radiographs of the soft tissues of the neck (1). Because the symptoms of supraglottitis can be nonspecific, computed tomography (CT) can be helpful in excluding other conditions that may be accompanied by similar symptoms, such as peritonsillar abscess, abscesses of the deep neck space, lingual tonsillitis, laryngitis, or an ingested foreign body. CT is also useful in identifying complications of supraglottitis, such as abscess formation. The purpose of this article is to describe the spectrum of CT findings in three patients with supraglottitis.

Case Reports

Case 1

A 49-year-old woman had a 1-day history of increasing sore throat, odynophagia, and pain and swelling in the

right anterior portion of the neck. On admission, she was afebrile and had swelling, tenderness, and erythema throughout the neck. A tender mass, measuring 7×4 cm, was palpated in the right side of the neck anterior to the sternocleidomastoid muscle. Nasopharyngoscopy revealed diffuse erythema with significant edema of the epiglottis, aryepiglottic folds, and false vocal cords, consistent with supraglottitis. The true cords were minimally edematous. Laboratory findings included a white blood cell count of $23.8 \times 10^9/L$ and nasopharyngeal culture with $4+$ *Haemophilus influenzae*. A test for the human immunodeficiency virus (HIV) was negative. The patient was stable without airway compromise.

Contrast-enhanced CT was performed to differentiate abscess from cervical adenitis in the right side of the neck. CT scans, extending from the base of the skull to the thoracic inlet, were obtained with 3-mm-thick sections with a 2-mm gap. CT findings revealed diffuse thickening of the epiglottis, aryepiglottic folds, false vocal cords, posterior pharyngeal wall, and platysma muscle (Fig 1A). Edema was seen in the retropharyngeal space and subcutaneous fat. No focal abscesses were identified (Fig 1B).

The patient was treated with intravenous clindamycin and solumedrol. Her course was complicated by bilateral pleural effusions from which *H influenzae* was cultured. The effusions were treated with thoracostomy tubes and intravenous cefotaxime. She was discharged after 12 days on oral ciprofloxacin. There was no residual throat or chest pain.

Case 2

A 22 year-old man presented after 4 days of progressive throat swelling, dysphagia, odynophagia, and difficulty handling secretions. He was afebrile, unable to speak, and could not lie supine. On physical examination the patient had trismus, which prevented examination of the airway. There was swelling and erythema of the neck. Laboratory results included a white blood cell count of $24.5 \times 10^9/L$. Cultures of the oropharynx and nasopharynx grew oropharyngeal flora and blood cultures were negative. A test for HIV was negative.

The patient was taken to the operating room, where a tracheostomy was performed under local anesthesia. Laryngoscopy showed marked swelling of the epiglottis and

Received August 14, 1995; accepted after revision November 2.

From the Department of Radiology, University of North Carolina School of Medicine, Chapel Hill.

Address reprint requests to M. Castillo, MD, CB# 7510, Radiology, University of North Carolina, Chapel Hill, NC 27599.

AJNR 17:1355-1358, Aug 1996 0195-6108/96/1707-1355 © American Society of Neuroradiology

Fig 1. A, Axial contrast-enhanced CT scan at the level of the hyoid bone shows marked thickening of the aryepiglottic folds (f), posterior pharyngeal wall, and platysma muscle (arrow).

B, Edema is seen in the retropharyngeal space extending to the carotid arteries bilaterally (asterisks) and in the subcutaneous fat. There is obliteration of the paraglottic fat planes and thickening of the false vocal cords (V).

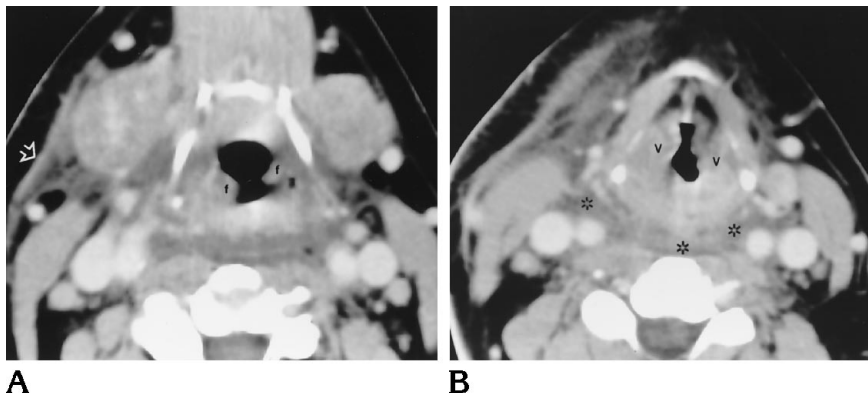
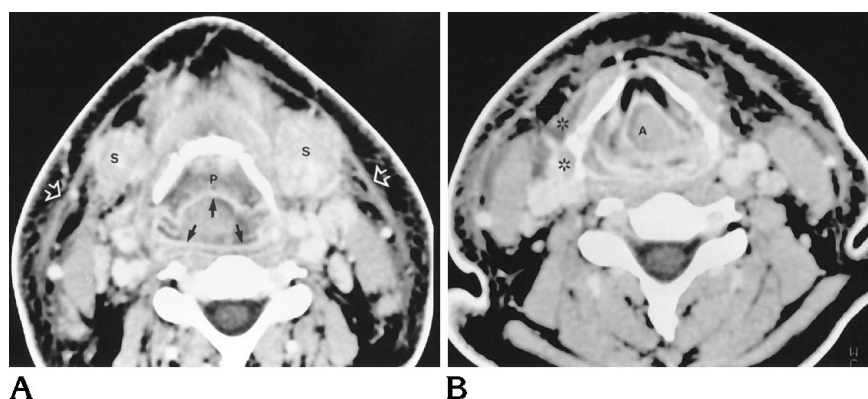


Fig 2. A, Axial postcontrast CT scan shows marked enhancement of the pharyngeal mucosa (black arrows) and submandibular glands (S). There is thickening of the platysma muscle (white arrows) and reticulation of the subcutaneous fat. The preepiglottic fat is obscured by edema (P).

B, Again, CT scan shows marked enhancement of the pharyngeal mucosa, thickening of the platysma muscle, and reticulation of the subcutaneous fat. Low attenuation is seen anterolateral to the sternocleidomastoid muscles and about the strap muscles on the right (asterisks), most likely corresponding to edema or early abscess formation. Secretions fill the airway (A).



supraglottic structures, confirming the diagnosis of supraglottitis. CT (same protocol as for case 1) was performed to exclude a retropharyngeal abscess. CT scans showed diffuse thickening of the epiglottis, aryepiglottic folds, false and true vocal cords, and prevertebral fascia (Fig 2A). The preepiglottic fat was obliterated, and edema was seen in the soft tissues bordering the larynx. The platysma muscle was diffusely thickened, and there was reticulation of the subcutaneous fat (Fig 2A). Small areas of low attenuation were seen lateral to the left submandibular gland and superficial to the right sternocleidomastoid muscle. These were thought to represent edema or early abscesses (Fig 2B). There were no retropharyngeal abscesses.

After 4 days of treatment with broad-spectrum intravenous antibiotics, including vancomycin, metronidazole, and cefotaxime, a decrease in oropharyngeal swelling and erythema was noted. The tracheostomy tube was removed on the 5th day after admission. On day 8, the patient was discharged on oral ciprofloxacin and clindamycin. Three weeks after discharge, the patient was asymptomatic and without evidence of recurrent disease.

Case 3

A 36-year-old man awoke with a sore throat. Over the next 4 hours, the pain became severe and he could no

longer swallow his secretions. Laryngoscopy showed marked swelling of the epiglottis to three times its normal size and swelling of the aryepiglottic folds consistent with supraglottitis. The white blood cell count was $13.3 \times 10^9/L$. Cultures of the epiglottis grew β -lactamase-negative *H influenzae*. Blood cultures were negative, as was a test for HIV.

Owing to airway compromise, the patient was intubated and was treated with intravenous solumedrol and cefuroxime. Over the next 48 hours, the patient improved and was extubated. On the 4th day after admission, progressive pain, swelling, and trismus developed in the right side of the neck and the left supraclavicular area. CT (same protocol as for case 1) was performed to exclude an abscess. The study showed thickening of the epiglottis, aryepiglottic folds, and platysma muscle (Fig 3A); there was reticulation in the subcutaneous fat; and edema was seen in the retropharyngeal space extending laterally to the right carotid artery. Several focal collections with enhancing rims, consistent with abscesses, extended along the fascial planes of the neck. The dominant collection extended from the right submandibular space inferiorly along the sternocleidomastoid muscle (Fig 3A). Multiple smaller collections were seen anterior to the thyroid cartilage anterior the strap muscles. Abscesses were also seen

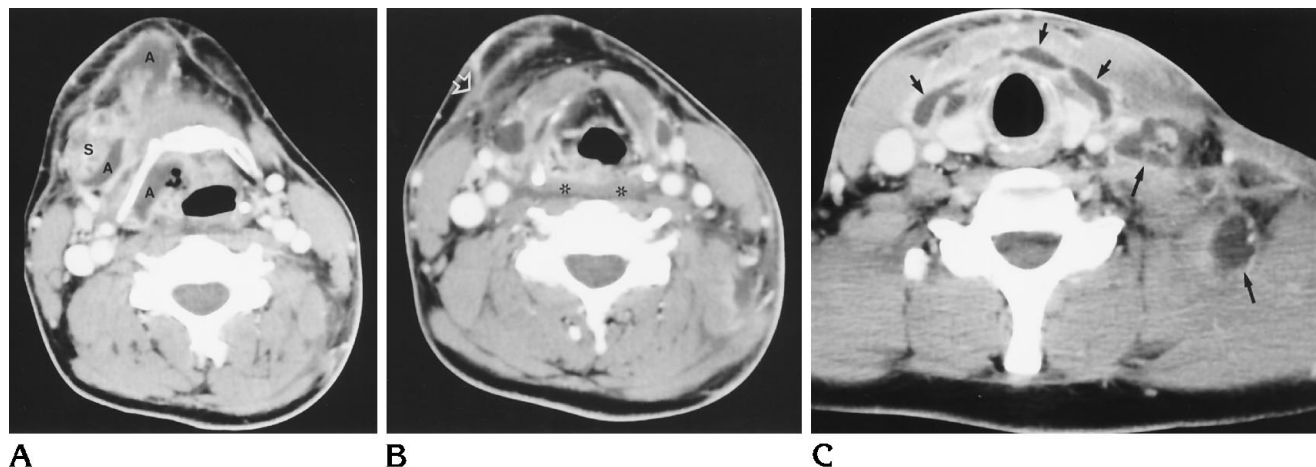


Fig 3. A, Axial contrast-enhanced CT scan at the level of the hyoid bone shows thickening of the epiglottis. Small abscesses (A) are seen medial to the right submandibular gland (S) and in the right anterior portion of the neck.

B, At the level of the thyroid cartilage, there is thickening of the platysma muscle (arrow) and reticulation of subcutaneous fat. Edema is present in the retropharyngeal space and extends to the carotid artery on the right (asterisks).

C, Focal collections with enhancing rims are seen deep to the strap muscles (short arrows) and in the left supraclavicular region (long arrows).

in the left supraclavicular region with extension into the mediastinum (Fig 3B and C).

The multiple fluid collections were drained, and the patient was discharged 3 weeks later on oral metronidazole. He was doing well on a follow-up visit to the clinic 3 weeks later.

Discussion

Adult supraglottitis is a relatively rare, yet potentially life-threatening condition. The term *supraglottitis* refers to a disease in adults that may involve the prevertebral soft tissues, valleculae, uvula, base of the tongue, and soft palate (2). Classically, supraglottitis is thought of as a childhood illness caused by *H influenzae*. Recent reports show that only a minority of adult cases are caused by this organism (3). Other organisms that have been implicated in adult supraglottitis include group A and group F β -hemolytic *Streptococcus pyogenes* and *Staphylococcus aureus* (4). In two of our patients (cases 2 and 3), cultures were positive for *H influenzae*, whereas no organism was isolated in one patient (case 2).

A diagnosis of supraglottitis should be considered in any adult presenting with a sore throat and dysphagia. Other symptoms include odynophagia, stridor, muffled voice, and difficulty handling secretions (drooling). Fever and elevated white blood cell count are nearly universal in these patients. Supraglottitis in adults has a more variable presentation and indolent

course than in children. In most adults, symptoms do not progress to include airway obstruction that requires intervention, possibly because of the larger diameter and greater rigidity of the adult airway (5). Clinically, the differential diagnosis includes pharyngitis, quinsy (peritonsillar abscess), abscesses in the deep neck space, lingual tonsillitis, ingested foreign body with or without perforation and abscess, and laryngitis (6). *Laryngitis* specifically refers to inflammation of the laryngeal mucosa and vocal cords, resulting in hoarseness, whereas *supraglottitis* refers to inflammation and swelling of the supraglottis and is a more severe condition associated with a higher risk of airway compromise. In the majority of cases, supraglottitis is diagnosed by history and findings on flexible laryngoscopy.

Recently, there has been an apparent increase in adult cases relative to pediatric cases. The incidence of acute supraglottitis in adults has remained stable over the past 11 years (approximately 1.8 cases per 100 000 adults) whereas the incidence in children has dramatically decreased. This is most likely related to routine immunization of children with *H influenzae* vaccine since April 1985 (3). Because it is necessary to examine the larynx to establish a correct diagnosis, the incidence of supraglottitis in adults is probably underestimated (7). Supraglottitis has been reported to occur in patients with acquired immunodeficiency syndrome

(AIDS). Although the disorder is believed to arise from similar pathogens in AIDS patients, it has a more aggressive course (8). AIDS patients are known to be predisposed to the development of emphysematous epiglottitis.

Lateral neck radiographs can be helpful in diagnosing adult supraglottitis. The radiologic manifestations of supraglottitis in 27 adults were reviewed recently (1). Findings include minimal to massive enlargement of the epiglottis, enlarged aryepiglottic folds and arytenoids, prevertebral soft-tissue swelling, and ballooning of the hypopharynx. Plain radiographic findings in adults are more subtle than those in children, and, at times, the configuration of the epiglottis remains normal, making the diagnosis of supraglottitis difficult.

CT may be used in the evaluation of adult supraglottitis. This imaging method is helpful in patients who are unable to undergo adequate physical examination; however, it should be limited to patients who have a stable airway. CT is not recommended to establish the diagnosis of supraglottitis initially, but rather to exclude complications, such as abscesses. CT findings in our cases included swelling of the supraglottis, obliteration of surrounding fat planes, and thickening of the platysma muscle and prevertebral fascia. These findings are similar to those found in patients who have received radiation therapy to the neck. Two of our patients had thickening of the false vocal cords, marked pharyngeal mucosal enhancement, retropharyngeal space edema, and obliteration of the preepiglottic fat. CT scans showed the extent of multiple abscesses in one patient, which directed appropriate surgical management.

Current treatment of adult supraglottitis includes medical therapy and airway management. Medical treatment consists of humidification, intravenous hydration, and intravenous antibiotics (6). Historically, ampicillin has been used; however, second-generation cephalosporins are now recommended owing to the increasing prevalence of β -lactamase, producing

H influenzae (9). Intravenous steroids may also be administered to reduce inflammation, but their use is controversial (6). Airway management in adult supraglottitis is controversial and includes observation, intubation, and tracheostomy (7, 10). In a recent study of 46 adult cases, 15% required tracheostomy (7). Several prognostic factors have been associated with increased likelihood of airway compromise, including rapid progression of symptoms, increased heart rate, and elevation of the white blood cell count (7). Most cases of uncomplicated supraglottitis resolve quickly with medical management and require only short hospital stays.

In conclusion, the CT findings of supraglottitis in three adult patients have been described. Although CT is not recommended as the primary means of establishing a diagnosis, it is indicated in patients in whom direct inspection of the airway is not possible.

References

1. Nemzek WR, Katzberg RW, Van Slyke MA, et al. A reappraisal of the radiologic findings of acute inflammation of the epiglottis and supraglottic structures in adults. *AJNR Am J Neuroradiol* 1995; 16:495-502
2. Rothcock SG, Pignatiello GA, Howard RM. Radiologic diagnosis of epiglottitis: objective criteria for all ages. *Ann Emerg Med* 1990; 19:978-982
3. MayoSmith MF, Hirsch PJ, Wodzinski SF, et al. Acute epiglottitis in adults: an eight-year experience in the state of Rhode Island. *N Engl J Med* 1986;314:1133-1139
4. Shih L, Hawkins DB, Stanley RB. Acute epiglottitis in adults: a review of 48 cases. *Ann Otol Rhinol Laryngol* 1988;97:527-529
5. Deeb ZE, Yenson AC, DeFries HO. Acute epiglottitis in the adult. *Laryngoscope* 1985;95:289-291
6. Smith TL, McQueen CT, Henrich D, et al. Adult supraglottitis. *Ear Nose Throat J* 1995;74:258-260
7. Barrow HN, Vastola AP, Wang RC. Adult supraglottitis. *Otolaryngol Head Neck Surg* 1993;109:474-477
8. Ognibene, FP. Upper and lower airway manifestations of human immunodeficiency virus infection. *Ear Nose Throat J* 1990;69: 451-455
9. Hanna GS. Acute supraglottic laryngitis in adults. *J Laryngol Otol* 1986;100:971-975
10. Schloss MD, Gold JA, Rosales JK, et al. Acute epiglottitis. *Laryngoscope* 1983;93:489-493