

Generic Contrast Agents

Our portfolio is growing to serve you better. Now you have a *choice*.



[VIEW CATALOG](#)

AJNR

Proton MR spectroscopy and neuropsychological testing in adrenoleukodystrophy.

V Rajanayagam, M Balthazor, E G Shapiro, W Krivit, L Lockman and A E Stillman

This information is current as of May 24, 2025.

AJNR Am J Neuroradiol 1997, 18 (10) 1909-1914
<http://www.ajnr.org/content/18/10/1909>

Proton MR Spectroscopy and Neuropsychological Testing in Adrenoleukodystrophy

V. Rajanayagam, M. Balthazor, E. G. Shapiro, W. Krivit, L. Lockman, and A. E. Stillman

PURPOSE: To determine early signs of disease in patients with childhood-onset cerebral adrenoleukodystrophy (COALD) with the use of proton MR spectroscopy. **METHODS:** Eleven children with posterior COALD involvement and three children with anterior COALD involvement were studied with single-voxel proton MR spectroscopy and neuropsychological testing. Findings were compared with those in five healthy control subjects. **RESULTS:** Areas of abnormal T2 signal intensity in children with COALD showed abnormal metabolite ratios relative to those of control subjects as follows: decreased *N*-acetylaspartate (NAA)/Creatine (Cr) and NAA/Choline (Ch) and increased Ch/Cr. Metabolite ratios from normal-appearing brain regions in the same patients also were abnormal, with reduced NAA/Cr and NAA/Ch and increased Ch/Cr values. The mean metabolite ratios in normal-appearing regions were between those in the abnormal regions and those found in the control subjects. Statistical comparison of these ratios with neuropsychological test scores, which are specific for anterior and posterior brain functions, showed a significant correlation with the abnormal metabolite ratios. Our results indicate that the normal-appearing brain regions in these patients are metabolically abnormal. **CONCLUSION:** Proton MR spectroscopy could be a useful noninvasive tool to evaluate extent of disease in patients with COALD.

Index terms: Adrenoleukodystrophy; Children, diseases; Magnetic resonance, spectroscopy

AJNR Am J Neuroradiol 18:1909–1914, November 1997

Adrenoleukodystrophy (ALD) is a cerebral degenerative disease that affects predominantly the white matter (1–5). Boys with childhood-onset cerebral ALD (COALD) have a mean age of onset of 7 years, with demyelination and deterioration progressing rapidly to death over an average of 3 to 4 years. No biochemical test distinguishes between these forms or reflects the degree of deterioration (1, 6). Abnormalities on magnetic resonance (MR) images correlate well with neuropsychological measures (7). However, detection of objective changes on MR

images to ascertain disease progression is difficult (8).

Proton MR spectroscopy has also been used to identify the different levels of cerebral metabolites present in abnormal brain regions in patients with ALD (9–12). Metabolite ratios of patients with ALD differ from those of control subjects. MR spectroscopy has shown promise in the monitoring of disease course and treatment, and metabolite ratios from abnormal brain regions also correlate well with the clinical status of patients with ALD (12).

We present the MR spectroscopic metabolite data accumulated from abnormal and normal-appearing white matter in a small cohort of patients with COALD.

Materials and Methods

The patient group consisted of 14 children, 4 to 13 years old, with the biochemical defect for ALD and with abnormal anterior and posterior regions of white matter on MR images. Of these 14 patients, 11 had posterior involvement and three had anterior involvement. Four patients

Received November 4, 1996; accepted after revision April 21, 1997.

Supported in part by NIH/NINDS grant NS 29–099–05.

Presented in part at the annual meeting of the International Society for Magnetic Resonance in Medicine, New York, NY, April 27 to May 3, 1996.

From the Departments of Radiology (V.R., A.E.S.), Neurology (M.B., E.G.S., L.L.), and Pediatrics (W.K.), University of Minnesota, Minneapolis.

Address reprint requests to Vasanthan Rajanayagam, PhD, Department of Radiology, Box 292, University of Minnesota, 420 Delaware St SE, Minneapolis, MN 55455.

AJNR 18:1909–1914, Nov 1997 0195-6108/97/1810–1909

© American Society of Neuroradiology

had nearly normal MR imaging studies, with only mild involvement in the posterior regions. Five male control subjects (age range, 8 to 35 years) also were studied. These control subjects were not age matched, as the primary changes in the metabolite ratios occur predominantly in the first 2 years of life (13, 14). In addition, and as observed by others, we did not find any significant differences in the metabolite ratios between the child and adult control subjects. Informed consent was obtained from the parents of the patients before the examinations. Nine children were sedated (2 to 6 mg/kg pentobarbital sodium) and monitored using pulse oximetry and an apnea monitor during the MR examination.

All MR studies were done on a 1.5-T imaging unit equipped with shielded gradients and a quadrature head coil. MR imaging consisted of axial, coronal, and sagittal T1-weighted sequences (600/14/2 [repetition time/echo time/excitations]) and axial T2-weighted sequences (2500/45,90/2). This was followed by MR spectroscopy, in which the spectra were acquired using the double spin-echo sequence (15). Single-voxel ($2 \times 2 \times 2 \text{ cm}^3$) water-suppressed spectra were acquired from occipital and frontal white matter regions that appeared both normal and abnormal on MR images. MR spectra from two regions of interest (ROI) were obtained from each patient. Fourteen examinations of abnormal regions (three anterior and 11 posterior) and 12 examinations of normal-appearing regions (nine anterior and three posterior) were performed. The ROIs were prescribed from axial, coronal, and sagittal T1-weighted images. After global and localized shimming, water suppression was optimized and water-suppressed spectra were acquired for each ROI. Water suppression was achieved by application of chemical-shift selective pulses with a bandwidth of 60 Hz followed by gradient spoiling of the excited magnetization. An echo time of 135 enabled the detection of lactate and also simplified spectral overlap, which enabled the acquisition of reliable peak area measurements. Localized spectra were acquired with parameters of 1600/135/256, a 1000-Hz sweep width, and 1024 complex points. The residual water signal was removed by means of time-domain filtering and then apodized and zero-filled to 2048 points before Fourier transformation to obtain the metabolite spectra. The spectra were manually phase corrected then baseline corrected, and the relative peak areas of *N*-acetylaspartate (NAA), total creatine (Cr), and choline-containing compounds (Ch) were determined by spectral peak fitting. The metabolite peak areas were not corrected for T1 and T2 differences.

Yearly neuropsychological tests measuring cognitive, nonverbal, verbal, memory, and attention functions were administered to all our patients with COCALD. Previous research has shown that performance IQ scores from the Wechsler tests of intelligence (16, 17) are particularly sensitive to posterior abnormalities commonly associated with ALD (18). This sensitivity is due to the varied demands on visual processing associated with performance IQ tasks. All subtests, including the optional mazes subtest, were administered. In addition, the test of vari-

ables of attention (TOVA), a "continuous performance" test of attention with several component measures (19), has been found to be sensitive to anterior abnormalities (7, 20). Two component measures were selected: omission errors, which measure vigilance, and reaction time. Thirteen children over the age of 6 years were able to complete the test. These two neuropsychological tests and their component measures were selected for correlation with the MR spectroscopic metabolite ratios.

Statistical analysis using a two-tailed Student's *t* test was performed to compare the means from the different groups. Linear correlations between the MR spectroscopic and the neuropsychological data were performed to determine the associations and the correlation coefficients. Differences were considered significant if *P* values were less than .05. All statistical analysis was done using Statview 4.5 (Abacus Concepts Inc, Berkeley, Calif).

Results

Metabolite Ratios from Abnormal Brain Regions in Patients with ALD

T2-weighted images of patients with ALD with active disease showed characteristic hyperintensity in the demyelinating regions (Fig 1A). Lactate resonance also appeared as an inverted doublet at 1.33 ppm (Fig 1B). The metabolite ratios NAA/Cr, NAA/Ch, and Ch/Cr for this region were 0.73, 0.40, and 1.84, respectively. Table 1 lists the mean values of the metabolite ratios from these abnormal regions in the 14 patients and the corresponding mean metabolite ratios in the five healthy control subjects. The NAA/Cr and NAA/Ch metabolite ratios were lower and the Ch/Cr ratio higher than those of the control subjects. All differences were statistically significant.

Metabolite Ratios from Normal Brain Regions in Patients with ALD

In the normal-appearing brain regions of these patients, the spectral patterns and metabolite ratios were different from those of the abnormal regions (Fig 1C). The lower values of NAA/Ch and the higher values of Ch/Cr indicate an abnormality relative to ratios in healthy control subjects. In another patient, MR imaging findings were normal but the localized spectra were abnormal (Fig 2). Spectra from the normal-appearing anterior and posterior regions resembled the spectrum in Figure 1C. The metabolite ratios of NAA/Cr, NAA/Ch, and Ch/Cr from the anterior and posterior regions of this patient were 1.95, 1.38, and 1.42, respectively,

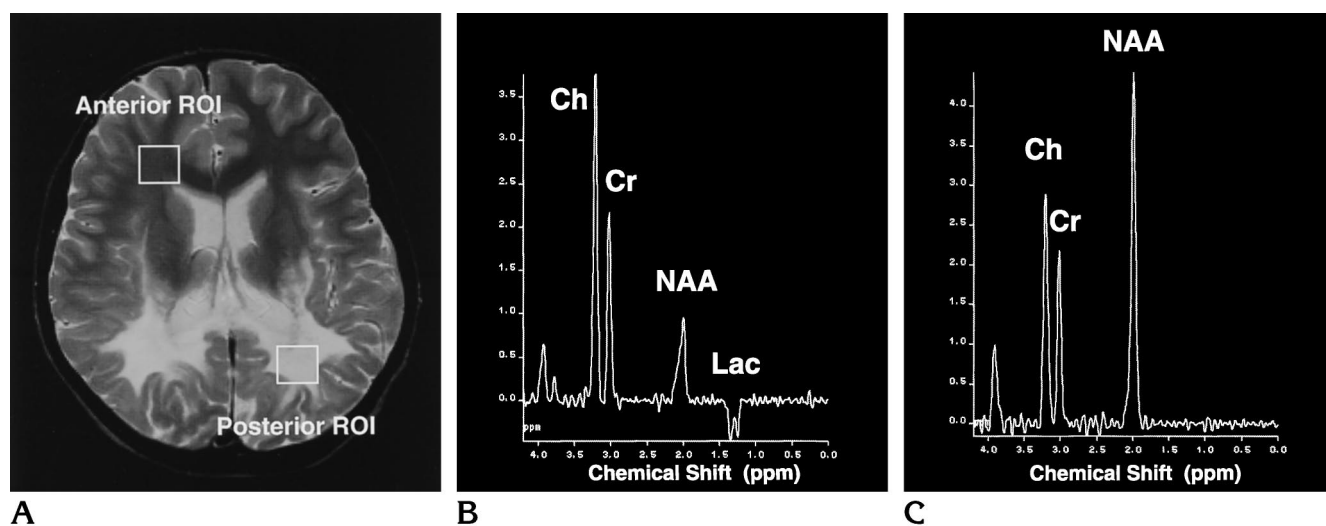


Fig 1. Findings in a 9-year-old with childhood-onset cerebral adrenoleukodystrophy.

A, Axial T2-weighted MR image (2500/90) shows placement of the anterior and posterior region of interest (ROI).

B, Spectra from abnormal posterior region show reduced NAA/Cr and NAA/Ch and elevated Ch/Cr. The lactate (Lac) doublet is also seen.

C, Spectra from normal-appearing anterior region show metabolites, which, relative to those from control subjects, showed lower values of NAA/Cr and NAA/Ch and a slightly increased Ch/Cr value.

TABLE 1: Comparison of metabolite ratios in control subjects and patients with COCALD who had abnormal and normal-appearing brain regions at MR imaging

	NAA/Cr	NAA/Ch	Ch/Cr
Control subjects (n = 5)	2.17 ± 0.09	2.00 ± 0.09	1.09 ± 0.04
Abnormal regions (n = 14)	1.49 ± 0.17	1.12 ± 0.16	1.52 ± 0.11
P value*	.005	.0004	.006
Normal-appearing regions (n = 12)	1.91 ± 0.07	1.58 ± 0.10	1.26 ± 0.06
P value†	.02	.004	<.05
P value‡	.03	.02	.06

Note—All values are presented as the mean plus or minus one standard error.

* Comparison of controls and patients with abnormal regions.

† Comparison of controls and patients with normal-appearing regions.

‡ Comparison of abnormal and normal-appearing regions in patients.

and 2.14, 1.81, and 1.18, respectively. A small amount of lactate was visible in the posterior region (Figure 2B). The mean values of the metabolite ratios from normal-appearing regions in 12 patients are also listed in Table 2. These values were between those of the control subjects and those from the abnormal regions. The differences between the values in the control subjects and those in the abnormal regions were statistically significant. The differences between the abnormal regions and the normal-appearing regions were also statistically different. The *P* values were at the lower end of significance, with that for Ch/Cr being .06.

Comparison of MR Spectroscopic Data and Neuropsychological Data

Neuropsychological tests were administered to every patient during the same visit. Table 2 lists correlation coefficients from abnormal regions of patients with posterior involvement of COCALD disease. Performance IQ correlated with all three metabolite ratios. Six individual subtests that make up the performance IQ score were evaluated separately, and the picture arrangement subtest was the only one that correlated significantly with all three metabolite ratios. Scores on the mazes test showed significant correlation with

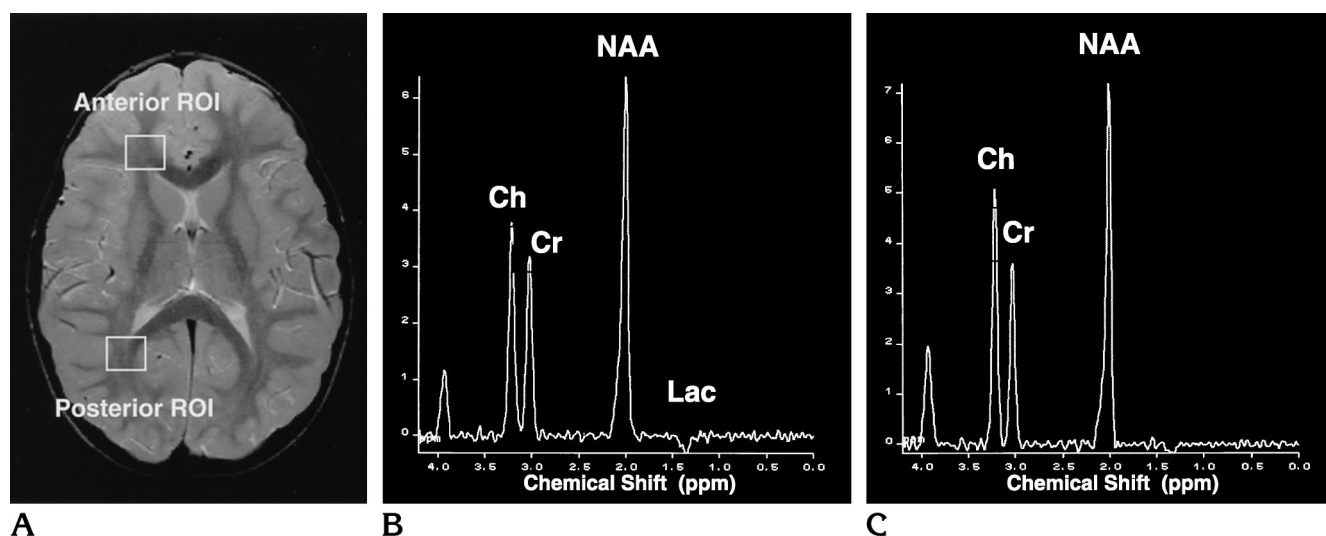


Fig 2. Findings in a 4-year-old with childhood-onset cerebral adrenoleukodystrophy. A, Axial T2-weighted MR image (2500/90) shows placement of the anterior and posterior region of interest (ROI). B, Spectra from normal-appearing posterior region show reduced NAA/Cr and lactate (Lac). C, Spectra from normal-appearing anterior region also show reduced NAA/Cr and NAA/Ch and elevated Ch/Cr. The MR image showed mild involvement in the posterior region, but the metabolite ratios from both regions are abnormal relative to those from control subjects.

TABLE 2: Correlation coefficients between neuropsychological data and MR spectroscopic metabolite ratios from abnormal and normal-appearing brain regions on MR images

	NAA/Cr	NAA/Ch	Ch/Cr
Abnormal posterior regions (n = 11)			
Performance IQ	0.90	0.91	-0.76
P value	.0001	<.0001	.009
Picture arrangement	0.94	0.94	-0.67
P value	<.0001	<.0001	.05
Mazes	0.76	0.77	-0.54
P value	.005	.004	.09
Normal-appearing anterior regions (n = 9)			
Reaction time	0.96	0.90	-0.56
P value	.007	.04	.4
Omission errors	NC	0.58	-0.90
P value		.4	.04

Note.—NC indicates no correlation.

NAA/Cr and NAA/Ch ratios. No significant correlations were found with the TOVA measures. For these same patients, MR spectra from normal-appearing anterior regions were correlated with neuropsychological measures, and two measures of the TOVA showed significant correlation with the metabolite ratios. NAA/Cr and NAA/Ch ratios from the normal-appearing anterior regions showed significant correlation with a measure of reaction time. One measure of vigilance, omission errors, correlated significantly with Ch/Cr. No significant correlation was found between performance IQ score and metabolite ratios from these

normal-appearing anterior regions. The correlation coefficients are listed in Table 2.

Discussion

Proton MR spectroscopy has been used to study X-linked ALD, and several studies have reported differences in metabolite ratios as compared with those in healthy control subjects, including a decrease in NAA/Cr and NAA/Ch ratios and an increase in the Ch/Cr ratio together with the presence of lactate (10–12). Previous studies have also shown that MR spectroscopic data correlate well with the clinical severity of disease (12). All these studies were focused on abnormal cerebral regions as depicted on MR images. Our study demonstrates the potential of proton MR spectroscopy to delineate abnormal cerebral regions in patients with ALD before the appearance of abnormal intensity patterns on MR images.

It has been shown previously that the metabolite ratios from abnormal cerebral regions are different from those in healthy control subjects; that is, NAA/Cr and NAA/Ch are decreased and Ch/Cr is increased (10–12). A decrease in NAA and an increase in Ch are common in patients with ALD. The decrease of NAA is due to loss of neurons (21) and the increase in Ch is an indicator of demyelination (22, 23). Metabolite ratios from normal-appearing regions in the same

patients also exhibit these patterns, and they are significantly different from those found in control subjects. The mean values are between those of the control subjects and those of the abnormal regions, indicating that the metabolic changes due to the disease are in progress before any change in intensity is seen on T2-weighted MR images. Monitoring of these normal-appearing regions by MR spectroscopy may be helpful in early diagnosis.

A comparison of MR spectroscopic metabolite ratios of normal-appearing regions with neuropsychological data helps to confirm that MR spectroscopic changes may herald the onset of disease before abnormalities are apparent on MR images. MR spectroscopic data from patients with posterior demyelination correlated well with performance IQ scores. In examining the subtests, we found that picture arrangement, which measures visual sequential ability and attention to visual detail, correlated highly with all three metabolite ratios from abnormal regions. Scores on the mazes subtest, a measure of visual processing and organization, also correlated with NAA/Cr and NAA/Ch ratios. No correlation was found with the measure of attention, thought to represent functions of the anterior brain region. The metabolite ratios from the normal-appearing anterior regions in these patients also showed significant correlation with measures of reaction time and vigilance. Thus, anterior region abnormalities, although normal-appearing on MR images, may be detected by MR spectroscopy. Too few patients with normal-appearing posterior regions were available for a detailed analysis.

Neuropsychological testing with the performance IQ test can be done in all patients over 3 years of age; however, measurement of attention on the TOVA can be done only in children over 6 years of age. Furthermore, loss of vision, a common occurrence in ALD, precludes the use of either test. Development of an auditory TOVA and a measure for preschool children will enable us to gather data on the full range of patients in the future.

In summary, we have shown that metabolite ratios from regions that appear normal at MR imaging can show abnormalities at proton MR spectroscopy. Thus, metabolic changes may precede morphological changes that manifest later as hyperintense areas on T2-weighted MR images. In addition, significant correlations between MR spectroscopic metabolite ratios and

neuropsychological measures were found, indicating that such normal-appearing regions are involved by ALD.

Acknowledgments

We thank the nurses and technicians of the MR imaging division of the Department of Radiology, University of Minnesota, for their excellent help in providing patient care and assistance.

References

1. Moser HW, Smith KD, Moser AB. X-linked adrenoleukodystrophy. In: Scriver CR, Beaudet AL, Sly WS, Valle D, eds. *The Metabolic Basis of Inherited Disease*. New York, NY: McGraw-Hill; 1995; 2325-2349
2. Moser HW, Moser AB, Smith KD, et al. Adrenoleukodystrophy: phenotypic variability, implications for therapy. *J Inherit Metab Dis* 1992;15:645-664
3. Lazo O, Contreras M, Hashmi M, Stanley W, Irazu C, Singh I. Peroxisomal lignoceroyl-CoA ligase deficiency in childhood adrenoleukodystrophy. *Proc Natl Acad Sci* 1988;85:7647-7651
4. Wanders RJA, van Roermond CWT, van Wijland MJA, et al. Direct evidence that the deficient oxidation of very long chain fatty acids in X-linked adrenoleukodystrophy is due to an impaired ability of peroxisomes to activate very long chain fatty acids. *Biochem Biophys Res Commun* 1988;153:618-624
5. Mosser J, Douar AM, Sarde CO, et al. Putative X-linked adrenoleukodystrophy gene shares unexpected homology with ABC transporters. *Nature* 1993;361:726-730
6. Philips JP, Lockman LA, Shapiro EG, et al. CSF findings in adrenoleukodystrophy: correlation between measures of cytokines, IgG production, and disease severity. *Pediatr Neurol* 1994;10:289-294
7. Shapiro EG, Lockman LA, Balthazor M, et al. Neuropsychological outcomes of several storage diseases with and without bone marrow transplantation. *J Inherit Metab Dis* 1995;18:413-429
8. Loes DJ, Hite S, Stillman AE, et al. Childhood cerebral form of adrenoleukodystrophy: short-term effect of bone marrow transplantation on brain MR observations. *AJNR Am J Neuroradiol* 1994;15:1767-1771
9. Tzika AA, Ball WS Jr, Vigneron DB, Dunn RS, Kirks DR. Clinical proton MR spectroscopy of neurodegenerative disease in childhood. *AJNR Am J Neuroradiol* 1993;14:1267-1281
10. Tzika AA, Ball WS Jr, Vigneron DB, Dunn RS, Nelson SJ, Kirks DR. Childhood adrenoleukodystrophy: assessment with proton MR spectroscopy. *Radiology* 1993;189:467-480
11. Kruse B, Barker PB, van Zijl PCM, Duyn JH, Moonen CTW, Moser HW. Multislice proton magnetic resonance spectroscopic imaging in X-linked adrenoleukodystrophy. *Ann Neurol* 1994;36:595-608
12. Rajanayagam V, Grad J, Krivit W, et al. Proton MR spectroscopy of childhood adrenoleukodystrophy. *AJNR Am J Neuroradiol* 1996;17:1013-1024
13. Van der Knapp MS, Van der Grond J, Van Rijen PC, Faber JAJ, Valk J, Willemsse K. Age-dependent changes in localized proton and phosphorus MR spectroscopy of the brain. *Radiology* 1990;176:509-515
14. Toft PB, Leth H, Lou HC, Pryds O, Henrikson O. Metabolite concentration in developing brain estimated with proton MR spectroscopy. *J Magn Reson Imaging* 1994;4:674-680

15. Ordidge RJ, Mansfield P, Lohman JA. Volume selection using gradients and selective pulses. *Ann NY Acad Sci* 1987;508:376–385
16. Wechsler D. *Wechsler Intelligence Scale for Children*. 3rd ed. San Antonio, Tex: The Psychological Corporation; 1991
17. Wechsler D. *Wechsler Preschool and Primary Scale of Intelligence Revised*. San Antonio, Tex: The Psychological Corporation; 1989
18. Balthazor M, Rajanayagam V, Shapiro EG, et al. Predicting dementia in white matter disease: magnetic resonance imaging, magnetic resonance spectroscopy and neuropsychology. *Ann Neurol* 1996;40:290
19. Greenberg LM. *Tests of Variables of Attention (TOVA)*. Los Alamitos, Calif: Universal Attention Disorders; 1989
20. Shapiro EG, Lockman LA, Knopman D, Krivit W. Characteristics of the dementia in late-onset metachromatic leukodystrophy. *Neurology* 1994;44:662–665
21. Birken DL, Oldendorf WH. N-acetyl-L-aspartic acid: a literature review of a compound prominent in ¹H NMR spectroscopic studies of brain. *Neurosci Biobehav Rev* 1989;13:23–31
22. Miller BL. A review of chemical issues in ¹H NMR spectroscopy: N-acetyl-aspartate, creatine and choline. *NMR Biomed* 1991;4:47–52
23. Confort-Gouny S, Vion-Dury J, Nicoli F, et al. A multiparametric data analysis showing the potential of localized proton MR spectroscopy of the brain in the metabolic characterization of neurological diseases. *J Neurol Sci* 1993;118:123–133

NOTICE

Beginning January 1, 1998, new manuscripts and correspondence should be sent to the following address:

American Journal of Neuroradiology
2210 Midwest Rd, Suite 207
Oak Brook, IL 60521

Until December 31, 1997, continue to use the current address: Rush-Presbyterian-St Luke's Medical Center, 1653 W Congress Pkwy, Suite KP108, Chicago, IL 60612.