

# Generic Contrast Agents

Our portfolio is growing to serve you better. Now you have a *choice*.



[VIEW CATALOG](#)

# AJNR

## **MR and proton MR spectroscopy of the brain in hyperhomocysteinemia caused by methylenetetrahydrofolate reductase deficiency.**

V Engelbrecht, M Rassek, J Huismann and U Wendel

This information is current as of May 24, 2025.

*AJNR Am J Neuroradiol* 1997, 18 (3) 536-539

<http://www.ajnr.org/content/18/3/536>

---

# MR and Proton MR Spectroscopy of the Brain in Hyperhomocysteinemia Caused by Methylenetetrahydrofolate Reductase Deficiency

V. Engelbrecht, M. Rassek, J. Huismann, and U. Wendel

**Summary:** MR imaging showed severe atrophy and large areas without myelination in the brain of a girl with methylenetetrahydrofolate reductase deficiency. Proton MR spectroscopy revealed mild signal reduction of *N*-acetylaspartate. After treatment with betaine, a second MR imaging study revealed a decrease in the size of the hypomyelinated zones that was paralleled by improved clinical status and laboratory findings.

**Index terms:** Magnetic resonance, spectroscopy; Metabolic disorder

Methylenetetrahydrofolate reductase (MTHFR) deficiency is an inherited metabolic error in the methionine synthesis pathway (1, 2). This enzyme catalyzes the reduction of 5,10-methylenetetrahydrofolate to 5-methyltetrahydrofolate, which is one of the donors of the methyl groups for the conversion of homocysteine to methionine. Patients with an inherited deficiency of MTHFR have raised homocysteine concentrations in blood, mild homocystinuria, and reduced concentrations of methionine in plasma and cerebrospinal fluid (3). This disorder results from decreased methionine and a resulting deficiency in *S*-adenosyl-*L*-methionine (SAM) formation. As a methyl donor for many methyl transfer reactions, SAM is involved in myelin synthesis (4). The clinical presentation of patients with this disorder is variable. The early-onset type manifests in infancy and if untreated results in delayed psychomotor development, severe mental retardation, progressive deterioration, and respiratory failure (1, 4, 5). The late-onset type of MTHFR deficiency manifests in adolescence with mental retardation, convulsion, neuropathy, or psychotic episodes (4, 6–8).

In patients with the late-onset type of MTHFR

deficiency, magnetic resonance (MR) imaging of the brain reveals atrophy, demyelination (9), and atrophy of the brain stem (8). We present the results of MR imaging and localized proton MR spectroscopy in a 10-month-old girl with proved MTHFR deficiency. Because betaine therapy was successful, we were able to evaluate the MR imaging changes of the brain after 1 year of treatment and compare them with the clinical outcome.

## Case Report

An infant girl, born after an uneventful term pregnancy, had initial feeding problems and, at 3 months of age, stopped smiling. Later, she did not sit up and did not learn to speak, and focal seizures developed. At the age of 10 months, we examined the patient for the first time. On physical examination, her length was in the 50th percentile, weight was in the 75th percentile, and head circumference was below the third percentile. The muscular tone of her arms and legs was normal, but there was a severe hypotonia of the trunk and she was only partially able to control her head movements. Deep tendon reflexes were equal on both sides. Ophthalmologic examination revealed a strabismus and astigmatism. Total homocysteine in plasma, measured as described by Fisherstrand et al (10), revealed elevated values of 154  $\mu\text{mol/L}$  (normal values, 6 to 12  $\mu\text{mol/L}$ ). Methionine in plasma, measured by column chromatography using amino acid analyses, was reduced to 7  $\mu\text{mol/L}$  (normal values, 15 to 21  $\mu\text{mol/L}$ ). Diagnosis of MTHFR deficiency was suggested because of mild homocystinuria and hyperhomocysteinemia with low plasma levels of methionine and confirmed by estimation of MTHFR activity as described by Kang et al (11) with modifications. The activity of MTHFR in lymphocytes was found to be under 10% of the mean normal activity. After initial therapy with folate and riboflavin for 1 week, plasma homocysteine and methionine levels remained unchanged.

---

Received January 18, 1996; accepted after revision May 5.

From the Institute of Diagnostic Radiology (V.E., M.R.) and the Department of Pediatrics (J.H., U.W.), Heinrich-Heine University Düsseldorf (Germany).

Address reprint requests to Dr Volkher Engelbrecht, Institute of Diagnostic Radiology, Heinrich-Heine University of Düsseldorf, PO Box 10100, D-40001 Düsseldorf, Germany.

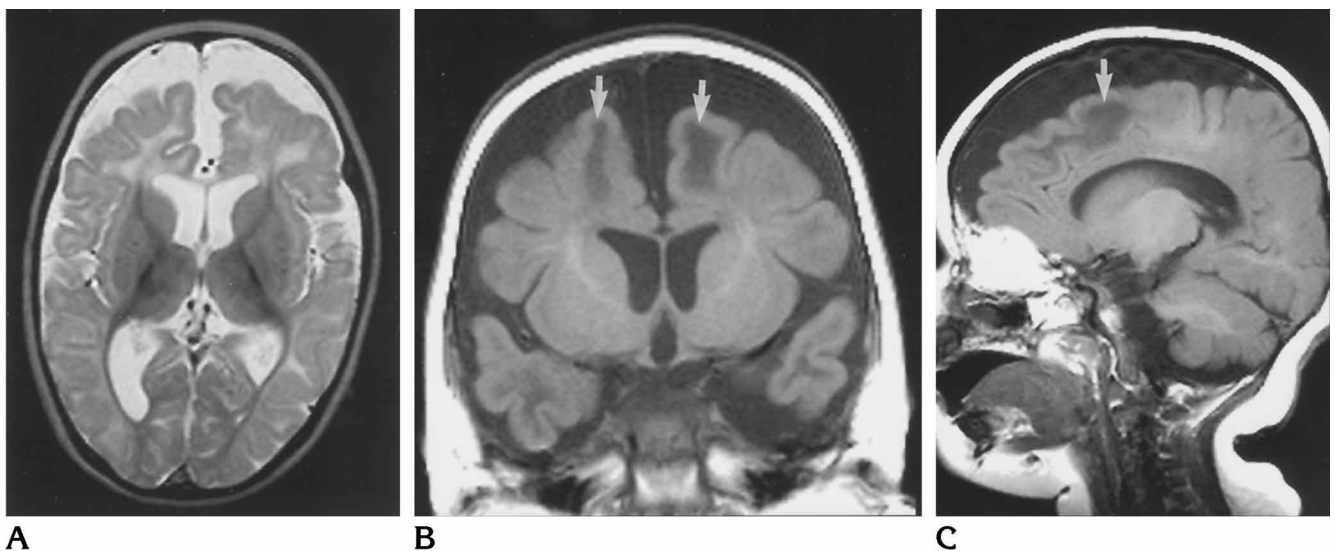


Fig 1. MR imaging in 10-month-old girl with MTHFR deficiency.

A, Axial turbo IR image (6000/19; inversion time, 250) shows severe brain atrophy with marked widening of subarachnoid space and moderate enlargement of the ventricles. The high signal intensity in frontal white matter indicates delayed myelination.

Coronal (B) and sagittal (C) T1-weighted images (660/15) show atrophy. Hypointense areas of white matter (arrows) are present in the frontal regions, suggesting delayed myelination.

At this time, MR imaging and proton MR spectroscopy were performed with a 1.5-T whole-body MR system and a circular polarized head coil. Axial spin-density and T2-weighted images (5000/15,90/1 [repetition time/echo time/excitations]) were acquired. For better evaluation of white matter, an additional magnitude reconstructed turbo inversion recovery (IR) sequence (6000/19/1; inversion time, 250) was obtained in the same orientation. T1-weighted images (660/15/2) were acquired in coronal and sagittal planes.

The initial MR images, obtained at the age of 10 months, showed marked brain atrophy with widening of the subarachnoid space, while the ventricles were only slightly dilated (Fig 1). Gyri and sulci appeared flat. The corpus callosum was small, infratentorial abnormalities were absent. The signal intensity of the genu of the corpus callosum on T2-weighted and turbo IR images was increased. Fibers of the optic radiations were small. In the frontal white matter, large areas with high signal intensity on T2-weighted and turbo IR images and reduced signal intensity on T1-weighted images were thought to represent white matter with delayed myelination (Fig 1).

The proton MR spectra were taken from a volume ( $2 \times 2 \times 2$  cm) located in parietal white matter on the left side after global and volume-selective shimming. With the use of point-resolved spectroscopy technology, the spectra were acquired with a double spin-echo sequence (1600/135/256), preceded by a frequency-selective  $90^\circ$  pulse at a water resonance to suppress the water signal. Eddy current compensation was achieved by a spectrum without water suppression (16 acquisitions). A zero-order phase correction was applied. Chemical shifts were expressed relative to tetramethylsilane (0 ppm) using the signal of *N*-acetylaspartate (NAA), which was set to 2.02

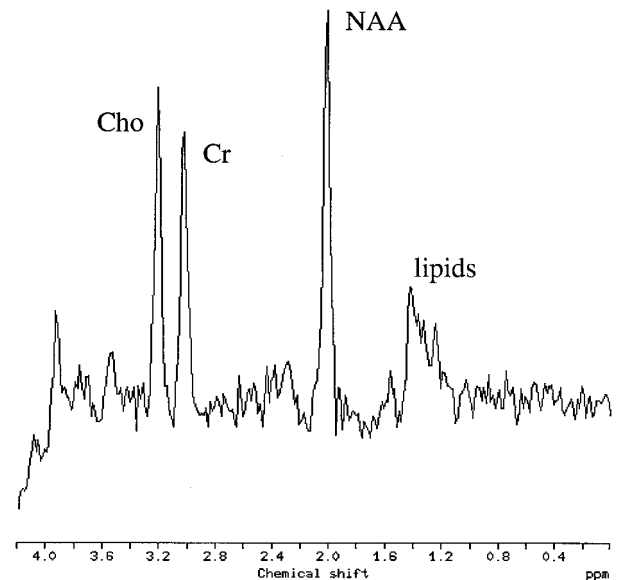


Fig 2. Graph shows findings at localized proton MR spectroscopy, with voxel located in parietal white matter. NAA signal intensity is reduced compared with the normal intensity of Cho and Cr, indicating delayed myelination. Lipid signals probably result from additional myelin breakdown.

ppm. Proton MR spectra were evaluated by peak area calculation using the implemented MR spectroscopy software. The ratios of NAA/creatine (Cr), NAA/choline (Cho), and Cho/Cr were calculated. Proton MR spectroscopy revealed a lowered NAA signal with a reduced ratio of NAA/Cr (1.42) and NAA/Cho (1.37). The ratio of Cho/Cr was normal (1.02) (Fig 2). A small signal of inositol was

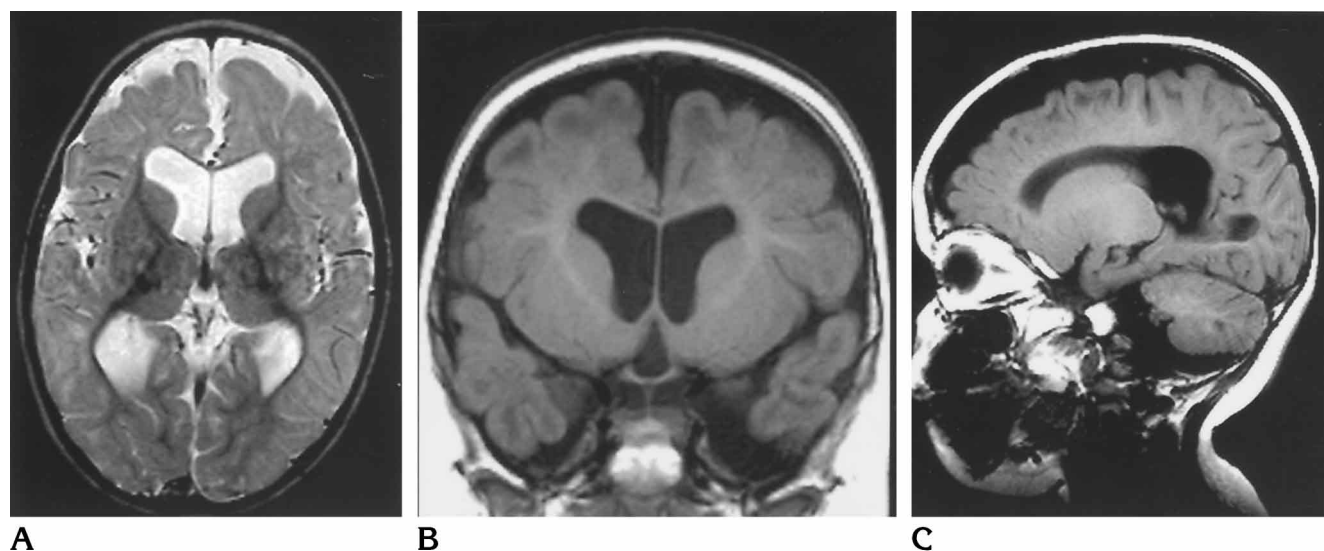


Fig 3. MR imaging in same child at the age of 22 months, after 1 year of therapy with betaine monohydrate. A, Turbo IR image (6000/19; inversion time, 250) shows less atrophy than in Fig 1A. The size of the ventricles has increased slightly, while the areas of delayed myelination in the frontal regions have decreased. Coronal (B) and sagittal (C) T1-weighted images (660/15) show a decrease in the size of the hypointense regions, indicating progressing myelination.

seen at 3.56 ppm. The peaks between 1.2 and 1.4 ppm were interpreted as lipid signals.

Later on, therapy was changed to betaine monohydrate (2 g three times per day) and anticonvulsive therapy. This led to reduced levels of homocysteine in plasma (90  $\mu\text{mol/L}$ ) and raised methionine concentration (30  $\mu\text{mol/L}$ ). After 1 year of therapy, marked clinical improvement was noted. Under additional physiotherapy, the now 22-month-old girl had learned to sit free, to stand by holding on with her hand, to grasp selectively, and to turn from a prone to a supine position. She could articulate, but was not able to speak words clearly. At this age, a second MR imaging study was performed.

This examination revealed a lesser degree of brain atrophy (Fig 3). Although widening of the subarachnoid space had decreased, the size of the ventricles showed a moderate increase. The corpus callosum still appeared small. In the occipital white matter, myelination was nearly normal and the size of the projection fibers of the optical radiation had increased. In the frontal white matter, the size of the areas with low or absent myelination had decreased (Fig 3).

## Discussion

Symptoms of inborn MTHFR deficiency can develop in infancy or later on in childhood or adolescence. An early report on the radiologic appearance of this disease described dilatation of the ventricles in pneumoencephalography and ventriculography of a 9-year-old girl (12). A report of the computed tomographic (CT) findings in a child with MTHFR described cere-

bral atrophy with widening of the subarachnoid spaces and enlargement of the third and lateral ventricles (1). In addition, low density in the white matter of both cerebral hemispheres was noted. Walk et al (9) reported mild diffuse cortical atrophy and periventricular white matter abnormalities near the occipital horns of the lateral ventricles on CT and MR imaging studies of a 12-year-old-girl with MTHFR deficiency.

In our patient, we observed areas with abnormally prolonged relaxation times in the frontal white matter on T1- and T2-weighted images at the age of 10 months. At this age, normal white matter should appear hyperintense within the entire brain on T1-weighted images, while the cortex and underlying white matter are mainly isointense on T2-weighted images (13). We believe that these abnormal white matter areas mainly represent regions of delayed myelination, as clear regression in size occurred under betaine treatment and was associated with clinical improvement.

Postmortem neuropathologic examinations of patients with MTHFR deficiency surviving beyond infancy have shown demyelination predominantly in the cerebral white matter (1, 6, 12, 14). The exact pathophysiology of this condition is unknown. A probable hypothesis is that reduced methionine biosynthesis causes reduced biosynthesis of SAM. This methyl donor is involved in various transmethylation reac-

tions, including the production of neurotransmitters, carnitine, phosphatidylcholine, and, consequently, in myelin synthesis (4, 6).

In our patient, proton MR spectroscopy revealed a reduction of NAA, consistent with both immature brain and demyelination. The lipid peaks may indicate myelin breakdown; however, the decreasing size of the lesions in the frontal white matter after therapy suggests that they are mainly caused by delayed myelination. Homocysteine and methionine are not detectable by in vivo proton MR spectroscopy because of their low concentrations in brain. Hence, findings at both MR imaging and proton MR spectroscopy are nonspecific and do not permit an unambiguous diagnosis.

Treatment of MTHFR deficiency with folates in an attempt to maximize any residual enzyme activity has failed in most cases (1, 5, 6, 12). The most promising therapy consists of oral administration of betaine, an alternative methyl donor for methionine synthesis (4–6, 8, 9). This appears effective in decreasing plasma homocysteine and in increasing plasma methionine as well as SAM in cerebrospinal fluid. With this therapy, either reversing or halting progression of the neurologic syndrome has been noted (4, 5, 8, 9). In our patient, MR imaging showed that betaine therapy for MTHFR deficiency led to a partial normalization of initially severely delayed myelination.

### Acknowledgment

We thank Henk Blom, University Children's Hospital Nijmegen, for measuring the MTHFR activity in blood cells and the total homocysteine in plasma.

### References

1. Clayton PT, Smith I, Harding B, Hyland K, Leonard JV, Leeming RJ. Subacute combined degeneration of the cord, dementia and parkinsonism due to an inborn error of folate metabolism. *J Neurol Neurosurg Psychiatry* 1986;49:920–927
2. Rosenblatt DS. Inherited disorders of folate transport and metabolism. In: Scriver CR, Beaudet AL, Sly WS, Valle D, eds. *The Metabolic and Molecular Bases of Inherited Disease*. 7th ed. New York, NY: McGraw-Hill; 1995:3116–3128
3. Erbe RW. Congenital defects in folate metabolism. *Adv Hum Genet* 1987;9:293–354
4. Wendel U, Bremer HJ. Betaine in the treatment of homocystinuria due to 5,10-methylenetetrahydrofolate reductase deficiency. *Eur J Pediatr* 1984;142:147–150
5. Hyland K, Smith I, Bottiglieri T, et al. Demyelination and decreased S-adenosylmethionine in 5,10-methylenetetrahydrofolate reductase deficiency. *Neurology* 1988;38:459–462
6. Visy JM, Le Coz P, Chadefaux B, et al. Homocystinuria due to 5,10-methylenetetrahydrofolate reductase deficiency revealed by stroke in adult sibs. *Neurology* 1991;41:1313–1315
7. Pasquier F, Lebert F, Petit H. Methylenetetrahydrofolate reductase deficiency revealed by a neuropathy in a psychotic adult. *J Neurol Neurosurg Psychiatry* 1994;57:765–766
8. Kishi T, Kawamura I, Harada Y, et al. Effect of betaine on S-adenosylmethionine levels in the cerebrospinal fluid in a patient with methylenetetrahydrofolate reductase deficiency and peripheral neuropathy. *J Inher Metab Dis* 1994;17:560–565
9. Walk D, Kang SS, Horwitz A. Intermittent encephalopathy, reversible nerve conduction slowing, and MRI evidence of cerebral white matter disease in methylene-tetrahydrofolate reductase deficiency. *Neurology* 1994;44:344–347
10. Fisherstrand T, Refsum H, Kralheim G, Ueland PM. Homocysteine and other thiols in plasma and urine: automated determination and sample stability. *Clin Chem* 1993;39:263–271
11. Kang SS, Wong PWK, Susmano A, Sora J, Noris M, Ruggie N. Thermolabile methylenetetrahydrofolate reductase: an inherited risk factor for coronary artery disease. *Am J Hum Genet* 1991;48:536–545
12. Wong PWK, Justice MScP, Hruby M, Weiss EB, Diamond E. Folic acid nonresponsive homocystinuria due to methylenetetrahydrofolate reductase deficiency. *Pediatrics* 1977;59:749–756
13. Barkovich AJ, Kjos BO, Jackson DE, Norman D. Normal maturation of the neonatal and infant brain: MR imaging at 1.5 T. *Radiology* 1988;166:173–180
14. Kanwar YS, Manaligod JR, Wong PWK. Morphologic studies in a patient with homocystinuria due to 5,10-methylenetetrahydrofolate reductase deficiency. *Pediatr Res* 1976;10:609–613