

# Generic Contrast Agents

Our portfolio is growing to serve you better. Now you have a *choice*.



[VIEW CATALOG](#)

# AJNR

## **Subcutaneous fat necrosis of the newborn: CT findings of head and neck involvement.**

K I Norton, P M Som, J M Shugar, M A Rothchild and L Popper

*AJNR Am J Neuroradiol* 1997, 18 (3) 547-550

<http://www.ajnr.org/content/18/3/547>

This information is current as of May 25, 2025.

---

# Subcutaneous Fat Necrosis of the Newborn: CT Findings of Head and Neck Involvement

Karen I. Norton, Peter M. Som, Joel M. A. Shugar, Michael A. Rothchild, and Laura Popper

**Summary:** We present the CT findings in two newborns with subcutaneous fat necrosis. This is an uncommon disease that occurs in neonates who have had difficult deliveries. The CT findings varied from discrete subcutaneous nodules to a diffuse subcutaneous fullness. Although the subcutaneous disease tends to spontaneously resolve within weeks to months, an associated hypercalcemia may have a fatal outcome.

**Index terms:** Infants, newborn; Neck, computed tomography

Subcutaneous fat necrosis is a transient disorder of the subcutaneous adipose tissue that develops after trauma or asphyxia during birth and that may be associated with hypercalcemia. The underlying cause of subcutaneous fat necrosis may be hypoxia and hypothermia in the neonatal period; however, since subcutaneous fat necrosis does not occur in all infants at risk for these conditions, there may be additional predisposing factors. Whereas the subcutaneous nodules of subcutaneous fat necrosis are usually self-limited, the hypercalcemia, if undetected, may have a fatal outcome. This disease has been described predominately in the dermatologic literature, with approximately 30 cases having been reported since 1991 (1–9). Subcutaneous fat necrosis has also been cited as a possible cause of soft-tissue calcification. It is important that radiologists be familiar with the clinical and imaging features of this unusual entity to facilitate a prompt diagnosis and to preclude unnecessary surgery.

## Case Reports

### Case 1

A full-term boy, delivered via forceps, was born with transposition of the great vessels. Surgery to correct this anomaly was performed successfully during the first week

of life. During the second week, his parents noticed a mass in his left cheek. He was seen by an otolaryngologist during his fourth week, when the mass measured approximately  $3 \times 2$  cm. The overlying skin was taut and there was a slight violaceous coloration of the overlying skin. A computed tomographic (CT) scan showed a diffuse subcutaneous soft-tissue thickening and increased attenuation in the cheek area. In addition, numerous, poorly defined subcutaneous nodules were present in the back of the neck, associated with a slight thickening and increased attenuation of the subcutaneous tissues (Fig 1). The remaining subcutaneous tissues in the face and neck were normal. A fine-needle aspiration biopsy of the cheek mass showed some fibrohistiocytic cells, occasional multinucleated cells, and fragments of fibrofatty connective tissue. The findings were considered compatible with subcutaneous fat necrosis. Over the next 3 weeks, the masses continued to enlarge slightly; however, 2 months later, each mass had reduced to approximately 50% of its former size. By 6 months of life, the masses had disappeared. During this interval, the patient's calcium levels were monitored and remained normal.

### Case 2

A full-term boy, delivered via forceps, had a cephalhematoma of the upper right scalp. During the first week of life he was noted to have a slowly enlarging, indurative, subcutaneous nodule in each cheek. At 9 days of age, the nodule in the left cheek measured 1 to 2 cm in diameter and the mass in the right cheek measured 3 to 4 cm. There was some violaceous coloration of the taut overlying skin. A third, smaller mass was present in the left side of the neck. There were no other abnormal findings. A CT scan showed the subcutaneous nodules in the cheek region to be limited to the subcutaneous fat. Each mass had minimally unsharp margins and the lesion in the right side of the face had a central region of near-fatty attenuation. The nodule in the left side of the neck extended from the subcutaneous fat to the deeper musculature, but was otherwise similar in appearance to the lesions in the facial area (Fig 2). The findings were considered compatible with subcutaneous fat necrosis. Over the next 2 months, the

---

Received April 3, 1996; accepted after revision June 25.

From the Departments of Radiology (K.I.N., P.M.S.), Pediatrics (K.I.N., L.P.), and Otolaryngology (P.M.S., J.M.A.S., M.A.R.), Mount Sinai School of Medicine of the City University of New York (NY).

Address reprint requests to Karen Norton, MD, Department of Radiology, Mount Sinai Hospital, One Gustave Levy Place, New York, NY 10029.

AJNR 18:547–550, Mar 1997 0195-6108/97/1803-0547 © American Society of Neuroradiology

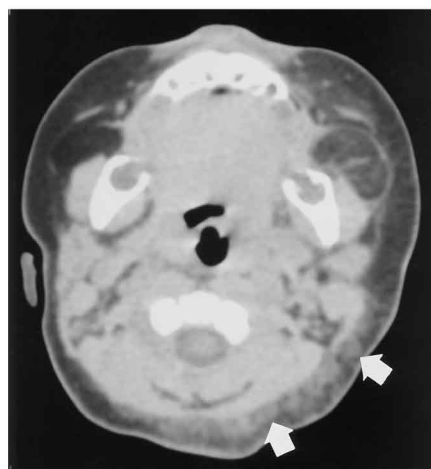
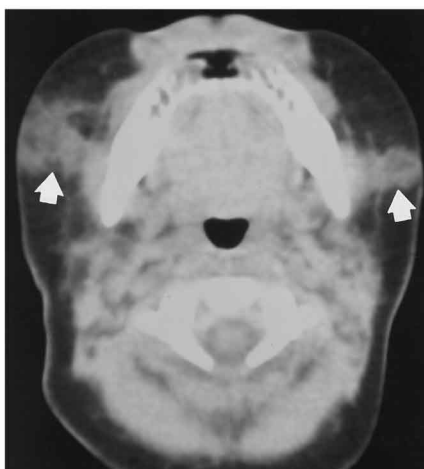
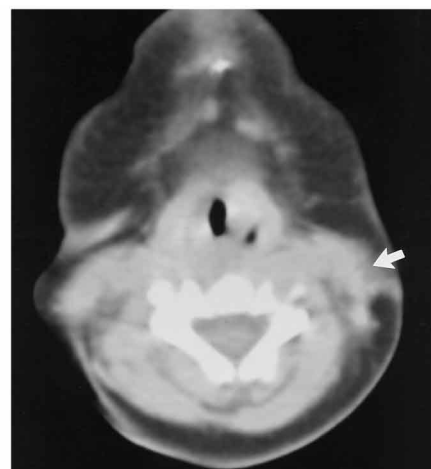


Fig 1. Axial CT scan shows diffuse infiltration of the subcutaneous fatty tissues of the left side of the cheek and multiple poorly defined posterior subcutaneous nodules (arrows).



A



B

Fig 2. Axial CT scan at the level of the mandible (A) reveals poorly defined subcutaneous nodules in both cheeks (arrows). These extended to but did not infiltrate the underlying musculature. Centrally, these masses have near-fatty attenuation. More caudally in the neck (B), another poorly defined subcutaneous mass abuts the left sternocleidomastoid muscle but does not appear to infiltrate it (arrow).

three masses markedly reduced in size and the overlying skin became normal. Hypercalcemia did not develop.

## Discussion

Subcutaneous fat necrosis affects full-term or postterm infants and is characterized by the appearance, days to weeks after a complicated perinatal period, of one or more well-defined, nonsuppurative, erythematous or violaceous, mobile subcutaneous masses, often with taut overlying skin. It is usually associated with obstetric manipulation, perinatal asphyxia, meconium aspiration, or maternal disease. Typically, lesions develop on the shoulders, back, buttocks, thighs, and cheeks. It has been postulated that these lesions result from localized tissue hypoxia and mechanical pressure, which further compromise the local circulation (1, 2). It has also been suggested that thrombocytosis may play a role in the pathogenesis of adipose tissue necrosis by causing lower blood perfusion and relative hypoxia and hypothermia (3). The nodules of subcutaneous fat necrosis may enlarge for several weeks to months, but then usually involute. Rarely, local complications include epidermal atrophy, ulceration, scarring, or infection.

In support of the hypothesis that affected infants share a common insult of hypothermia is the observation that subcutaneous fat necrosis can be seen after surgically induced hypother-

mia for cardiac surgery (4). It has been postulated that the brown fat of infancy, which contains a higher percentage of the saturated palmitic and stearic acids rather than the oleic acid, which is found in adult yellow fat, has a higher melting point and hence tends to crystallize with hypothermic injury (1, 2). Pressure injury, such as the obstetrician's hands or forceps, may cause a local ischemic effect that compounds the tissue injury. Other hypotheses include a borderline defect in fat (1) or triglyceride (5) metabolism, which is exacerbated by neonatal stress, and an association with elevated levels of prostaglandin E (6).

Pathologically, subcutaneous fat necrosis is characterized by clusters of adipocytes, histiocytes, fibroblasts, scant lymphocytes, and numerous foreign body giant cells. Granulomatous fat necrosis and calcifications are seen. Hypercalcemia is the most serious complication of subcutaneous fat necrosis, and is believed to be caused by an excess production of 1,25 dihydroxyvitamin D by the granulomatous macrophages (7). Because hypercalcemia may occur from 1 to 6 months after the skin lesions develop, a neonate with subcutaneous fat necrosis should have calcium levels monitored for at least 6 months. In the older literature, fatality was reported in 3% to 19% of cases (1); however, these statistics are probably inflated, as detection and treatment of hypercalcemia have

advanced in recent years. The radiologist should also monitor for possible renal complications, and renal sonographic studies are recommended to rule out nephrocalcinosis and nephrolithiasis (8).

On CT scans, the lesions of subcutaneous fat necrosis appear localized to the subcutaneous tissues immediately deep to the skin. One of our patients had two discrete nodules in the right side of the face, one nodule in the left side of the face, and one nodule in the middle of the left side of the neck. The nodules had minimally infiltrative margins and two nodules had areas of central low density only slightly higher in attenuation than that of fat. When a nodule extended to partially obliterate the fat planes about the superficial margin of an adjacent deep muscle, the muscle itself and the more medial fat planes about the muscle were otherwise normal. In our second patient, a series of diffuse small nodules in the back of the neck were located within slightly thickened subcutaneous tissues that had a slightly increased attenuation. In the left facial area, there was a diffuse subcutaneous fullness with increased attenuation in the fat, but no discrete mass was identified. Sonographic examination was not done, since this technique cannot optimally show soft-tissue planes or infiltration. Magnetic resonance imaging was deferred, since it would have required sedation, and the clinicians preferred not to use it.

If the clinical situation warrants, fine-needle aspiration biopsy of the subcutaneous lesions may be useful to confirm the diagnosis (9, 10). The finding of negatively stained, needle-shaped crystals within histiocytes and multinucleated giant cells is highly suggestive of subcutaneous fat necrosis. The principle differential diagnosis includes other soft-tissue tumors of infancy, including rhabdomyosarcomas, the spectrum of fibrous lesions, hemangiomas, neurofibromas, and sclerema neonatorum. Histologically, these are all distinct entities.

Embryonal rhabdomyosarcoma is the most common of these tumors to affect young children (11). However, unlike subcutaneous fat necrosis, rhabdomyosarcoma most often develops in children after the first few months of life. Rhabdomyosarcoma is usually a solitary, rapidly enlarging, firm mass that involves a striated muscle. On imaging, it is a densely cellular infiltrating neoplasm that may have sites of hemorrhage and necrosis. In the neck and cheeks,

the tumor apparently always involves a skeletal muscle.

The fibromatoses that develop in children include infantile myofibromatosis (congenital generalized or multiple fibromatosis), desmoid fibromatosis, and extraabdominal fibromatosis. Of these entities, infantile myofibromatosis can occur in neonates; however, the typical lesions are in the skeleton, lungs, heart, and gastrointestinal tract. The more superficial lesions tend to be desmoid fibromatoses, and these tend to develop in somewhat older children than those who are affected by subcutaneous fat necrosis. On CT scans, these fibrous tumors have a fairly homogeneous soft-tissue attenuation, usually with infiltrating margins, that involve adjacent muscles and often bone. These lesions also tend to arise in a variety of sites that are uncommon for subcutaneous fat necrosis (12).

A hemangioma can arise in the neonatal period, but usually it appears when the patient is several months old. Although congenital hemangiomas are usually more deeply located than the cutaneous capillary variety, both can be multiple, enlarge during the first year of life, and then involute. However, these are soft lesions, often with a bluish discoloration of the overlying skin. Distinguishing them from the lesions of subcutaneous fat necrosis is rarely a problem.

Neurofibromas may occur as multiple lesions, but subcutaneous locations are not typical in the neonate. Most of the subcutaneous lesions are plexiform neurofibromas that are clinically distinct from the subcutaneous lesions of subcutaneous fat necrosis. Similarly, other causes of neck masses in the newborn, such as fibromatosis coli, lymphatic malformations, and branchial cleft cysts, are also usually clinically distinct.

Sclerema neonatorum is a rare disease of the newborn that is characterized by a diffuse hardening of the subcutaneous adipose tissues. As such, it is distinct from the localized lesions of subcutaneous fat necrosis. In addition, it is associated with prematurity and a grave prognosis (1, 2, 13).

In summary, subcutaneous fat necrosis is an unusual clinical and pathologic entity with apparently distinctive radiologic features. It has a favorable prognosis if the associated hypercalcemia is controlled and invasive procedures are avoided. Discovery of a growing mass or masses in the soft tissues of an otherwise healthy neonate can be alarming. Recognition

of this unusual condition and its CT manifestations can allow the physician to distinguish this entity from malignant lesions and to reassure the parents of the probability of a complete spontaneous recovery.

## References

1. Hicks MJ, Levy ML, Alexander J, Flaitz CM. Subcutaneous fat necrosis of the newborn and hypercalcemia: case report and review of the literature. *Pediatr Dermatol* 1993;10:271-276
2. Darmstadt GL, Kanzler MH. Pathological case of the month. *Arch Pediatr Adolesc Med* 1994;148:61
3. Turba F, Bianchi C, Cella D, Rondanini GF. Thrombocytosis and neonatal subcutaneous adiponecrosis. *Minerva Pediatr* 1994;46:343-346
4. Chuang SD, Chiu HC, Chang CC. Subcutaneous fat necrosis of the newborn complicating hypothermic cardiac surgery. *Br J Dermatol* 1995;132:805-810
5. Janssens PMW, Vonk J, DeMacker PNM. Hypertriglyceridaemia in a case of subcutaneous fat necrosis in a newborn. *Ann Clin Biochem* 1993;30:482-484
6. Sharata H, Postellon DC, Hashimoto K. Subcutaneous fat necrosis, hypercalcemia, and prostaglandin E. *Pediatr Dermatol* 1995;12:43-47
7. Kruse K, Irle U, Uhlig R. Elevated 1,25-dihydroxyvitamin D serum concentrations in infants with subcutaneous fat necrosis. *J Pediatr* 1993;122:460-463
8. Gu LL, Daneman A, Binet A, Kooh SW. Nephrocalcinosis and nephrolithiasis due to subcutaneous fat necrosis with hypercalcemia in two full-term asphyxiated neonates: sonographic findings. *Pediatr Radiol* 1995;25:142-144
9. Gupta RK, Naran S, Selby RE. Fine needle aspiration cytodiagnosis of subcutaneous fat necrosis of the newborn: a case report. *Acta Cytol* 1995;39:759-761
10. Walker WP, Smith RJ, Cohen MB. Fine-needle aspiration biopsy of subcutaneous fat necrosis of the newborn. *Diagn Cytopathol* 1993;9:329-332
11. Hajdu SI. Soft tissue sarcomas: classification and natural history. *Cancer* 1981;31:271-280
12. Patrick LE, O'Shea P, Simoneaux SF, Gay BB Jr, Atkinson GO. Fibromatoses of childhood: the spectrum of radiographic findings. *AJR Am J Roentgenol* 1996;166:163-169
13. Jardine D, Atherton DJ, Trompeter RS. Sclerema neonatorum and subcutaneous fat necrosis of the newborn in the same infant. *Eur J Pediatr* 1990;150:125-126