

Generic Contrast Agents

Our portfolio is growing to serve you better. Now you have a *choice*.



FRESENIUS
KABI

[VIEW CATALOG](#)

AJNR

CT and MR findings of denervated tongue after radical neck dissection.

R Murakami, Y Baba, R Nishimura, M Furusawa, T Baba, T Okuda, M Takahashi and T Ishikawa

AJNR Am J Neuroradiol 1997, 18 (4) 747-750

<http://www.ajnr.org/content/18/4/747>

This information is current as of May 28, 2025.

CT and MR Findings of Denervated Tongue after Radical Neck Dissection

Ryuji Murakami, Yuji Baba, Ryuichi Nishimura, Mitsuhiro Furusawa, Takashi Baba, Tomoko Okuda, Mutsumasa Takahashi, and Takeru Ishikawa

PURPOSE: To describe the CT and MR findings in the denervated tongue after a radical neck dissection. **METHODS:** We retrospectively evaluated the radiologic findings in seven patients who had hypoglossal paralysis following radical neck dissection. None of the patients had clinical or radiologic evidence of tumor recurrence. **RESULTS:** The side of the tongue operated on showed low density on CT scans. At MR imaging, denervated tongues were clearly seen as hyperintense relative to muscle on T2-weighted images; on T1-weighted images, the signal was hypointense to hyperintense, representing increased extracellular water or fatty degeneration. **CONCLUSION:** In patients who have undergone a neck dissection for a malignant process, abnormal imaging findings in the tongue not only might indicate a recurrence of tumor involving the hypoglossal nerve but also suggest the possibility of postoperative change. Our findings emphasize the importance of the denervated tongue in differentiating inflammatory from neoplastic diseases of the tongue.

Index terms: Tongue, magnetic resonance; Neck, surgery; Surgery, complications; Nerves, hypoglossal (XII); Iatrogenic disease or disorder

AJNR Am J Neuroradiol 18:747–750, April 1997

Denervation muscle atrophy is a known sign of pathologic changes involving the motor nerves (1–6). Hemiatrophy of the tongue is an indirect sign of damage to the hypoglossal nerve; it signals the possibility of head and neck neoplasm or brain stem abnormality (1–3). Hypoglossal paralysis occurring after a radical neck dissection has been reported in the otorhinolaryngologic literature as a complication of surgery (7, 8). Our aim was to evaluate the radiologic findings in seven patients with denervated tongue after a radical neck dissection, with special attention to the appearance on magnetic resonance (MR) images.

Materials and Methods

Radiologic findings in seven patients with a denervated tongue after radical neck dissection were evaluated retrospectively. Surgery had been performed both with and without radiation therapy for the treatment of malignant tumors of the head and neck (Table). Hypoglossal paralysis was diagnosed clinically after radical neck dissection. No patient had evidence of tumor recurrence, and there was no radiologic evidence of soft-tissue enlargement along the course of the hypoglossal nerve up to the skull base.

MR images were obtained with one of two 1.5-T imagers from 1 to 18 months after radical neck dissection as follow-up studies: two patients were studied serially. T1-weighted spin-echo images (600–670/14–15/1–2 [repetition time/echo time/excitations]) were obtained before and after intravenous injection of 0.1 mmol/kg gadopentetate dimeglumine. T2-weighted images were obtained either with the conventional spin-echo (2300/90/1) or the fast spin-echo (4000–4500/96/1–2) technique. Computed tomography (CT) was also performed in four patients.

Results

The radiologic findings of the seven patients are summarized in the Table. CT scans showed

Received May 30, 1996; accepted after revision October 7.

From the Departments of Radiology (R.M., Y.B., R.N., M.F., T.B., T.O., M.T.) and Otorhinolaryngology (T.I.), Kumamoto (Japan) University School of Medicine.

Address reprint requests to Ryuji Murakami, MD, Department of Radiology, Kumamoto University School of Medicine, 1–1 Honjo, Kumamoto 860, Japan.

AJNR 18:747–750, Apr 1997 0195-6108/97/1804-0747

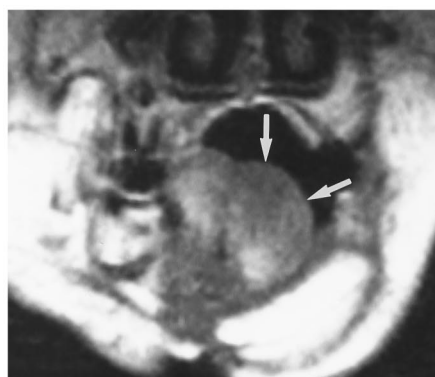© American Society of Neuroradiology

Patients with denervated tongue after radical neck dissection

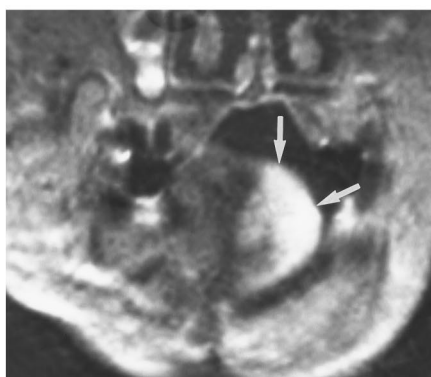
Case	Age, y/Sex	Primary Lesion	Side of RND	Duration, mo, from RND	MR Imaging			CT
					T1-Weighted Images	T2-Weighted Images	Presence of Enhancement	
1	42/M	L submandibular ACC	L	1	Hypo	Hyper	Yes	Low density
2	63/M	R maxillary SCC	R	1	Iso	Hyper	No	...
3	57/M	R nasopharyngeal SCC	R	7	Hyper	Hyper	No	...
				3	Iso	Hyper	No	...
4	66/F	L gingival SCC	L	6	Iso	Hyper	No	...
				4	Hypo	Hyper	Yes	Low density
5	70/M	L gingival SCC	L	5	Hyper	Hyper	No	...
6	52/M	R maxillary SCC	R	12	Hyper	Hyper	Yes	Low density*
7	42/M	R nasopharyngeal SCC	L	18	Hyper	Hyper	Yes	Low density*

Note.—SCC indicates squamous cell carcinoma; ACC, adenoid cystic carcinoma; RND, radical neck dissection; hypo, hypointense relative to contralateral normal tongue; iso, isointense; and hyper, hyperintense.

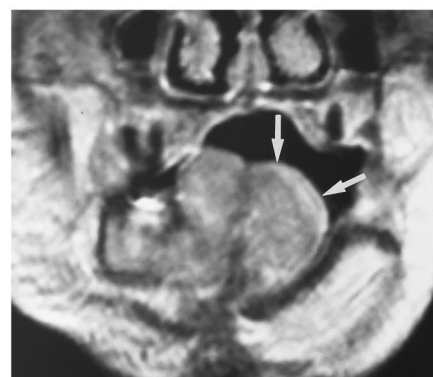
* Fatty density.



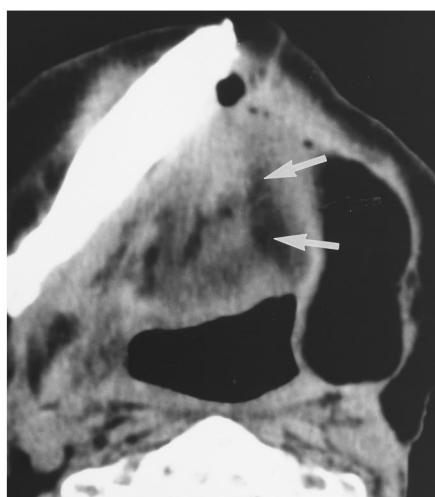
A



B



C



D

Fig 1. Case 4: 66-year-old woman with left-sided hypoglossal paralysis 4 months after left mandibular resection, left-sided radical neck dissection, and myocutaneous neck flap reconstruction.

A, Coronal unenhanced T1-weighted MR image (600/15/1) shows hypointensity on the left side of the tongue (arrows).

B, Coronal T2-weighted MR image (2300/90/1) clearly shows hyperintensity on the left half of the tongue (arrows).

C, Coronal contrast-enhanced T1-weighted MR image (600/15/1) shows abnormal enhancement in the corresponding area (arrows).

D, CT scan shows low-density area representing increased fat (arrows).

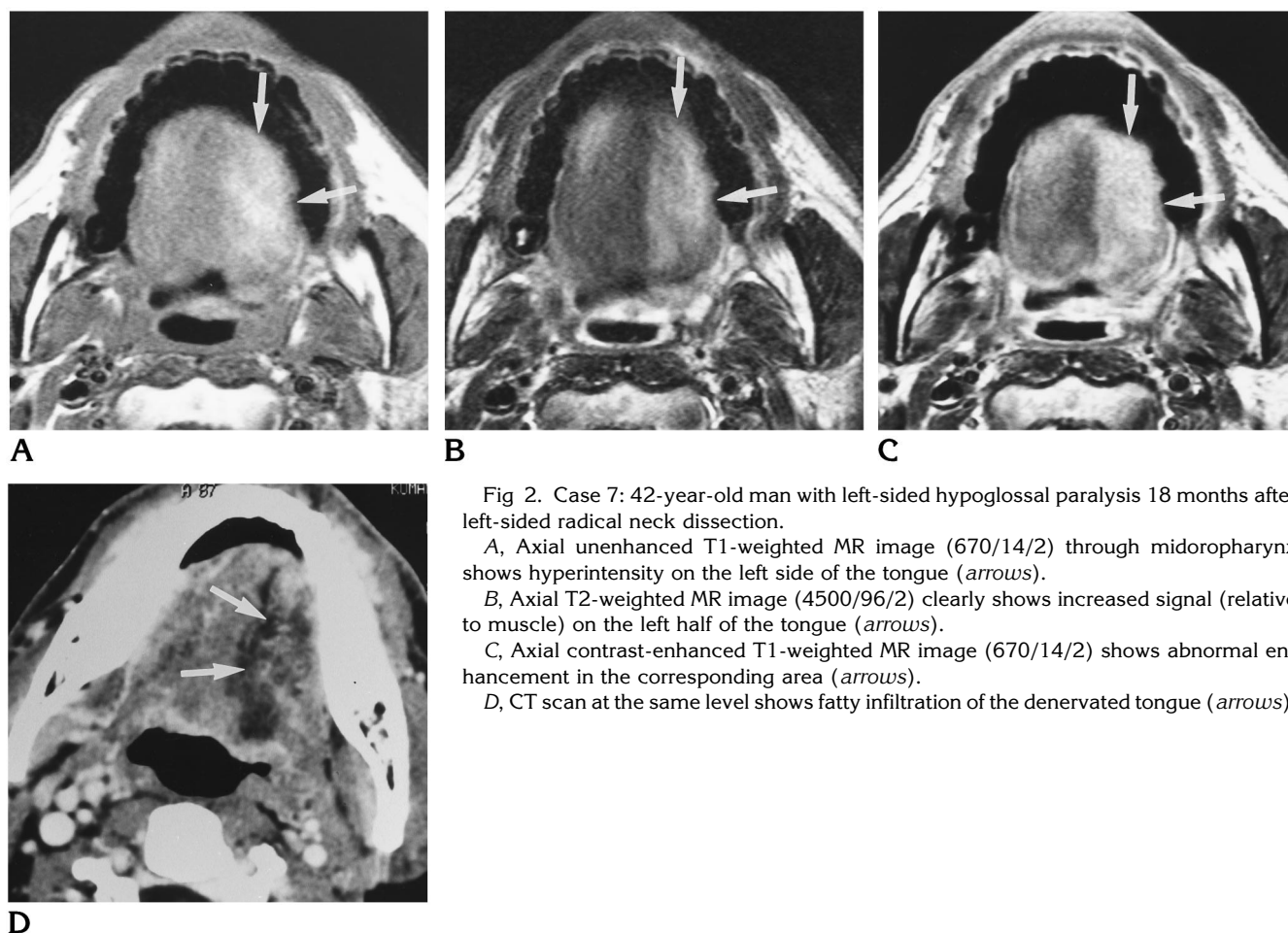


Fig 2. Case 7: 42-year-old man with left-sided hypoglossal paralysis 18 months after left-sided radical neck dissection.

A, Axial unenhanced T1-weighted MR image (670/14/2) through midoropharynx shows hyperintensity on the left side of the tongue (arrows).

B, Axial T2-weighted MR image (4500/96/2) clearly shows increased signal (relative to muscle) on the left half of the tongue (arrows).

C, Axial contrast-enhanced T1-weighted MR image (670/14/2) shows abnormal enhancement in the corresponding area (arrows).

D, CT scan at the same level shows fatty infiltration of the denervated tongue (arrows).

low density with atrophy on the side of the tongue operated on. T1-weighted MR images showed hypointense to hyperintense signal, with areas of hyperintensity appearing on images obtained 5 or more months after radical neck dissection (Figs 1 and 2). The denervated tongue at each phase was clearly seen as hyperintense relative to normal tongue musculature on T2-weighted MR images obtained with either the conventional spin-echo or fast spin-echo technique. Contrast enhancement on the denervated side of the tongue was more prominent than that on the normal side in four of seven patients.

Discussion

The hypoglossal nerve supplies motor innervation to the intrinsic and extrinsic muscles of the tongue. Damage to the hypoglossal nucleus or hypoglossal nerve would be expected to cause denervation tongue atrophy (1-3). The initial microscopic event is probably degenera-

tion of the nerve axon and its branches distal to the site of damage, with consequent denervation of the distal muscles. In the condition of denervation, muscle fibers of the entire motor unit atrophy; thus, true muscle volume decreases. Fatty infiltration and fibrous change of the affected muscle ensue in the chronic stage (1).

The usefulness of radiologic evaluation for the denervated skeletal muscle has been reported, but reports concerning radiologic findings of hypoglossal denervation are limited (1-3). Harnsberger and Dillon (2) described a patient with a denervated tongue resulting from tumor invasion to the hypoglossal nerve, in whom several biopsies of the contralateral, normal tongue were done with the misdiagnosis of a tumor mass. Although radiologically abnormal findings of the tongue suggest inflammatory or neoplastic disease of the tongue, we must also consider the possibility of a denervated tongue and evaluate neurologic findings.

Radical neck dissection is the classic operation for cervical lymph node metastases (7). The cranial and cervical nerves are at risk for injury during neck dissection. Cranial nerves V and VII through XII, the phrenic and cervical nerves, the sympathetic plexus, and the brachial plexus, have been injured during surgery (7, 8). The frequency of unintentional injury of the nerves is less than 5%, but the risk increases with disease progression (7). Recently, the clinical importance of disability following radical neck dissection has been considered. Functional shoulder disability due to spinal accessory nerve injury has often occurred after radical neck dissection, and a tendency toward more conservative neck dissections with preservation of the spinal accessory nerve has been observed (9). Tongue disability after radical neck dissection must also be considered. The hypoglossal nerve courses over both internal and external carotid arteries, and is crossed twice by the digastric muscle at the submandibular triangle, where the hypoglossal nerve injury may occur during neck dissection. In patients in whom the primary tumor or lymph node metastases involve the submandibular triangle, there is an increased possibility of hypoglossal paralysis after this surgery.

Denervated muscles in the subacute phase appear isointense to hypointense relative to normal muscle on T1-weighted MR images and hyperintense on T2-weighted images (4, 5). This appearance is attributed to the relatively increased tissue water in the enlarged interstitial space of the affected muscle. Chronic denervation is characterized by development of fatty infiltration and atrophy of the muscle. Fatty infiltration is easily detected as increased T1 signal (4). Increased signal intensity relative to muscle on T2-weighted MR images is also consistent with fatty infiltration, but because increased extracellular water also has high signal, the T2-weighted appearance alone is not sufficient to distinguish between subacute and chronic denervation (4). In our cases, hyperintensity appeared on T1-weighted MR images obtained 5 or more months after radical neck

dissection. CT scans showed low density at each phase, presumably representing increased fatty infiltration (1–3).

Contrast enhancement of the denervated muscles is sometimes more prominent than that of the normal muscles. The mechanism of enhancement is thought to be as follows: blood flow to the denervated muscle is functionally increased relative to normal muscle, because the concentration or number of capillaries per volume of muscle increases as atrophy progresses (6). Furthermore, injected contrast material accumulates in the interstitial spaces, which are more prominent in atrophic muscle.

Abnormal imaging findings in the tongues of patients who have undergone neck dissection for malignant process suggest the possibility not only of recurrence with involvement of the hypoglossal nerve but also of postoperative change.

References

1. Larsson SG. Hemiatrophy of the tongue and floor of the mouth demonstrated by computed tomography. *J Comput Assist Tomogr* 1985;9:914–918
2. Harnsberger HR, Dillon WP. Major motor atrophic patterns in the face and neck: CT evaluation. *Radiology* 1985;155:665–670
3. Naidich TP, Pudlowski RM, Leeds NE, Deck MDF. Hypoglossal palsy: computed tomography demonstration of denervation hemiatrophy of the tongue associated with glomus jugulare tumor. *J Comput Assist Tomogr* 1978;2:630–632
4. Fleckenstein JL, Watumull D, Conner KE, et al. Denervated human skeletal muscle: MR imaging evaluation. *Radiology* 1993;187:213–218
5. Uetani M, Hayashi K, Matsunaga N, et al. Denervated skeletal muscle: MR imaging. *Radiology* 1993;189:511–515
6. Davis SB, Mathews VP, Williams DW III. Masticator muscle enhancement in subacute denervation atrophy. *AJNR Am J Neuroradiol* 1995;16:1292–1294
7. Million RR, Cassisi NJ, Mancuso AA, et al. Management of the neck for squamous cell carcinoma. In: Million RR, Cassisi NJ, eds. *Management of Head and Neck Cancer: A Multidisciplinary Approach*. 2nd ed. Philadelphia, Pa: Lippincott; 1994:75–142
8. Ewing MR, Martin H. Disability following radical neck dissection; an assessment based on the postoperative evaluation of 100 patients. *Cancer* 1952;5:873–883
9. Sobol S, Jensen C, Sawyer W II, et al. Objective comparison of physical dysfunction after neck dissection. *Am J Surg* 1985;150:503–509