

Generic Contrast Agents

Our portfolio is growing to serve you better. Now you have a *choice*.



[VIEW CATALOG](#)

AJNR

Clinical and radiologic findings in progressive facial hemiatrophy (Parry-Romberg syndrome).

R C Cory, D A Clayman, W J Faillace, S W McKee and C H Gama

This information is current as of May 22, 2025.

AJNR Am J Neuroradiol 1997, 18 (4) 751-757
<http://www.ajnr.org/content/18/4/751>

Clinical and Radiologic Findings in Progressive Facial Hemiatrophy (Parry-Romberg Syndrome)

Richard C. Cory, David A. Clayman, Walter J. Faillace, Shaun W. McKee, and Carlos H. Gama

Summary: We describe the clinical and radiologic changes related to progressive facial hemiatrophy (Parry-Romberg syndrome) occurring during a 20-month period in a child who presented with unilateral neurologic deficits and facial hemiatrophy. CT and MR findings included unilateral focal infarctions in the corpus callosum, diffuse deep and subcortical white matter signal changes, mild cortical thickening, and leptomeningeal enhancement with dense mineral deposition. Angiographic findings were normal. We hypothesize that a noninfectious, unilateral inflammatory process, possibly associated with a chronic vasomotor disturbance and sympathetic nerve chain inflammation, was a major factor in the pathogenesis of this syndrome.

Index terms: Face, atrophy; Children, diseases

Long after its description by Parry in 1825 and Romberg in 1846, progressive facial hemiatrophy syndrome remains a poorly understood entity (1–3). The major features of this syndrome, which have been reported previously, are atrophy of the soft tissues on one side of the face with hyperpigmentation of the overlying skin and various neurologic findings, including migraine-type headache, trigeminal neuralgia, and focal epilepsy. Imaging features consist of increased signal in the white matter on proton density- and T2-weighted magnetic resonance (MR) images, meningeal enhancement, intracranial calcifications, and central cerebral atrophy.

We present serial neuroimaging findings illustrating the progression of brain changes in a case of Parry-Romberg syndrome and speculate on the underlying pathogenesis of this disorder.

Case Report

We examined a 5½-year-old right-handed girl with normal developmental milestones. The mother's pregnancy

was complicated by gestational diabetes and preeclampsia; the patient's medical history was unremarkable for trauma or a major illness. Intermittent frontal headaches developed insidiously, without precipitating factors. The headaches averaged 2 hours in duration, were often accompanied by nausea and emesis, and were assuaged by acetaminophen and sleep. There were no prodromal auras and there was no family history of migraine headache. The headaches were accompanied by a mild expressive aphasia, dysesthesia in the right hand and leg, followed by transient hand paresis and clumsiness. Normal sensation and motor strength returned after cessation of the headaches.

Findings at neurologic examination between episodes of neurologic dysfunction were normal. Abnormal findings at computed tomography (CT) suggested a differential diagnosis of childhood hemiplegic migraine, cerebritis, or vasculitis, and prompted cerebral angiography and MR imaging.

After the first few headaches, skin atrophy and hyperpigmentation (coup de sabre) of the left side of the forehead below the hairline developed and progressed to involve the left eyelid and maxillary region lateral to the lip line (Fig 1). There was also loss of lashes around the left eye. The progressive facial changes established the diagnosis of progressive facial hemiatrophy.

CT and MR examinations were obtained during times of progressive atrophic changes in the patient's facial appearance. CT was performed without contrast enhancement. All MR examinations were performed on a 1.0-T system and included axial and sagittal T1-weighted sequences (733/20/2 [repetition time/echo time/excitations]) without and with contrast medium (0.1 mmol/kg gadopentetate dimeglumine) and noncontrast spin-density and T2-weighted sequences (3000/20,80/1).

The initial brain CT scan, obtained at age 5 years 7 months, showed small calcifications anteriorly in the left cingulate gyrus adjacent to the genu of the corpus callosum (Fig 2A). Linear sulcal and gyral calcifications were present in the superior lateral left frontoparietal region. Subtle low densities in the subcortical white matter of the

Received May 30, 1995; accepted after revision July 18.

From the Departments of Radiology (R.C.C., D.A.C., S.W.McK.), Neurosurgery (W.J.F.), and Neurology (C.H.G.), University of Florida Health Science Center/Jacksonville.

Address reprint requests to David A. Clayman, MD, Department of Radiology, University of Florida Health Science Center/Jacksonville, University Medical Center, 655 W 8th St, Jacksonville, FL 32209.

AJNR 18:751–757, Apr 1997 0195-6108/97/1804–0751 © American Society of Neuroradiology

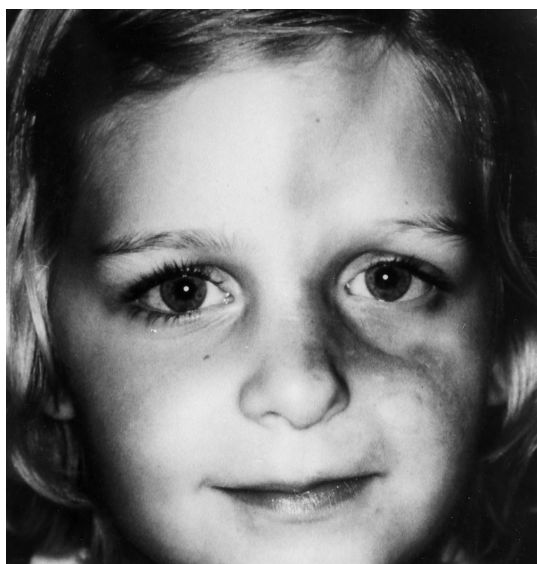

Fig 1. Left-sided facial changes in a 6-year-old girl with progressive facial hemiatrophy: skin atrophy and hyperpigmentation of the forehead (coup de sabre); periorbital, premaxillary, and perioral soft-tissue atrophy and hyperpigmentation; hair loss in the medial eyebrow; and loss of lashes along the medial eyelids.

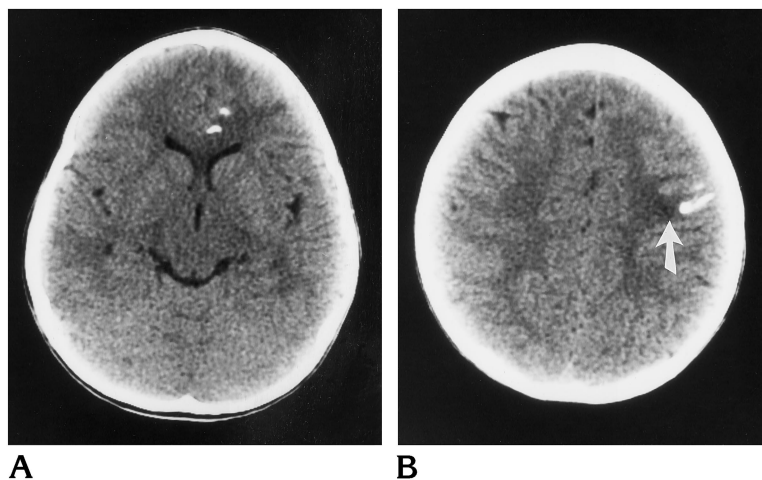


Fig 2. Axial noncontrast CT scans (at age 5 years 7 months) show calcifications and adjacent white matter decreased densities in the left frontal cingulate gyrus and corpus callosum (A) and in the superior lateral left frontoparietal parenchyma (arrow in B).

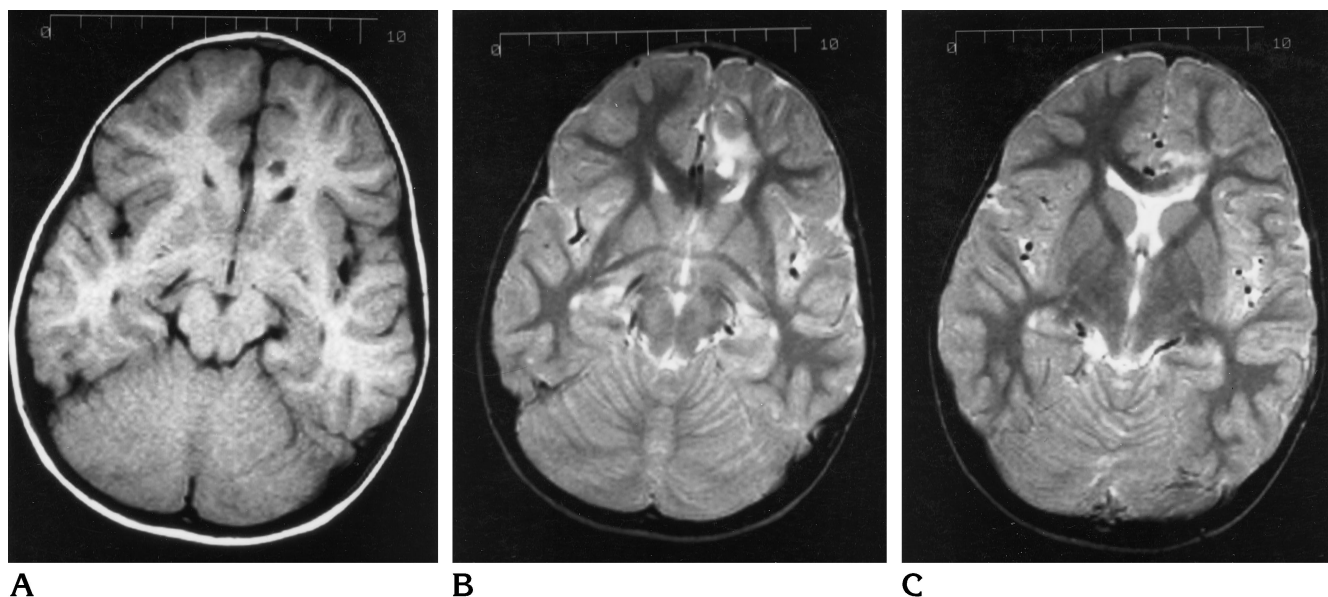


Fig 3. Axial noncontrast T1-weighted (A) and T2-weighted (B) MR images below the genu of the corpus callosum and T2-weighted image (C) through the level of the genu (at age 5 years 7 months) show focal low-signal abnormality in the left genu in A, becoming high signal in B, and showing more diffuse subcortical and subependymal white matter high signal changes in C.

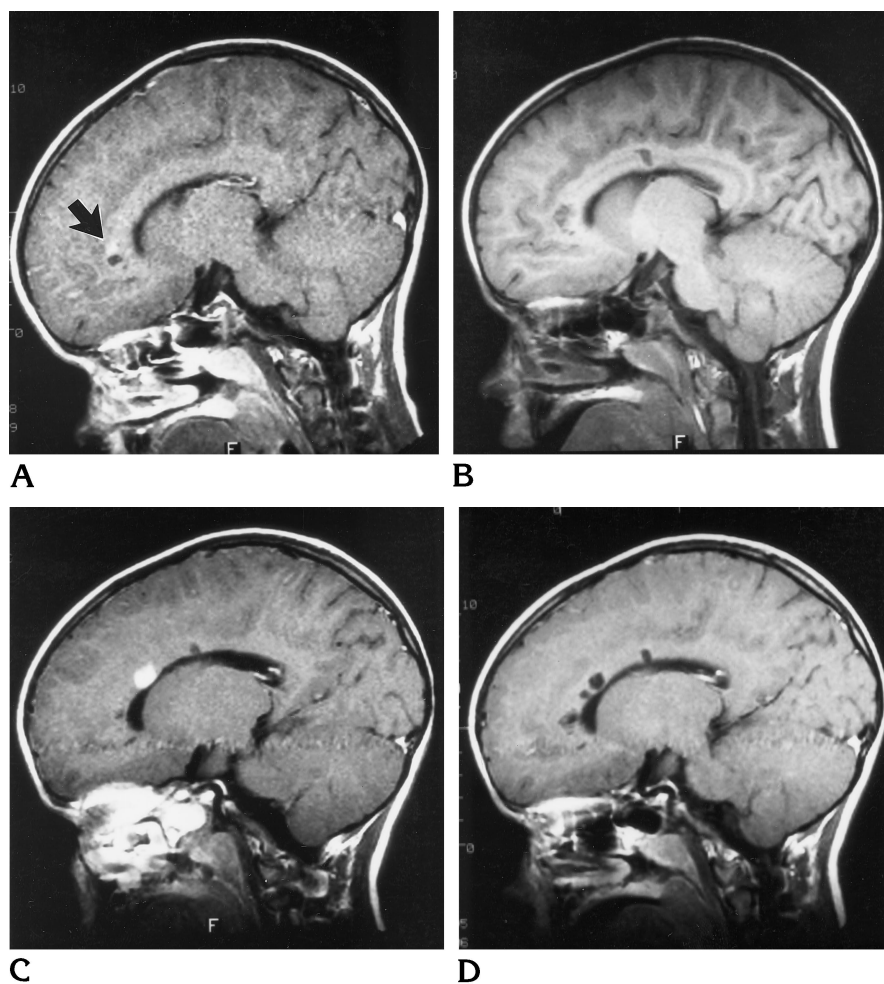


Fig 4. Serial parasagittal images of the patient over a period of 10 months show progression of the abnormal findings.

A, At age 5 years 7 months, a focal low signal abnormality is identified in the corpus callosal genu with a subtle area of enhancement superiorly (arrow).

B, At age 6 years, a new area of low signal has formed in the body of the corpus callosum, and enlargement of the genu abnormality is noted.

C, At age 6 years 1 month, a new high-signal enhancing focus is seen in the anterior aspect of the corpus callosal body.

D, Finally, at age 6 years 5 months, the lesion in the anterior body of the corpus callosum no longer enhances and now is hypointense.

left frontal and parietal regions were identified near the calcifications (Fig 2B). Cerebral atrophy was not present.

The first MR study, obtained the same day as the initial CT examination, showed a focal area of T1 and T2 prolongation at the site of the cingulate calcification identified on the CT scan (Fig 3A and B). Subtle enhancement superior to this focus was seen on the contrast-enhanced sagittal T1-weighted MR image (Fig 4A). T2-weighted MR images clearly showed abnormal hyperintensity in the subependymal aspect of the left corpus callosal genu (Fig 3C). Abnormal signal also extended anteriorly and laterally into the subcortical white matter of the cingulate gyrus and into the deep left frontal white matter (Fig 3B and C). Abnormal high signal in the left frontoparietal subcortical white matter extended into the centrum semiovale (Fig 5C). T1-weighted contrast-enhanced MR images showed sulcal/pial enhancement between the left frontoparietal gyri at the site of calcification shown on the CT scan and adjacent to the signal changes in the subcortical white matter (Fig 5B). More craniad axial T1- and T2-weighted MR images revealed a subtle thickening of the cortical gyri with mild effacement of the sulcal spaces (Fig 6A and B).

Findings on a four-vessel cerebral arteriogram were normal. Cerebrospinal fluid (CSF) and blood chemistries

were normal; CSF and blood cultures were without growth after 5 days. A sleep-deprived electroencephalogram (EEG) was initially normal. Repeat EEG testing revealed intermittent slowing of posterior rhythms in the absence of drowsiness, without obvious epileptiform activity.

Histologic examination of a skin biopsy specimen of the hyperpigmented left side of the forehead revealed chronic inflammation with atrophy of hair follicles. Culture and special staining of this specimen showed no abnormality. Brain biopsy was considered but ultimately deferred owing to confidence in the clinical diagnosis.

Serial follow-up MR examinations obtained during periods of worsening atrophy of the left facial structures at ages 6 years, 6 years 1 month, 6 years 5 months, and 7 years 3 months revealed progressive abnormal changes of the brain. T1-weighted images showed the development of several low signal foci in the left corpus callosum over a 9-month period (Fig 4B). One of these lesions, which showed bright contrast enhancement on T1-weighted images, evolved into a well-defined hypointensity over a 6-month interval (Fig 4C and D). Meningeal enhancement of the left parietal lobe persisted and did not increase over a 20-month period (Fig 7B). A modest progression of the abnormal white matter areas of hyperintensity seen on

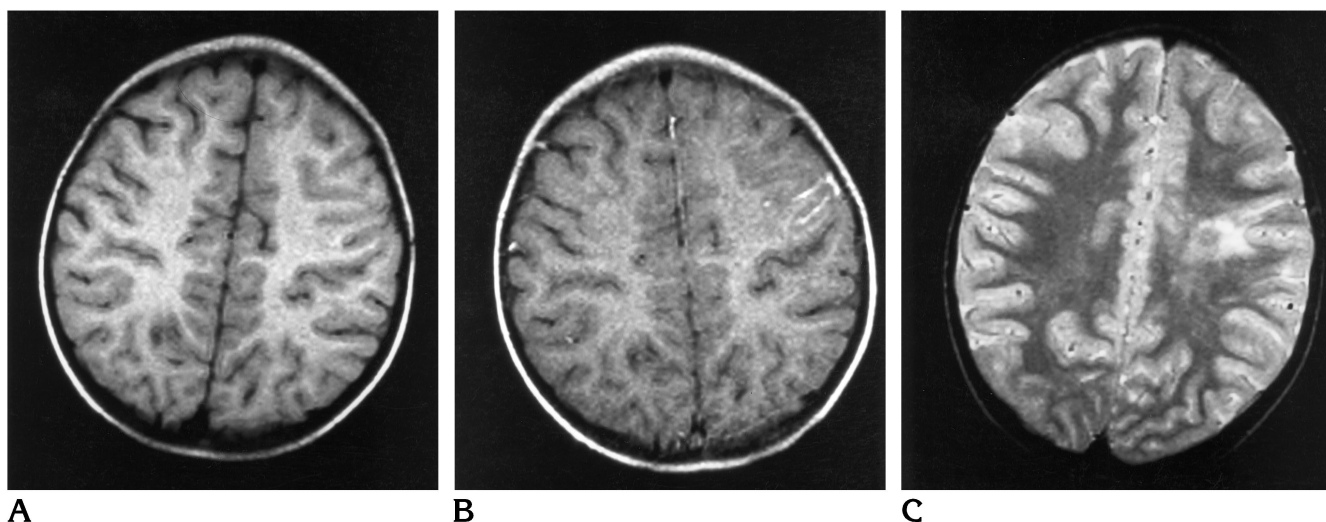


Fig 5. Axial noncontrast (A) and contrast-enhanced (B) T1-weighted MR images at the level of the centrum semiovale (at age 5 years 7 months) show sulcal/pial enhancement. Axial noncontrast T2-weighted image at the same level (C) shows abnormal subcortical high signal.

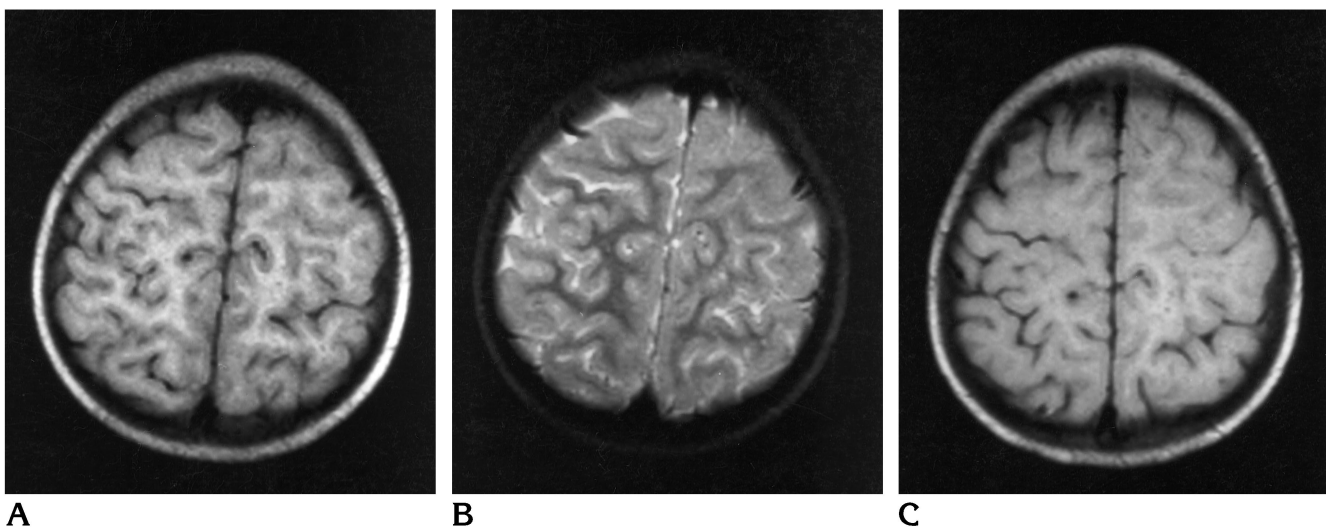


Fig 6. Axial noncontrast T1-weighted (A) and T2-weighted (B) MR images through the high frontal and parietal lobes (at age 5 years 7 months) show subtle cortical thickening with less definition of the gray-white border and sulcal effacement. Axial noncontrast T1-weighted MR image (C) obtained 10 months later shows mild progression of cortical changes.

spin-density and T2-weighted images occurred, which coincided with progression of facial atrophy (Fig 7C and D). A gradual increase of the cortical gyral thickening in the left parietal lobe was recognizable over time (Figs 6C and 7A, C, and D). A follow-up CT scan showed corpus callosal encephalomalacia and a progression of white matter low density in the left hemisphere (Fig 8A and B).

Discussion

Our patient had MR findings of acute, focal white matter enhancement with progression to

encephalomalacia, and a slowly progressive thickening of the cerebral cortex with overlying meningeal enhancement. The predominant findings were intraaxial with some areas of extraaxial leptomeningeal enhancement. Arteriographic findings were normal, similar to the experience of other authors (1, 3). CT and MR findings were actively progressive at the time of angiography.

Increased signal intensities in the cerebral white matter have been reported in other studies

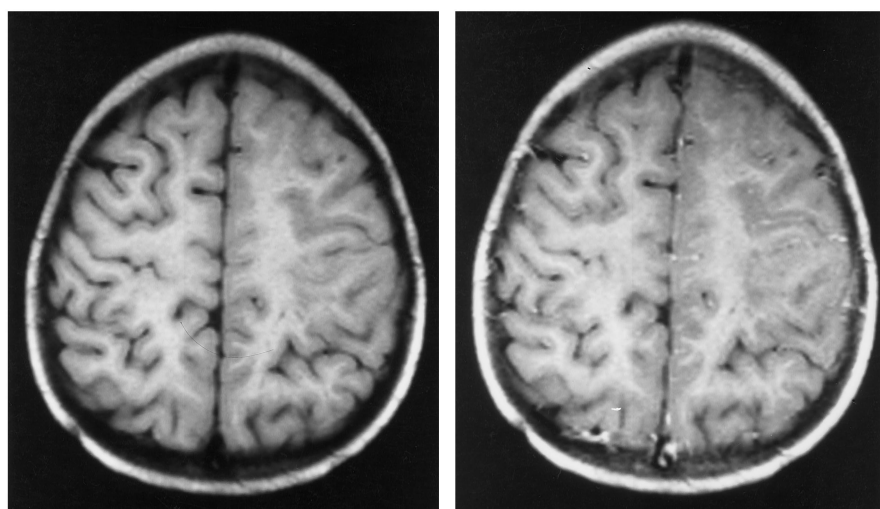
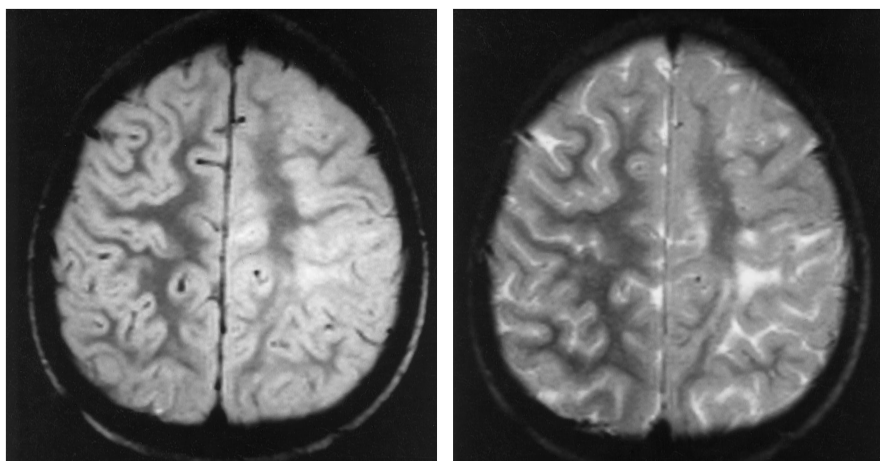
**A****B****C****D**

Fig 7. Axial noncontrast (A) and contrast-enhanced (B) T1-weighted images and spin-density (C) and T2-weighted (D) images through the frontal and parietal lobes above the lateral ventricles (at age 7 years 4 months) show mild cortical thickening involving the more frontal parenchyma. Subcortical white matter high signal changes are present (C and D). Pial enhancement is still present (B).

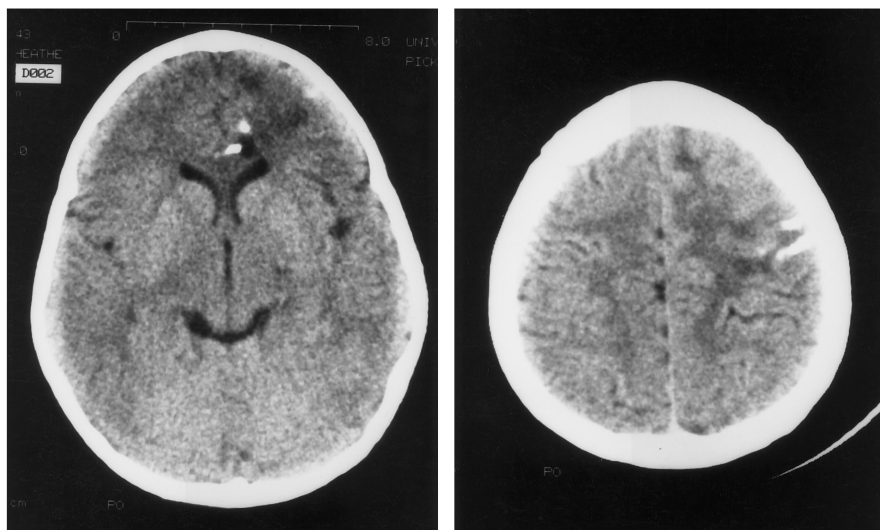
**A****B**

Fig 8. Noncontrast axial CT scans through the level of the frontal horns and corpus callosum (A) and through the high frontoparietal brain (B) (at age 6 years 5 months) show calcifications are relatively unchanged while white matter low densities in the left hemisphere have progressed.

of progressive facial hemiatrophy syndrome (1). Terstegge et al (2) reported meningocortical dysmorphism, meningeal enhancement, and central atrophy at MR imaging and proposed that meningoencephalitis with vasculitis was the mechanism underlying the morphologic brain changes in this disorder. The predominate intraaxial, as opposed to extraaxial, manifestations in our case do not completely support this hypothesis. The cortical thickening and enhancement in our patient do support meningocortical dysmorphism as described by Terstegge et al, but in our patient the dysmorphism occurred without development of atrophy. Intracranial calcifications (1, 3–5) as well as cerebral hypodensities have also been reported (2, 4).

Unilateral cerebral changes ipsilateral to the facial atrophy as seen in our case have been described by others (1–4). However, our case differs from other studies, which have reported contralateral cerebral involvement. Most references to contralateral intracranial disease were nonspecific and were inferred from findings on skull radiographs (6) or from the presence of ventriculomegaly seen on pneumoencephalograms (3, 6). In one case a CT finding of focal increased density in the contralateral hemisphere was described (3). The finding was nonspecific but raised the possibility of bilateral disease in a case of progressive facial hemiatrophy syndrome.

The pathogenesis of progressive facial hemiatrophy has eluded investigators. Trauma has been implied, but trauma is an inconsistent feature (3). In 1945, Wartenberg (7) ascribed cases of scleroderma with streaklike facial atrophy (coup de sabre) to “abortive progressive facial hemiatrophy.” Other reports have suggested that the opposite is true: that progressive facial hemiatrophy is a form of focal scleroderma (5, 8). The diagnostic differentiating feature between the two is the preservation of elastic tissue at histologic examination in progressive facial hemiatrophy. Encephalitis, complicated migraine, and slow virus infection have also been advanced as possible causes (4, 8).

Several authors have proposed that progressive facial hemiatrophy results from a disturbance leading to sympathetic nervous system hyperactivity (7, 9, 10). Wartenberg (7) stated that trophism of the fat and subcutaneous tissues is under the influence of the sympathetic nervous system. Moss and Crikelair (9) pro-

duced a condition resembling progressive facial hemiatrophy by performing a unilateral sympathectomy in rats. More recently, Resende et al (10) ablated the superior cervical sympathetic ganglion in young rabbits, cats, and dogs, and reproduced the principal clinical alterations of Parry-Romberg syndrome. In humans, no case of progressive facial hemiatrophy has occurred after cervical sympathectomy. The disease most commonly occurs during the first or second decade of life, when facial and head growth might be most affected. We suggest that the clinical features of Parry-Romberg syndrome may not be apparent if sympathectomy occurs after facial maturation and cessation of head growth.

In contrast, many authors have reasoned that a pathologic state of sympathetic irritation leads to the facial hemiatrophy and, as a result, periarterial sympathectomy has been performed with some success in order to halt the progression of facial atrophy (8). Tebloev and Kalashnikov (11) reported 19 patients in whom facial hemiatrophy developed after the onset of ganglionitis of the superior cervical sympathetic ganglion, brain stem encephalitis, trigeminal neuralgia, tumors of the gasserian ganglion, and syringobulbia. These authors proposed a pathologic relationship between the development of symptomatic facial hemiatrophy and lesions of the mesencephalotrunical and superior cervical sympathetic ganglion structures. If the sympathetic nervous system is responsible, it remains unclear whether facial atrophy results from postinflammatory hypofunctioning of the sympathetic nerves or from sympathetic hyperactivity in the presence of active inflammation.

Anatomically, the internal carotid nerves arise from the superior cervical ganglia and give rise to the medial and lateral internal carotid plexus. The lateral plexus communicates with lower cranial and deep facial nerves and ganglia, while the medial plexus communicates with upper cranial nerves. Terminal filaments from the internal carotid plexus course around the cerebral arteries (12).

We postulate that the CT and MR imaging findings in progressive facial hemiatrophy represent a diffuse, slowly progressive and self-limited inflammatory process. We suggest that the more focal changes represent an accelerated and local manifestation of the same pathologic process. Our case reveals the initial dynamic evolution of progressive facial hemiat-

rophy and demonstrates the first phases of a chronic, progressive disease course that is punctuated by acute exacerbations. We disagree with Fry et al (1), who discounted the theory of a trigeminal or sympathetic innervation abnormality. Instead, we favor the hypothesis of hyperactivity of the sympathetic nervous system, specifically, inflammation of the superior cervical ganglion in a young patient, as the cause of progressive facial hemiatrophy. The division of the sympathetic nervous system into right and left and the distribution of medial and lateral internal carotid nerve branches provide an anatomic basis for the unilateral facial and intracranial manifestations of the disease. The hyperactive vasomotor tone of the intracranial vasculature might explain migraine symptomatology and normal cerebral angiography. Last, recent animal studies and clinical series lend support to the hyperactive sympathetic nervous system hypothesis as the etiologic mechanism responsible for progressive hemifacial atrophy syndrome (8–11).

Acknowledgments

We thank Dorothy Shumate for her kind assistance in searching the literature and preparing the manuscript and L. Habelson Wilf and Robert P. Booth for their assistance in editing the manuscript.

References

1. Fry JA, Alvarellos A, Fink CW, Blaw ME, Roach ES. Intracranial findings in progressive facial hemiatrophy. *J Rheum* 1992;19:956–958
2. Terstegge K, Kunath B, Felber S, Speciali JG, Henkes H, Hosten N. MR of brain involvement in progressive hemifacial atrophy (Romberg disease): reconsideration of a syndrome. *AJNR Am J Neuroradiol* 1994;15:145–150
3. Aher SW, Berg BO. Progressive hemifacial atrophy: report of 3 cases, including one observed over 43 years, and CT findings. *Arch Neurol* 1992;39:44–46
4. Sagild J, Alving J. Hemiplegic migraine and progressive hemifacial atrophy. *Ann Neurol* 1985;17:620
5. Merritt KK, Faber HK, Bruch H. Progressive facial hemiatrophy: report of two cases with cerebral calcifications. *J Pediatr* 1937;10:374–395
6. Eadie MJ, Sutherland JM, Tyrer JH. The clinical features of hemifacial atrophy. *Med J Austr* 1963;50:177–180
7. Wartenberg R. Progressive facial hemiatrophy. *Arch Neurol Psychiatry* 1945;54:75–97
8. Rogers BO. Progressive facial hemiatrophy: Romberg's disease: a review of 772 cases. *International Congress Series 66*. Washington, DC: Excerpta Medica Foundation; 1963:681–689
9. Moss ML, Crikelair GF. Progressive facial hemiatrophy following cervical sympathectomy in the rat. *Arch Oral Biol* 1959;1:254–258
10. Resende LA, Pai DV, Alves A. Experimental study of progressive facial hemiatrophy: effects of cervical sympathectomy in animals [in French]. *Rev Neurol (Paris)* 1991;147:609–611
11. Tebloev IK, Kalashnikov IuD. Pathogenesis of symptomatic facial hemiatrophy [in Russian]. *Zh Neuropatol Psikiatr Im S S Korsakova* 1979;79:413–416
12. Gray H; Goss CM, ed. *Gray's Anatomy of the Human Body*. 29th ed. Philadelphia, Pa: Lea & Febiger; 1973:1013–1014