

Generic Contrast Agents

Our portfolio is growing to serve you better. Now you have a *choice*.



[VIEW CATALOG](#)

AJNR

Transient obstruction of the internal carotid artery during angiography.

D T Cross, 3rd and B T Allen

AJNR Am J Neuroradiol 1997, 18 (6) 1186-1188

<http://www.ajnr.org/content/18/6/1186>

This information is current as
of May 23, 2025.

Transient Obstruction of the Internal Carotid Artery during Angiography

DeWitte T. Cross III and Brent T. Allen

Summary: While performing carotid angiography in a 76-year-old man, we found that the right internal carotid artery repeatedly opened and closed during the examination. The patient experienced no related neurologic events. The explanation, confirmed at surgery, was that a flap associated with an atherosclerotic plaque had acted as a ball valve.

Index terms: Angiography, complications; Arteries, carotid, internal

The development of a sudden occlusion of the internal carotid artery (ICA) during otherwise routine common carotid angiography might not only cause some distress for the angiographer but also lead to some potentially catastrophic consequences for the patient. Proceeding to direct fibrinolytic therapy or to emergent endarterectomy would be two possible courses of action. In this case, the patient experienced no symptoms while the ICA alternated between patent and obstructed states on serial injections. Once the artery had been examined at surgery, the angiographic findings became understandable, and traditional management proved appropriate.

Case Report

A 76-year-old man was referred for carotid angiography. He had had a transient ischemic attack about a month before the angiographic procedure, with symptoms of left arm and facial weakness lasting 6 hours. Smoking was his only risk factor for stroke. There was no carotid bruit on examination. Doppler sonography revealed 50% to 79% stenosis of the right ICA origin. A computed tomographic (CT) scan of the brain showed no infarction. He was a candidate for carotid endarterectomy.

Angiography was performed with the use of a local anesthetic and conscious sedation of the patient (intravenous fentanyl and midazolam). All images were obtained on a biplane digital subtraction unit using nonionic contrast material. After placing a 5F femoral artery sheath

(Optilock, Cook Inc, Bloomington, Ind) and performing biplane arch aortography with a 5F pigtail catheter (Mallinckrodt Medical, St Louis, Mo), we used a 5F H1 catheter (Cook Inc) to select easily the right common carotid artery over a hydrophilic guidewire (Roadrunner, Cook Inc). Two initial right common carotid artery injections were performed to evaluate the right carotid bifurcation in four projections. Contrast material was injected at 5 mL/s for a volume of 7 mL for each of these biplane sequences. The initial images obtained of the right carotid bifurcation revealed 50% stenosis of the right ICA origin and normal, brisk flow through the ICA (Fig 1A and B). A linear contrast defect parallel to the artery on an early arterial phase image (Fig 1A) that disappeared later in the arterial phase (Fig 1B) was assumed to represent a flow-related phenomenon rather than an intimal flap. This linear defect appeared and disappeared on subsequent bifurcation sequences.

The table, tubes, and image intensifiers were repositioned for an angiographic evaluation of the cranial vessels while the patient's head position on the table remained unchanged. The initial cranial images were obtained using a faster injection rate and larger contrast volume (7 mL/s for a total of 11 mL) than for the preceding bifurcation imaging. The contrast material only opacified the external carotid branches in the early arterial phase (Fig 1C) then slowly trickled up the ICA in the late arterial phase (Fig 1D), behavior similar to that of an ICA with a stringlike origin stenosis and not predictable from the preceding angiographic runs. The catheter position was reassessed fluoroscopically. The catheter tip was unchanged, well below the carotid bifurcation; the catheter could not have delivered the contrast material selectively into the external carotid artery to explain the contrast distribution.

The patient had experienced no neck pain during the injections and, at clinical examination, was found to be neurologically intact.

With another common carotid injection, images were obtained to evaluate the ICA from the bifurcation to the siphon. This and all subsequent carotid injections were obtained with the original injection parameters, 5 mL/s for a volume of 7 mL. ICA flow was severely slowed, a distinct change from the first images of the bifurcation, but the

Received April 25, 1996; accepted after revision September 18.

From the Departments of Radiology (D.T.C.) and Surgery (B.T.A.), Washington University School of Medicine, St Louis, Mo.

Address reprint requests to DeWitte T. Cross III, MD, Department of Radiology, Washington University, 510 S Kingshighway, St Louis, MO 63110.

AJNR 18:1186-1188, Jun 1997 0195-6108/97/1806-1186 © American Society of Neuroradiology

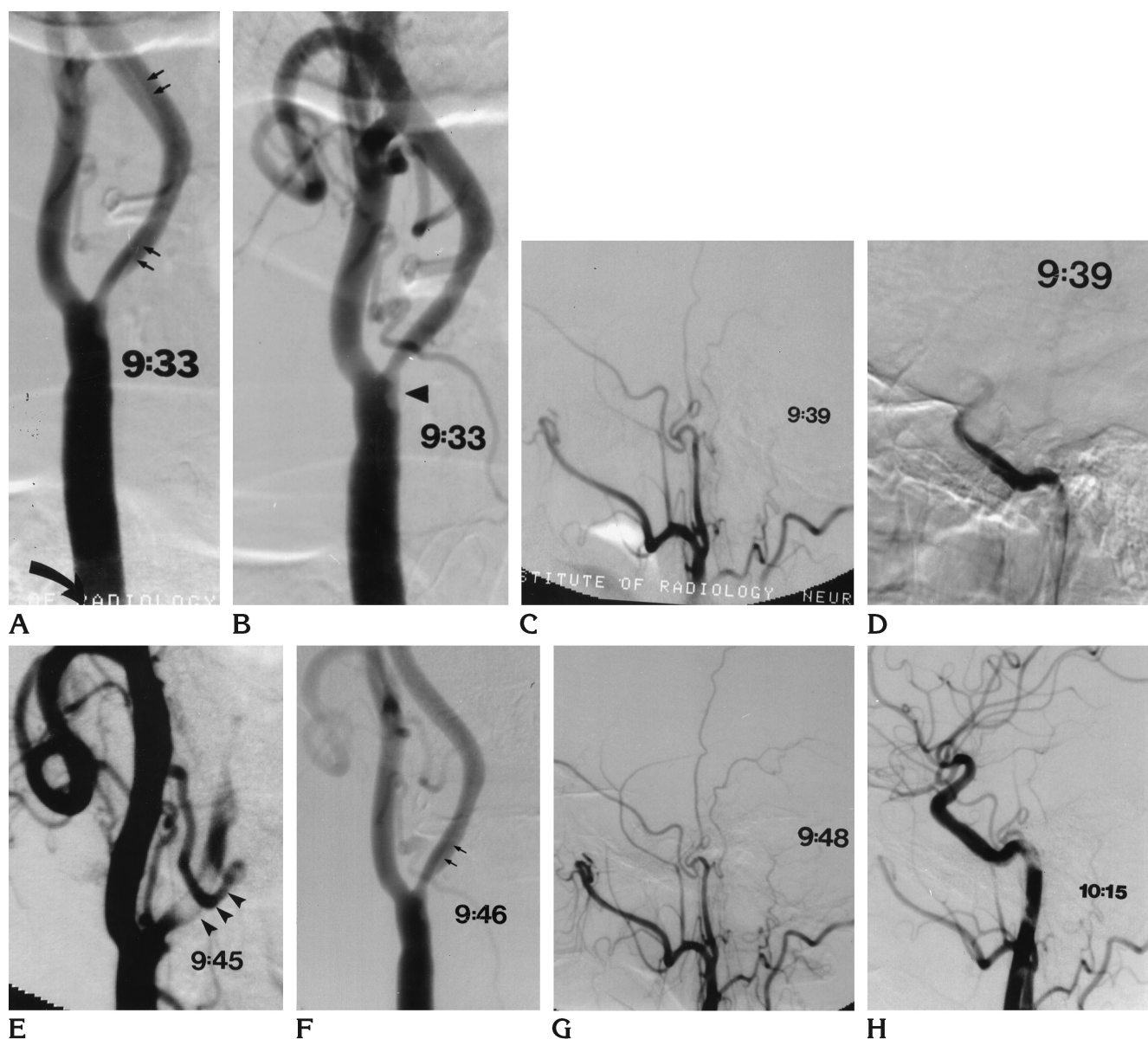


Fig 1. Serial right common carotid injections labeled with injection times in 76-year-old man with stenosis of the right ICA.

A and B, Initial bifurcation views. In A, straight arrows indicate a linear defect at the ICA origin that disappears later in the arterial phase (B). Curved arrow indicates catheter tip. Arrowhead in B indicates plaque.

C and D, Initial cranial views show early filling of external carotid artery branches and delayed filling of ICA.

E and F, Repeat examinations of the bifurcation. Arrowheads in E indicate large filling defect originally thought to be a clot that had migrated. Arrows in F indicate reappearance of linear defect at ICA origin.

G, Reexamination of the cranial vessels shows no flow in the ICA.

H, Another examination of cranial vessels now shows normal flow in ICA intracranially. There are no visible emboli to ICA branches.

reason for the change in flow was not known with certainty. A thrombus was suspected on the basis of a filling defect that appeared at the ICA origin (Fig 1E). The table and intensifiers were repositioned over the carotid bifurcation, and the common carotid artery was reinjected. These images (Fig 1F) showed a return to normal flow in the ICA and no evidence of clot obstructing the lumen.

The cranial vessels were then reevaluated with another common carotid injection. This study (Fig 1G) indicated

that the ICA had become completely occluded; no contrast material was seen to enter the ICA even late into the sequence. The patient remained surprisingly asymptomatic.

After recentring to reevaluate the ICA from the bifurcation to the siphon, another common carotid injection centered at the bifurcation showed an unexpected return to normal flow in the ICA. Imaging of the cerebral vessels was finally accomplished (Fig 1H) to scrutinize for suspected

migration of thrombus from the ICA origin, but there were no emboli evident in the ICA branches. Subsequent injections of the left common carotid artery and the right vertebral artery were notable for the absence of any circle of Willis or leptomeningeal collaterals to the right carotid territory.

The patient received anticoagulative therapy with intravenous heparin overnight and underwent right carotid endarterectomy with a local anesthetic the following morning. At surgery, a flap at an atherosclerotic plaque of the ICA origin was found. Recovery was uneventful and the patient has remained symptom free in the year since surgery.

Discussion

The cause for the changing hemodynamics of the ICA on serial common carotid injections was an intermittently obstructive flap within atherosclerotic plaque at the ICA origin, a flap with a ball-valve effect. Mobile atherosclerotic plaques in the thoracic aorta have been well described in the literature on transesophageal echocardiography, and an increase in the frequency of mobile aortic plaques has been noted in stroke patients (1). This case is an example of what a mobile atherosclerotic plaque within the ICA can do.

It is possible that the initial, relatively small contrast injections used for the bifurcation images did not close the flap, while the larger injection used for the first cranial imaging sequence exerted enough force to temporarily close the flap. In view of the lack of symptoms related to the procedure and lack of collaterals from other territories, it is presumed that the ICA did not remain obstructed for long after any injection.

Carotid occlusions have been well described in association with dissections (2, 3), and spontaneous recanalizations of carotid occlusions associated with dissections and with atherosclerotic disease have been reported (4–6), but those recanalizations have occurred after intervals of days to months.

In the event of sudden ICA obstruction or occlusion during common carotid angiography, one should, after assessing the patient and catheter position, repeatedly reevaluate the artery angiographically, with varying injection rates and volumes, if necessary, to look for evidence of an atherosclerotic mobile plaque and for any abrupt return to normal flow. Such findings would help allay fears that an occlusive thrombus or embolus was responsible for the sudden change in hemodynamics and better guide surgical or endovascular management.

References

1. DiTullio MR, Sacco RL, Gersony D, et al. Aortic atheromas and acute ischemic stroke: a transesophageal echocardiographic study in an ethnically mixed population. *Neurology* 1996;46:1560–1566
2. Houser OW, Mokri B, Sundt TM Jr, Baker HL Jr, Reese DF. Spontaneous cervical cephalic arterial dissection and its residuum: angiographic spectrum. *AJNR Am J Neuroradiol* 1984;5: 27–34
3. Mokri B, Sundt TM Jr, Houser OW, Piepgras DG. Spontaneous dissection of the cervical internal carotid artery. *Ann Neurol* 1986; 19:126–138
4. Sindermann F, Brugel R, Giedke H. Spontaneous recanalization of internal carotid artery occlusions. *Neuroradiology* 1974;7:53–56
5. Cusick JF, Daniels D. Spontaneous reversal of internal carotid artery occlusion: case report. *J Neurosurg* 1981;54:811–813
6. Kapp JP, Smith RR. Spontaneous resolution of occlusive lesions of the carotid artery. *J Neurosurg* 1982;56:73–79