

Generic Contrast Agents

Our portfolio is growing to serve you better. Now you have a *choice*.



[VIEW CATALOG](#)

AJNR

Direct thrombolysis of superior sagittal sinus thrombosis with coexisting intracranial hemorrhage.

J R Rael, W W Orrison, Jr, N Baldwin and J Sell

AJNR Am J Neuroradiol 1997, 18 (7) 1238-1242

<http://www.ajnr.org/content/18/7/1238>

This information is current as
of May 21, 2025.

Direct Thrombolysis of Superior Sagittal Sinus Thrombosis with Coexisting Intracranial Hemorrhage

Jesse R. Rael, William W. Orrison, Jr, Nevan Baldwin, and James Sell

Summary: We present a case of dural cerebral venous thrombosis with coexisting left frontal hemorrhage that was successfully treated with 13.79 million units of urokinase over a period of 165 hours.

Index terms: Dural sinuses; Thrombosis, dural sinus; Thrombolysis

Since the description of cerebral venous thrombosis by Ribe in 1824, numerous articles have been published detailing the wide spectrum of clinical presentations, radiographic findings, and therapeutic options associated with this disorder (1). Recent articles have shown that direct thrombolysis of dural venous sinus thrombosis should be considered for the acutely deteriorating patient who has not responded to conventional medical therapy (2–6). It may be necessary to consider thrombolytic therapy in the setting of parenchymal hemorrhage associated with venous infarction. Intracranial hemorrhage may not be an absolute contraindication for local urokinase therapy in the symptomatic patient with dural venous sinus thrombosis; a few cases have been reported in which thrombolysis was performed for thrombosis of the superior sagittal sinus in conjunction with cerebral hemorrhage (5, 6). In this report, we describe a severely symptomatic patient with dural venous sinus thrombosis and intracranial hemorrhage who was successfully treated with direct urokinase infusion.

Case Report

A 20-year-old woman had a 1-day history of headache, confusion, seizure, and progressive deterioration of mental status. She was transferred to our institution after a cranial computed tomographic (CT) scan showed a left-sided frontal hemorrhage. The patient's medical history was sig-

nificant for asthma, bronchitis, and oral contraceptive use. On physical examination, there was symmetric withdrawal to noxious stimuli, no verbal response, and no eye opening (Glasgow coma score 6).

Endotracheal intubation was performed and a repeat CT study revealed no change in the left frontal lobe hemorrhage (Fig 1A). Results of baseline coagulation studies and a hypercoagulable panel were normal. The pathogenesis of the dural venous thrombosis was thought to be associated with the use of birth control pills. Because of the patient's initially stable condition and known intracranial hemorrhage, treatment began with anticoagulation and mannitol instead of direct intradural thrombolysis. Intravenous heparin was started with a loading dose of 5000 U and a maintenance dose of 1000 U/h. Six hours later, the patient deteriorated acutely, exhibiting decerebrate posturing with fixed and dilated pupils bilaterally. A repeat cranial CT scan showed obliteration of sulci and basilar cisterns, compatible with diffuse cerebral edema (Fig 1B). A magnetic resonance (MR) study confirmed abnormally increased T1-weighted signal in the superior sagittal sinus, compatible with methemoglobin (Fig 1C). (MR angiography was not available at our institution at the time of this patient's admission.) An emergency angiogram revealed occlusion of the superior sagittal sinus, faint opacification of the transverse sinuses, and propagation of thrombus to cortical veins (Fig 1D and E). The 5F vascular sheath used for the first cerebral angiogram was removed prior to heparinization but in retrospect would have been of benefit if left in place. Great care was taken during the repuncturing of the femoral vessels while the patient was on heparin. Because of the life-threatening deterioration of clinical status and the propagation of thrombus, a decision was made to proceed with thrombolysis.

Using a right transfemoral vein approach, we gently transgressed the thrombosed right internal jugular vein and the sigmoid, right transverse, and superior sagittal sinuses to the level of the torcular Herophili using a twistable hydrophilic guidewire and angled 45° catheter.

The twistable wire was removed and a side-hole infusion wire was introduced via the guiding catheter to the

Received September 27, 1995; accepted after revision October 9, 1996.

From the Departments of Radiology (J.R.R., W.W.O., J.S.), Neurology (J.R.R., W.W.O.), and Surgery (N.B.), the University of New Mexico School of Medicine, Albuquerque.

Address reprint requests to Jesse R. Rael, MD, Department of Radiology, the University of New Mexico, Albuquerque, NM 87131.

AJNR 18:1238–1242, Aug 1997 0195-6108/97/1807–1238 © American Society of Neuroradiology

anterior aspect of the superior sagittal sinus. A sinus venogram confirmed the presence of extensive thrombus involving the entire superior sagittal sinus to the torcular Herophili (Fig 1F). Thrombolysis of the superior sagittal sinus was initially performed with 250 000 U of urokinase in a pulse-spray manner through the side-hole infusion wire over a period of 2 hours. A sinus venogram after urokinase infusion revealed improvement in cortical vein flow but persistent thrombus within the sinus.

Urokinase was administered by means of a constant infusion method at a rate of 80 000 U/h (20 000 U/h via angled guiding catheter; 60 000 U/h via side-hole infusion wire). Fibrinogen levels were monitored every 4 to 6 hours during the course of the urokinase infusion. A continuous heparin infusion was used to maintain the partial thromboplastin time at twice that of the control value.

The side-hole infusion wire was repositioned so as to lyse the entire superior sagittal sinus thrombus. A cranial CT scan revealed improved visibility of the basilar cisterns with no change in the frontal lobe hemorrhage.

Daily dural venography performed via the infusion wire and in the venous phase via carotid artery injections revealed progressive lysis of the dural vein thrombus. The overall infusion time was 165 hours, with a total urokinase dose of 13.79 million units. Repeat venography revealed progressive lysis of the dural sinuses with improved blood flow. Daily cranial CT scans revealed no change in the left frontal lobe hemorrhage.

At 1 week, venography revealed near total lysis of superior sagittal and transverse sinus thrombus (Fig 1G and H). The infusion wire and 45° and guiding catheters were removed. A cranial CT obtained on the last day of infusion showed evolution of the left frontal hemorrhage without new hemorrhage (Fig 1I). The first signs of consciousness occurred at day 4 of thrombolysis. At this time, the patient was somnolent but arousable. She recognized family and would nod appropriately to simple questions. At the time of catheter and wire removal, she was awake and oriented with no focal sensory or motor abnormalities. Extubation was difficult because of the patient's asthma and bronchitis, but was accomplished 17 days after admission. Anticoagulation therapy was converted from heparin to warfarin. She was discharged after a 30-day hospital stay with no focal neurologic deficit, although neuropsychiatric testing revealed a mild impairment in the area of numerical processing. Warfarin was maintained for 6 months. A subsequent follow-up MR venogram showed flow signal throughout the superior sagittal sinus. Altered signal in the posterior superior sagittal sinus was thought to be turbulent flow artifact (Fig 1J).

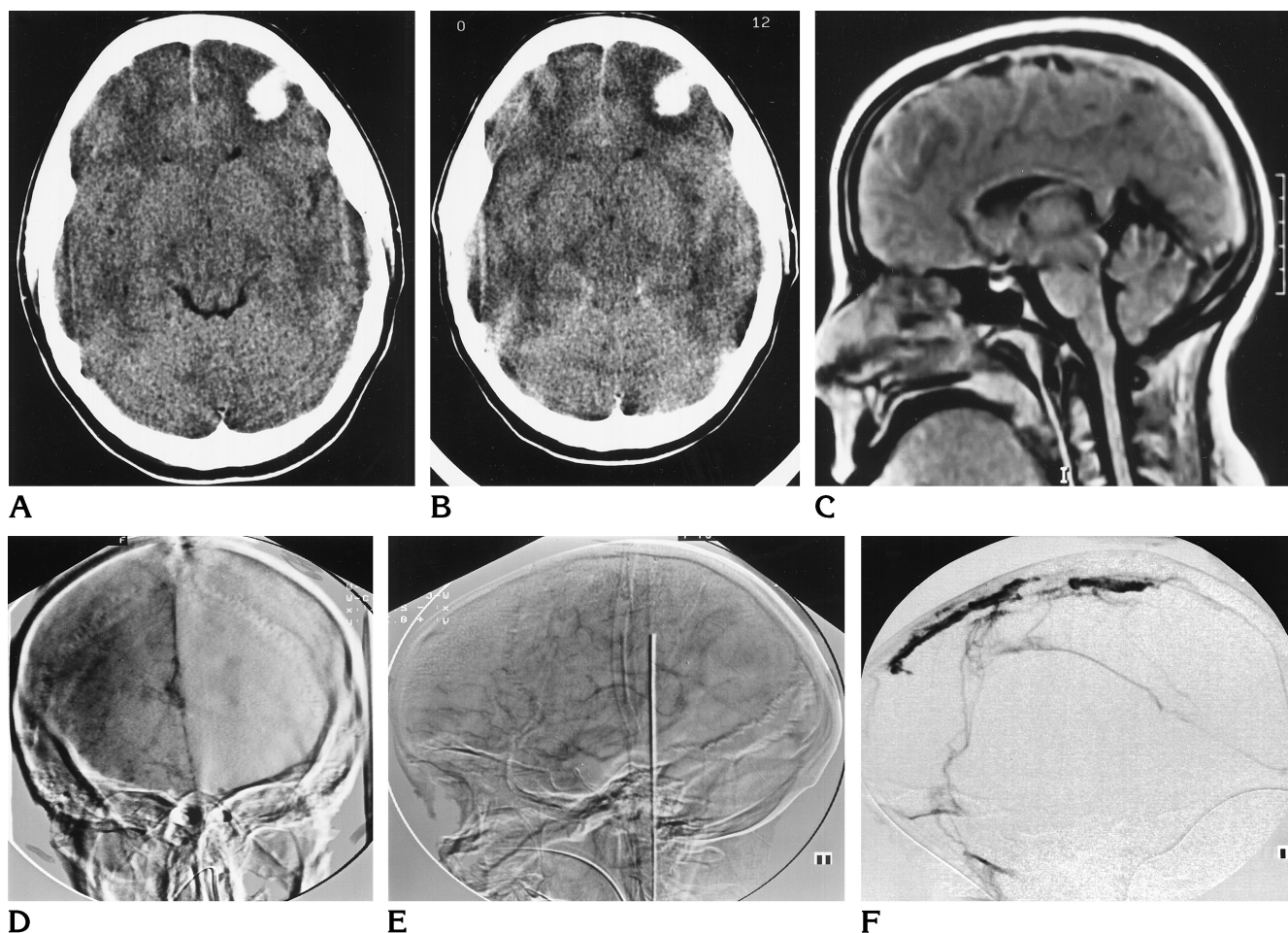
Discussion

Acute occlusion of the superior sagittal sinus, particularly the posterior half, and the dominant transverse and sigmoid sinuses can lead to significant cerebral edema, increased intracranial

pressure, hydrocephalus, and venous congestion with resulting hemorrhage and/or infarction (4, 7). Recanalization of the affected vessels is essential for patients with severe symptoms, particularly if collateral vessels are absent or thrombosed. Presently, direct thrombolytic therapy should be considered for patients in whom medical therapy fails or in those who deteriorate clinically (2, 3, 6). Experience with thrombolysis in the setting of sinus thrombosis with coexisting cerebral hemorrhage is limited (3, 6). Initially, thrombolytic therapy was considered in our case after the first angiogram. However, because of the patient's initial clinical stability, we decided that treatment with heparin was most appropriate. When the patient showed further clinical deterioration, with CT findings of increased cerebral edema and impending herniation, the decision to proceed with thrombolytic therapy was considered imperative.

Much of what we know about thrombolysis comes from others' experience with thrombolysis of arterial and bypass graft occlusions (8–10). It has been shown that optimal thrombolysis is best achieved when urokinase is infused directly into the thrombus, as opposed to peripheral intravenous administration (11). Other investigators have reported shortened time to thrombolysis by using a pulse-spray technique through side-hole catheters, because intrathrombotic injection of urokinase macerates the clot and augments the amount of its interactive area (6, 9, 11). It was postulated in our case that localized thrombolysis of the superior sagittal sinus with urokinase would minimize perfusion of infarcted or damaged brain tissue and lessen the risk of additional brain hemorrhage. Regarding the risk of a systemic fibrinolytic state, it was further postulated that direct thrombolytic therapy would minimize the risk of a systemic fibrinolytic state because of the limited circulation and short half-life of urokinase (11 to 16 minutes) (12). Data from studies in which recombinant tissue plasminogen activator was given for acute ischemic stroke have shown no systemic hemorrhagic complications (13, 14).

The use, optimal technique, and dosage for intrathrombotic infusion of urokinase in the thrombosed dural sinus have not been well defined, particularly in those patients with preexisting parenchymal hemorrhage. Horowitz and colleagues (6) reported 13 patients with dural sinus thrombosis treated with selective catheter-



terization and urokinase therapy. In their series, 11 of 12 patients had good outcomes, including four patients with hemorrhagic infarcts. Higashida and coauthors (5) described direct thrombolysis in a newborn child with superior sagittal sinus thrombosis and coexisting parenchymal hemorrhage. Unfortunately, the thrombolytic dose may be difficult to correlate with hemorrhage (3, 11, 13, 14). Administered doses of urokinase should therefore be kept as low as possible to minimize the risk of hemorrhage. Reported urokinase doses and infusion times vary among authors, ranging from 250 000 U to 500 000 U (3, 7) for the initial bolus; however, 250 000 U administered over 1 hour seems to be the most common. Long-term dural sinus infusion doses of 80 000 to 200 000 U have been reported without significant fibrinolysis (2, 3, 6). In the present case, an initial dose of 250 000 U of urokinase was administered over 2 hours using a pulsed-spray technique. Urokinase was then infused at a rate of 80 000 U/h for a total infusion time of 165

hours. Daily cranial CT scans revealed no propagation of the preexisting parenchymal hemorrhage or areas of new hemorrhage. The absence of rehemorrhage was verified by an independent review of CT scans performed by a neuro-radiologist who was blinded to the details of the case. Daily fibrinogen levels were normal; however, normal fibrinogen levels do not ensure against a fibrinolytic state. The correlation of abnormal plasma fibrinogen levels with the risk of hemorrhage appears to be weak at best (11). The absence of additional hemorrhage probably had nothing to do with monitoring fibrinogen levels but rather with the negligible risk of local thrombolytic therapy. In our case, we probably would have discontinued the urokinase if levels had dropped below 100 mg/dL, a level that has been reported as necessary for systemic hemostasis (12).

A case of parenchymal brain hemorrhage associated with thrombolysis of the dural sinus has been reported (15). In that case, both the urokinase and heparin were subsequently dis-

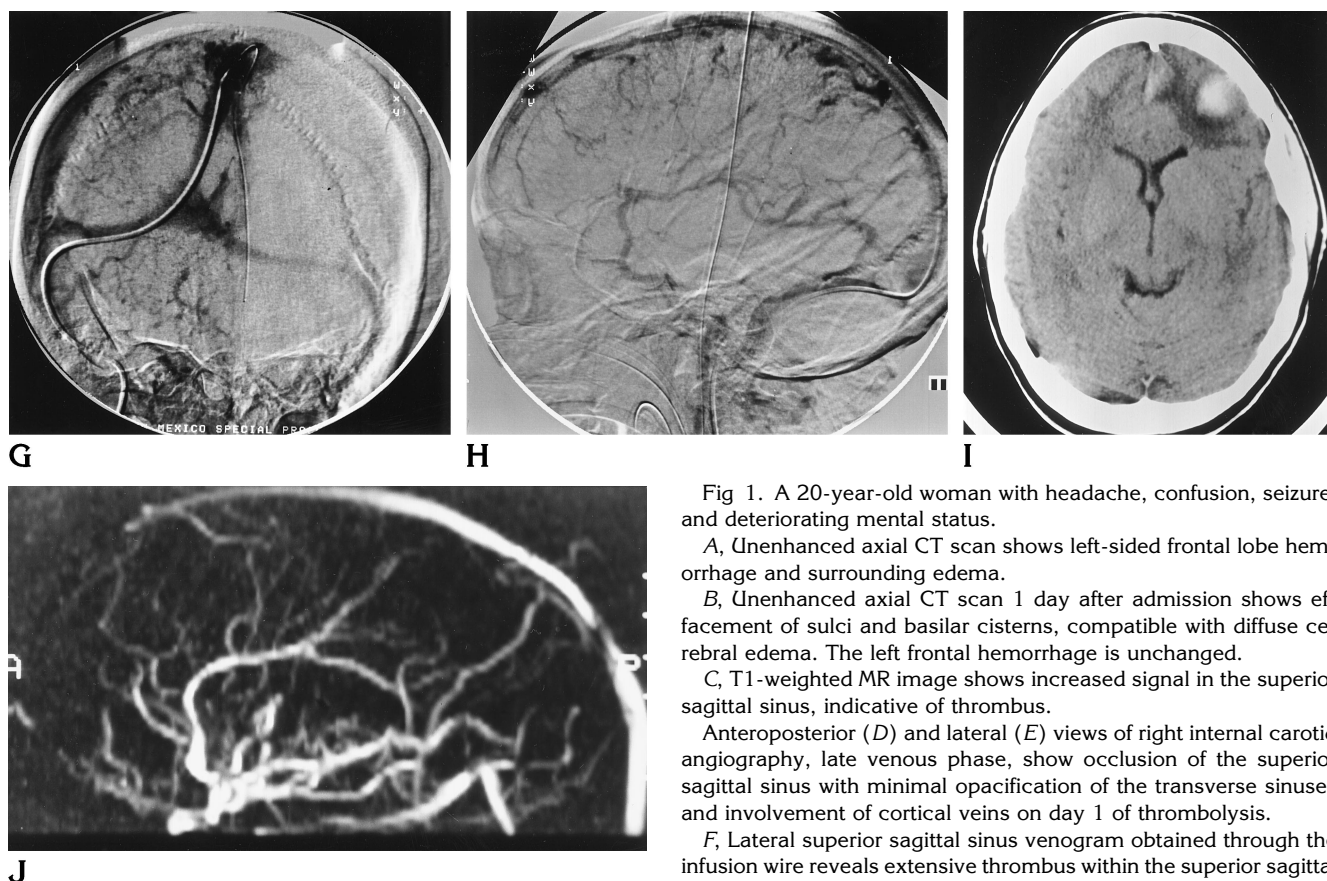


Fig 1. A 20-year-old woman with headache, confusion, seizure, and deteriorating mental status.

A, Unenhanced axial CT scan shows left-sided frontal lobe hemorrhage and surrounding edema.

B, Unenhanced axial CT scan 1 day after admission shows effacement of sulci and basilar cisterns, compatible with diffuse cerebral edema. The left frontal hemorrhage is unchanged.

C, T1-weighted MR image shows increased signal in the superior sagittal sinus, indicative of thrombus.

Anteroposterior (D) and lateral (E) views of right internal carotid angiography, late venous phase, show occlusion of the superior sagittal sinus with minimal opacification of the transverse sinuses and involvement of cortical veins on day 1 of thrombolysis.

F, Lateral superior sagittal sinus venogram obtained through the infusion wire reveals extensive thrombus within the superior sagittal sinus.

Anteroposterior (G) and lateral (H) views of right internal carotid angiography, venous phase, on last day of thrombolysis show near total lysis of the thrombus within the superior sagittal and transverse sinuses.

I, Unenhanced CT scan on last day of urokinase infusion shows evolution of left frontal hemorrhage and better delineation of surrounding edema. Increased attenuation seen in the anterior mid-falx region is thought to be bone artifact and perhaps mild residual thrombus in the anterior superior sinus.

J, MR venogram of the superior sagittal sinus shows flow signal throughout the sinus.

continued. Systemic anticoagulation was reinstated 48 hours after resolution of hemorrhage, and the patient subsequently did well.

Ideally, one would like to continue thrombolysis until the dural sinus shows a normal appearance and flow. However, since prolonged infusion increases the risk of thrombolytic-related complications, particularly catheter-related infection, it may sometimes be necessary to settle for a less than optimal result. The time of dural sinus thrombolysis varies from 88 to 244 hours, with an average time of 171 hours (3). In our case, the infusion was discontinued after 165 hours with a less than perfect-appearing superior sagittal sinus. The sinus venogram revealed brisk flow through the superior and transverse sinuses with areas of residual thrombus, which was not flow limiting. Our decision to terminate was also influenced by the patient's nearly normal mental status as well as fever,

which was presumed to be related to pulmonary atelectasis/infiltrate. Dural sinus venous pressures may provide an objective means of deciding when to discontinue thrombolytic therapy. A venous pressure of less than 17 mm Hg has been associated with an absence of parenchymal injury and clinically significant symptoms and may be an indication to terminate the infusion (7).

The use of heparin for cerebral venous thrombosis has been the subject of considerable debate. Proponents of anticoagulation believe that heparin will prevent further propagation of thrombus and allow formation of collaterals. Others believe that heparin may promote intracranial hemorrhage (1, 16). At present, it is believed that heparin is not only safe but beneficial in the treatment of symptomatic patients with cerebral venous thrombosis, even in the setting of intracerebral hemorrhage (5, 6).

Regarding postthrombolytic care, Bousser et al (1) initially used heparin for 1 to 3 months and then oral anticoagulants for another 4 to 8 months. We started Warfarin once the patient showed clinical improvement and significant lysis of the cerebral thrombus. Warfarin was then continued for 6 months and daily aspirin recommended indefinitely. Patients can then be followed up with serial MR imaging and/or MR angiography.

In conclusion, thrombosis of the dural sinuses can be life threatening as a consequence of poor cerebral venous outflow. In cases such as ours, restoration of venous outflow may be crucial for preventing such complications as increased intracranial pressure, edema, infarction, and brain herniation. While our results with this patient were dramatic, it is possible that this case represents an exception and that intradural sinus thrombolysis could potentiate additional intracranial hemorrhage and increased mortality. We expect that the criteria for treatment of symptomatic cerebral venous thrombosis will become better defined with additional experience and future research.

References

1. Bousser MG, Chiras J, Bories J, Castaigne P. Cerebral venous thrombosis: a review of 38 cases. *Stroke* 1985;16:199-212
2. Barnwell SL, Higashida RT, Halbach VV, Dowd CF, Hieshima GB. Direct endovascular thrombolytic therapy for dural sinus thrombosis. *Neurosurgery* 1991;28:135-142
3. Smith TP, Higashida RT, Barnwell SL, et al. Treatment of dural sinus thrombosis by urokinase infusion. *AJNR Am J Neuroradiol* 1994;15:801-807
4. Tsai FY, Higashida RT, Matovich V, Alfieri K. Acute thrombosis of the intracranial dural sinus: direct thrombolytic treatment. *AJNR Am J Neuroradiol* 1992;13:1137-1141
5. Higashida RT, Helmer E, Halbach VV, Hieshima GB. Direct thrombolytic therapy for superior sagittal sinus thrombosis. *AJNR Am J Neuroradiol* 1989;10(Suppl):S4-S6
6. Horowitz M, Purdy P, Unwin H, Carstens G, et al. Treatment of dural sinus thrombosis using selective catheterization and urokinase. *Ann Neurol* 1995;38:58-67
7. Tsai FY, Wang A, Matovich VB, et al. MR staging of acute dural sinus thrombosis: correlation with venous pressure measurements and implications for treatment and prognosis. *AJNR Am J Neuroradiol* 1995;16:1021-1029
8. Bookstein JJ, Valji K. Pulse-spray pharmacomechanical thrombolysis: updated clinical and laboratory observations. *Semin Interv Radiol* 1992;9:174-181
9. Bookstein JJ, Fellmeth B, Roberts A. Pulsed-spray pharmacomechanical thrombolysis: preliminary clinical results. *AJR Am J Roentgenol* 1989;152:1097-1100
10. Valji K, Roberts AC, Davis GB, Bookstein JJ. Pulsed-spray thrombolysis arterial and bypass graft occlusions. *AJR Am J Roentgenol* 1991;156:617-621
11. Marder VJ, Sherry S. Thrombolytic therapy: current status. *N Engl J Med* 1988;318:1585-1595
12. Castañeda-Zúñiga WR, Tadavarthy SM. *Interventional Radiology*. 2nd ed. Baltimore, Md: Williams & Wilkins; 1992:603
13. Marler JR, The National Institute of Neurological Disorders and Stroke rt-PA Stroke Study Group. Tissue plasminogen activator for acute ischemic stroke. *N Engl J Med* 1995;333:1581-1587
14. Hacke W, Markku K, Cesare F, et al. Intravenous thrombolysis with recombinant tissue plasminogen activator for acute hemispheric stroke. *JAMA* 1995;274:1017-1025
15. Eskridge JM, Wessbecher FW. Thrombolysis for superior sagittal sinus thrombosis. *J Vasc Interv Radiol* 1991;2:89-94
16. Estanol B, Rodriguez A, Conte G, Aleman JM, Loyo M, Pizzuto J. Intracranial venous thrombosis in young women. *Stroke* 1979;10:680-684