

Generic Contrast Agents

Our portfolio is growing to serve you better. Now you have a *choice*.



FRESENIUS
KABI

[VIEW CATALOG](#)

AJNR

Basilar artery rethrombosis: successful treatment with platelet glycoprotein IIB/IIIa receptor inhibitor.

R C Wallace, A J Furlan, D J Moliterno, G H Stevens, T J Masaryk and J Perl, 2nd

This information is current as of May 20, 2025.

AJNR Am J Neuroradiol 1997, 18 (7) 1257-1260
<http://www.ajnr.org/content/18/7/1257>

Basilar Artery Rethrombosis: Successful Treatment with Platelet Glycoprotein IIB/IIIA Receptor Inhibitor

Robert C. Wallace, Anthony J. Furlan, David J. Moliterno, Glen H. J. Stevens, Thomas J. Masaryk, and John Perl II

Summary: We describe the use of abciximab to prevent rethrombosis of the basilar artery after transluminal angioplasty. A 60-year-old patient with vertebral basilar insufficiency and acute occlusion of the basilar artery underwent revascularization with urokinase and angioplasty. Despite the repeated use of urokinase and angioplasty under anticoagulation with heparin, the basilar artery immediately rethrombosed. In a final attempt to prevent rethrombosis, abciximab was administered before the final angioplasty, resulting in a widely patent basilar artery and no rethrombosis.

Index terms: Arteries, transluminal angioplasty; Thrombosis, arterial

The immediate recanalization rate of acute basilar artery thrombosis with local intraarterial thrombolysis ranges from 44% (1) to 75% (2, 3). When basilar artery thrombosis occurs at a site of severe atherostenosis, local intraarterial thrombolysis may be combined with angioplasty (4, 5). In such cases, acute reocclusion is a major limitation, even with therapeutic anticoagulation (3). Antiplatelet therapy with ticlopidine and aspirin, combined with heparin anticoagulation, is routinely used to prevent acute thrombosis during coronary artery angioplasty and stenting. Recently, abciximab (ReoPro, Centocor, Malvern, Pa), a monoclonal antibody directed against the platelet glycoprotein IIb/IIIa receptor, has been shown to be more effective than aspirin and heparin in the prevention of acute thrombosis during coronary angioplasty (6, 7). We report the use of abciximab in a patient undergoing local intraarterial cerebral thrombolysis and angioplasty for acute basilar artery atherothrombosis.

Case Report

A 60-year-old man was admitted to a local emergency department with intermittent diplopia 3 days before trans-

fer to our institution. Findings on a noncontrast computed tomographic (CT) scan of the brain were normal, and he was discharged. He returned 24 hours later with horizontal diplopia on right lateral gaze, a partial left third nerve palsy, left-sided tinnitus, paresthesias of the left side of the face and the left arm and leg, and dysarthria. The diagnosis of posterior circulation ischemia was made, and the patient was admitted and given heparin. On the second hospital day he experienced increasing right-sided weakness, dysphagia, right-sided facial droop, and worsening dysarthria. He was transferred to our institution for examination and management of vertebrobasilar insufficiency. His stroke risk factors included a 70-pack-year smoking history and a 4-month history of hypertension. An electrocardiogram revealed a (clinically silent) remote inferior myocardial infarction.

The blood pressure was 158/96 mm Hg with a regular pulse rate of 88 beats per minute. The patient was drowsy but arousable. His speech was fluent but dysarthric. There was a right gaze palsy, coarse left beat nystagmus, skew deviation, and ocular bobbing. A right-sided central facial palsy and truncal ataxia were present.

Admission transcranial Doppler sonography revealed a basilar artery mean flow velocity of 11 cm/s (normal, 32 to 58 cm/s) with bidirectional flow and a pulsatility index of 2.1 (normal, 1.0) (8). Flow was retrograde in the distal right vertebral artery. Findings on a repeat CT scan were normal. Magnetic resonance imaging could not be performed because of a cranial metallic plate from previous surgery.

Despite aggressive medical management, including intravenous heparin anticoagulation (1800 U/h; activated partial thromboplastin time, 48 seconds) and optimization of hemodynamic parameters, the patient's symptoms continued to worsen 36 hours after admission. His level of consciousness decreased with worsening of the right-sided facial weakness, dysarthria, development of left lower extremity weakness, and a right internuclear ophthalmoplegia.

Under general anesthesia, a selective injection of the left vertebral artery showed occlusion of the basilar artery immediately distal to the vertebrobasilar junction, with

Received August 21, 1996; accepted after revision December 9.

From the Departments of Neuroradiology (R.C.W., T.J.M., J.P.), Neurology (A.J.F., G.S.), and Cardiology (D.J.M.), the Cleveland (Ohio) Clinic Foundation.

Address reprint requests to Anthony J. Furlan, MD, Department of Neurology, the Cleveland Clinic Foundation, 9500 Euclid Ave, Cleveland, OH 44195.

AJNR 18:1257-1260, Aug 1997 0195-6108/97/1807-1257 © American Society of Neuroradiology

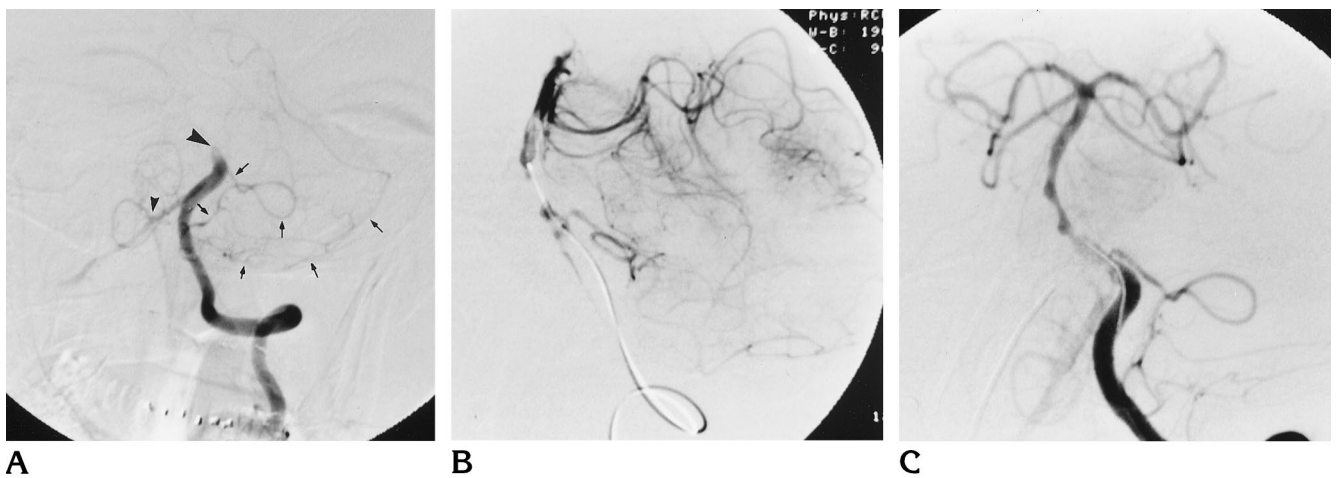


Fig 1. A 60-year-old man with vertebral artery insufficiency and acute occlusion of the basilar artery.

A, Initial diagnostic angiogram shows occlusion of the basilar artery (*large arrowhead*). A relatively large proximal left AICA branch arises just proximal to the occlusion and also supplies the left PICA territory (*arrows*). Retrograde filling of the distal right vertebral artery opacifies the right PICA (*small arrowhead*). The right vertebral artery is occluded proximally.

B, After 1 hour and 500 000 U of urokinase, the guidewire and microcatheter could be manipulated through the occluded segment. With the microcatheter spanning the high-grade stenosis, selective angiography through the microcatheter opacifies the distal basilar artery territory.

C, Representative angiographic appearance of the basilar artery after angioplasty with a 2-mm-diameter angioplasty balloon.

D, Angiographic appearance (anteroposterior projection) immediately after final angioplasty with patient on abciximab.

E, Angiogram (lateral projection) 15 minutes after the final angioplasty (3-mm balloon).

retrograde flow in the distal right vertebral artery (Fig 1A). The proximal right vertebral artery was occluded. There was minimal collateral flow to the distal basilar artery through a small left posterior communicating artery with the left carotid injection.

A coaxial catheter system consisting of a 6F guiding catheter, a microcatheter (Rapid Transit, Cordis Endovascular Systems, Miami Lakes, Fla), and a 0.016-inch microguidewire (Terumo Glidewire Gold, Meditech, Watertown, Mass) were advanced to the site of the basilar artery occlusion. Anticoagulation was continued with intravenous heparin (1800 U/h) while the activated clotting time was maintained at 220 seconds or greater. An unsuccessful attempt was made to manipulate the microguidewire through the occlusion. With the microcatheter tip placed at the "face" of the occlusion, 500 000 U of urokinase were continuously administered over an hour. Angiography was performed after 30 minutes of infusion, and the catheter tip was advanced further into the thrombus. The initial 500 000 U of urokinase produced only minimal change in

the appearance of the occlusion. Further manipulation allowed passage of the 0.016-inch guidewire and the microcatheter through the occlusion site (Fig 1B). With the microcatheter tip within the occlusion site, an additional 200 000 U of urokinase was infused over 30 minutes, with only minimal improvement in patency. Control angiography through the guide catheter in the proximal left vertebral artery did not opacify the basilar artery, indicating the severity of stenosis.

Angioplasty was then performed twice with a 2.0-mm-diameter single-lumen angioplasty balloon and a 2-cm tip length occlusive wire (Fasstealth, Target Therapeutics, Fremont, Calif). A control angiogram showed patency of the lumen with moderate residual stenosis (Fig 1C), which subsequently occluded completely at the site of the original lesion. The microcatheter was advanced through the occlusion and another 100 000 U of urokinase were infused over 30 minutes, which restored patency of the vessel but reoccluded after 2 minutes. A third angioplasty was performed with a 3-mm-diameter balloon, resulting in

a mild residual stenosis; however, the artery reoccluded for the fourth time.

An infusion catheter with side holes (Soft-stream, Target Therapeutics) was then advanced through the thrombosed segment with the side holes centered at the obstructing site, and treatment with systemic abciximab was initiated. To reduce the risk of brain hemorrhage, urokinase was stopped and heparin was reversed. When the activated clotting time was less than 160 seconds, a 0.25 mg/kg bolus of abciximab was given intravenously over 2 minutes, followed by a 0.125 mcg/kg per minute filtered intravenous infusion, which was continued for 12 hours. Five minutes after the abciximab bolus was administered, repeat angioplasty was performed with a 3-mm-diameter balloon inflated to 6 atm. Angiography revealed a patent basilar artery lumen, and 15 minutes later the vessel remained patent with antegrade flow (Fig 1D and E). The basilar artery mean velocity by sonography was antegrade at 18 cm/s with a pulsatility index of 1.5.

Following the procedure, low-molecular-weight heparin was started (heparin antibodies were detected) with subsequent conversion to warfarin (international normalization ratio of 2.4). During follow-up over the next 20 days, sonography revealed antegrade flow in the basilar artery (velocity, 25 cm/s; pulsatility index, 1.14), indicating continued patency, and CT scans showed a focal right pontine infarction but no hemorrhage. The patient continued to improve over the subsequent weeks and was able to stand at the time of discharge to a rehabilitation hospital. At follow-up 6 weeks after discharge, the patient was at home, ambulatory with a walker, and requiring some assistance with activities of daily living.

Discussion

After four successive acute reocclusions on intravenous heparin, recanalization of a symptomatic basilar artery atherothrombosis was achieved and maintained by using abciximab. No hemorrhagic complications occurred, and the patient did well clinically.

Abciximab has been approved by the Food and Drug Administration only for coronary indications. In coronary angioplasty, platelet aggregation plays a pivotal role in abrupt vessel closure after intervention. This occurs in 4% to 9% of procedures, despite the concomitant use of heparin and aspirin. Acute thrombotic vessel closure is probably related to heightened platelet activity. Regardless of the stimulus, the final common pathway for platelet aggregation involves the surface glycoprotein IIb/IIIa receptors (9, 10). Each platelet contains approximately 50 000 IIb/IIIa receptors, which are expressed and become competent when the platelet is activated. Receptors on activated platelets couple with adjacent platelet IIb/IIIa receptors by an

interposed fibrinogen molecule. Unlike aspirin, which blocks only the arachidonic acid-thromboxane pathway of platelet activity, or ticlopidine, which may interfere with the platelet fibrinogen receptor, IIb/IIIa receptor antagonists markedly inhibit platelet aggregation regardless of pathway or stimulus. Abciximab is a chimeric antibody to the human platelet IIb/IIIa receptor. Within minutes of intravenous administration of abciximab, platelet aggregation, measured in response to adenosine diphosphate, is inhibited by 80% to 90%. A weight-dependent bolus and 12-hour infusion of abciximab inhibits platelet aggregation by more than 50% for approximately 48 hours after cessation of infusion.

Vessel wall injury from atherosclerotic plaque rupture exposes to the circulation the subendothelial matrix, lipid peroxides, and collagen. These substrates are potent stimuli for platelet adhesion (platelet-endothelial cell binding), platelet aggregation (platelet-platelet binding), and activation of the coagulation cascade. In a similar fashion, angioplasty iatrogenically produces plaque wall disruption and can result in local vascular thrombosis. Key components for coagulation are thrombin, which converts fibrinogen to fibrin, and platelets, which form the cellular plug within the fibrin mesh and release additional vasoactive substances. Thrombin is among the most potent activators of platelets, whereas activated platelets provide a lipid-rich surface that accelerates the generation of thrombin from prothrombin. This synergism suggests that the prevention of acute thrombosis during angioplasty and some ischemic syndromes may require antithrombin and antiplatelet agents.

The first large-scale study of abciximab, then referred to as c7E3, was the Evaluation of c7E3 to Prevent Ischemic Complications (EPIC) trial in high-risk coronary angioplasty (6). In this trial, patients receiving abciximab bolus plus infusion in addition to aspirin and standard-dose heparin had a 38% reduction in 30-day myocardial ischemic events, death, myocardial infarction, or emergent myocardial revascularization compared with those receiving aspirin and heparin only. In the EPIC trial, major peripheral bleeding complications, since determined to be due mainly to excess concomitant heparin use, were higher among those receiving abciximab. However, the risk of brain hemorrhage was not increased. Bleeding complications were re-

duced by using low-dose, weight-adjusted heparin (11).

Although angioplasty, stenting, and thrombolysis of the cerebral circulation are being attempted with increasing frequency, antithrombotic and antiplatelet regimens have not been standardized. The safety and efficacy of antithrombotic therapy during cerebrovascular interventions may depend on the clinical presentation, lesion characteristics, and therapeutic protocols. Although residual stenosis is common after intraarterial thrombolysis and intracranial angioplasty, the frequency of acute reocclusion and restenosis is unclear. Higashida et al (12) reported acute rethrombosis in three of nine patients with residual stenosis after middle cerebral artery thrombolysis.

The risk of brain hemorrhage complicating thrombolysis may be higher in patients with acute stroke or neuroimaging evidence of ischemia than in patients with transient ischemic attacks or incomplete infarction (13). Standard-dose intravenous heparin is usually given during neurointerventional procedures, but is contraindicated for 24 hours after intravenous thrombolysis. There is some evidence that high-dose heparin increases the risk of brain hemorrhage during intraarterial thrombolysis in patients with acute stroke (14). For high-risk cerebrovascular lesions, such as basilar artery atherothrombosis, our initial experience suggests that antiplatelet IIb/IIIa agents can significantly reduce acute reocclusion rates during neurointerventional procedures.

References

1. Hacke W, Zeumer H, Ferbert A, Bruckmann H, del Zoppo GJ. Intra-arterial thrombolytic therapy improves outcome in patients with acute vertebrobasilar occlusive disease. *Stroke* 1988;19:1216-1222
2. Zeumer H, Freitag HJ, Zanella F, Thie A, Arning C. Local intra-arterial fibrinolytic therapy in patients with stroke: urokinase versus recombinant tissue plasminogen activator. *Neuroradiology* 1993;35:159-162
3. Becker KJ, Monsein LH, Mirski M, Williams M, Hanley DF. Intra-arterial thrombolysis in vertebrobasilar occlusion. *AJNR Am J Neuroradiol* 1996;17:255-262
4. McKenzie JD, Wallace RC, Dean BL, Flom RA, Khayata MH. Preliminary results of intracranial angioplasty for vascular stenosis caused by atherosclerosis and vasculitis. *AJNR Am J Neuroradiol* 1996;17:263-268
5. Higashida RT, Tsai FY, Halbach VV, et al. Transluminal angioplasty for atherosclerotic disease of the vertebral and basilar arteries. *J Neurosurg* 1993;78:192-198
6. The EPIC Investigators. Use of a monoclonal antibody directed against the platelet glycoprotein IIb/IIIa receptor in high-risk coronary angioplasty. *N Engl J Med* 1994;330:956-961
7. Shomig A, Neumann F-J, Kastrati A, et al. A randomized comparison of antiplatelet and anticoagulant therapy after the placement of coronary-artery stents. *N Engl J Med* 1996;334:1084-1089
8. Adams RJ, Nichols FT, Hess DC. Normal values and physiological variables. In: Newell DW, Aaslid R, eds. *Transcranial Doppler*. New York, NY: Raven Press; 1992:41-48
9. Collier BS. Blockade of platelet GPIIb/IIIa receptors as an anti-thrombotic strategy. *Circulation* 1995;92:2373-2380
10. Lefkovits J, Plow EF, Topol EJ. Platelet glycoprotein IIb/IIIa receptors in cardiovascular medicine. *N Engl J Med* 1995;332:1553-1559
11. Aguirre F, Ferguson JJ, Califf, et al. Clinical predictors of bleeding complications in high risk angioplasty: results from the EPIC study group. *Circulation* 1993;90:I-252
12. Higashida RT, Halbach VV, Tsai FY, Dowd CF, Hieshima GB. Interventional neurovascular techniques in acute thrombolytic therapy for stroke. In: Yamaguchi T, Mori E, Minematsu K, del Zoppo GJ, eds. *Thrombolytic Therapy in Acute Ischemic Stroke, III*. Tokyo, Japan: Springer-Verlag; 1995;99:294-300
13. Hacke W, Kaste M, Fieschi C, for the ECASS Study Group. Intravenous thrombolysis with recombinant tissue plasminogen activator for acute hemispheric stroke. *JAMA* 1995;274:1017-1026
14. del Zoppo GJ, Higashida RT, Furlan AJ, et al. The prolyse in acute cerebral thromboembolism trial (PROACT): results of the 6 mg dose tier. *Stroke* 1996;27:164