

Generic Contrast Agents

Our portfolio is growing to serve you better. Now you have a *choice*.



[VIEW CATALOG](#)

AJNR

Serial MR in gene therapy for recurrent glioblastoma: initial experience and work in progress.

A V Deliganis, A B Baxter, M S Berger, S G Marcus and K R Maravilla

This information is current as of May 19, 2025.

AJNR Am J Neuroradiol 1997, 18 (8) 1401-1406
<http://www.ajnr.org/content/18/8/1401>

Serial MR in Gene Therapy for Recurrent Glioblastoma: Initial Experience and Work in Progress

Anastasia V. Deliganis, Alexander B. Baxter, Mitchel S. Berger, Stephen G. Marcus, and Kenneth R. Maravilla

PURPOSE: To describe the MR imaging findings in a pilot study evaluating gene therapy for treatment of patients with recurrent glioblastoma. **METHODS:** Serial MR examinations were evaluated retrospectively in patients treated with gene therapy that included a retroviral vector containing the herpes simplex virus thymidine kinase gene and intravenous ganciclovir. Images were obtained after tumor resection and after each cycle of treatment, at approximately 40-day intervals. The volume of enhancing tissue was measured on serial MR images. **RESULTS:** Eleven patients with recurrent glioblastoma were entered into the clinical trial of gene therapy and seven patients completed at least two cycles of treatment. Of these seven, three patients had an early (between 40 and 80 days) increase in the volume of enhancing tissue followed by a decrease or plateau in enhancing tissue volume. A fourth patient had a stable volume of enhancing tissue for 132 days. The remaining three patients had continuous increases in volume of enhancement on all subsequent MR examinations. **CONCLUSION:** Although animal data show striking tumor regression in response to similar gene therapy, only limited regression was observed among the seven patients we studied. The transient increases in enhancement seen in three of seven patients might reflect an inflammatory response to local injection of the viral vector.

Index terms: Brain neoplasms, magnetic resonance; Drugs, effects; Glioblastoma multiforme

AJNR Am J Neuroradiol 18:1401-1406, September 1997

Glioblastoma multiforme is the most common primary brain tumor in adults. Despite technical improvements in surgery, radiation therapy, and chemotherapy, the outcome for patients with glioblastoma remains poor, with a median survival of 8 to 12 months (1). Therapeutic approaches for brain neoplasms based on the genetic transformation of tumor cells have shown promising results in animal studies. Gene therapy is currently undergoing human phase I/II clinical trials in a multicenter study (2, 3).

In the gene therapy protocol used in the current study, a producer cell was genetically engineered to generate and release retroviral vector containing the herpes simplex virus thymidine kinase gene (Fig 1). After gross surgical resection, vector-producing cells containing the thymidine kinase gene were injected directly into the tumor bed. Because retroviral vectors integrate and express their genes only in proliferating cells, dividing tumor cells incorporate the thymidine kinase gene while mature, nondividing neurons are unaffected. Transformed tumor cells express the thymidine kinase gene and produce the enzyme thymidine kinase, which has a high affinity for the antiviral drug ganciclovir. Thymidine kinase phosphorylates ganciclovir to toxic metabolites that inhibit DNA polymerase, leading to cell death.

Results of animal studies using this method of gene therapy are promising (4-6). In 24 rats with implanted glioblastoma treated with gene therapy, Izquierdo et al (4) demonstrated tumor regression in all animals, with relapse-free survival of up to 8 months. Ram et al (5) reported

Received November 22, 1996; accepted after revision March 7, 1997.
Supported in part by Genetic Therapy Inc, Gaithersburg, Md.

Presented in part at the annual meeting of the American Society of Neuroradiology, Seattle, Wash, June 1996.

From the Departments of Radiology (A.V.D., A.B.B., K.R.M.) and Neurological Surgery (M.S.B.), University of Washington School of Medicine, Seattle, and Genetic Therapy Inc, Gaithersburg, Md (S.G.M.).

Address reprint requests to K. Maravilla, MD, Department of Radiology, Box 357115, University of Washington, Seattle, WA 98195.

AJNR 18:1401-1406, Sep 1997 0195-6108/97/1808-1401

© American Society of Neuroradiology

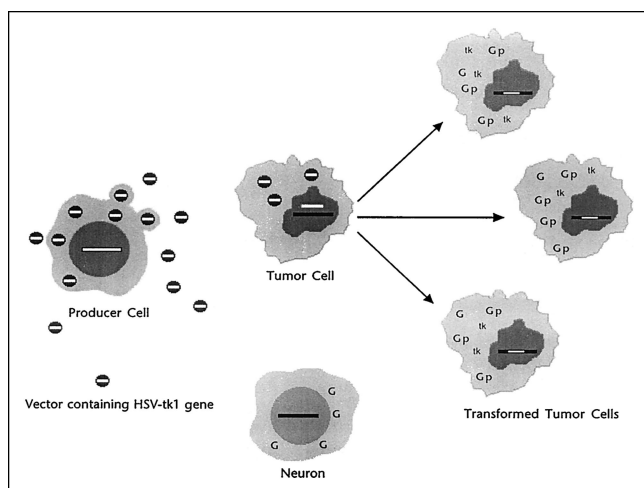


Fig 1. Diagram shows method of retrovirus-mediated transduction of tumor cells with the herpes simplex thymidine kinase (*HSV-tk1*) gene. Producer cell generates retroviral vector containing the gene for thymidine kinase (*small white bar*). When injected into tumor cells, retroviral vector DNA is incorporated during cell division into tumor cell DNA, inducing production of the enzyme thymidine kinase (*tk*). Thymidine kinase catalyzes the phosphorylation of ganciclovir (*G*) to a phosphorylated derivative (*Gp*), a toxic metabolite, leading to cell death. Nondividing neurons do not incorporate the thymidine kinase gene, and are therefore unaffected by ganciclovir.

complete regression of tumors in 23 of 30 rats treated with gene therapy and ganciclovir. In a study including histologic examination, Culver et al (6) described complete macroscopic and microscopic tumor regression in 11 of 14 rats with gliomas treated with gene therapy. Animal studies of gene therapy in a rat tumor model have shown reproducible imaging changes corresponding to tumor regression (4). Our purpose is to describe the serial magnetic resonance (MR) imaging findings in a pilot study of patients undergoing gene therapy for recurrent glioblastoma and to evaluate this patient group for evidence of treatment response.

Materials and Methods

This study was part of a multicenter phase I/II clinical trial (2). After receiving a careful explanation of the study, all patients signed a written consent form approved by the human subjects review committee at our institution. Criteria for entry into the protocol included adult patients with recurrent glioblastoma who had received primary surgical treatment and had completed radiation treatment at least 12 weeks earlier. All patients had evidence of progressive disease while on a stable or increasing dose of steroids. Patients with tumors involving the brain stem, basal ganglia, or both hemispheres, or who had multifocal disease or diffuse subependymal spread, were excluded.

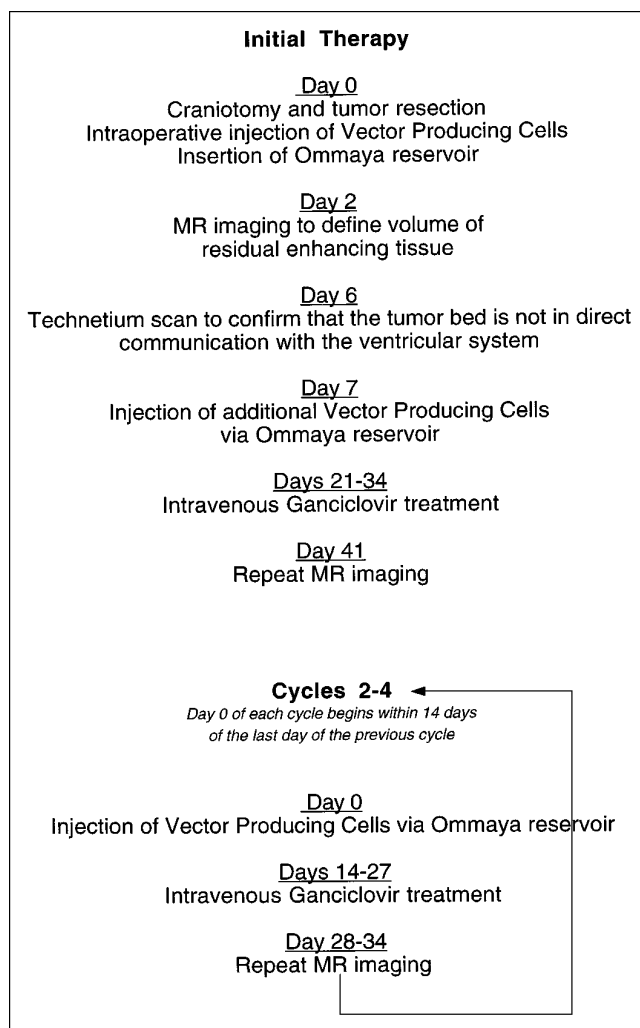


Fig 2. Gene therapy protocol.

Each enrolled patient underwent craniotomy with subtotal or gross total resection of tumor followed by direct injection of retroviral vector-producing cells (cell line PA317-G1Tk1SvNa.7, $1-2 \times 10^8$ cells per milliliter suspended in Plasma Lyte A [Genetic Therapy Inc, Gaithersburg, Md]; maximum volume, 10 mL) into the margins of the surgical cavity. An Ommaya reservoir (Medtronic PS Medical, Goleta, Calif) was placed in the cavity for subsequent administration of vector-producing cells. On the second postoperative day, an MR examination was performed to define the size of any residual enhancing tissue, presumed to represent tumor. On the sixth postoperative day, technetium was injected into the Ommaya reservoir to exclude communication between the surgical cavity and the ventricular system, which would contraindicate further vector cell injections (see below and Fig 2).

Additional vector-producing cells were injected via the Ommaya reservoir on postoperative day 7 ($1-2 \times 10^8$ cells per milliliter suspended in Plasma Lyte A, up to 10 mL). On postoperative day 21, patients received daily intravenous ganciclovir (5 mg/kg twice a day; Syntex Corp, Palo Alto, Calif) for the next 14 days, followed by MR

examination thereafter. Each subsequent cycle was begun within 14 days of the last MR examination and consisted of reinjection of vector-producing cells followed by repeat intravenous ganciclovir on days 14 through 27 and MR examination on day 28.

Each patient received up to four cycles of vector and ganciclovir, depending on tumor response and clinical status. Three patients completed four cycles of treatment, one patient completed three cycles, three patients completed two cycles, and three patients completed one cycle. One patient did not complete the initial cycle of treatment, owing to death caused by a pulmonary thromboembolism. Reasons for discontinuing the protocol included indication of communication between the tumor cavity and the ventricular system or subarachnoid space, evidence of neurologic toxicity, and voluntary withdrawal. Postoperative steroid treatment was left to the investigator's medical judgment and varied depending on the patient's clinical status. After surgery, doses were tapered on the basis of clinical condition in order to wean the patient off steroid treatment. Only in cases of worsening mass effect and/or worsening clinical symptoms were steroid doses increased. In patients in whom there was improvement, steroid doses were tapered or discontinued. In no patients in whom improvement was seen were steroid doses increased.

MR imaging consisted of an unenhanced sagittal T1-weighted localizing sequence, axial T1-weighted (500/11/1 [repetition time/echo time/excitations]) and T2-weighted (2500/17,102/1) sequences, and axial and coronal T1-weighted (500/11/1) sequences obtained after intravenous administration of gadopentetate dimeglumine (0.1 mm/kg). All images were acquired with 5-mm-thick contiguous sections and a 256 × 256 matrix.

One observer measured the serial axial and coronal postcontrast T1-weighted MR studies in all patients to determine the area of enhancement surrounding the resection cavity on each image. Enhancing tissue was outlined by using a manual trace software program on an independent console. The surgical resection cavity itself was excluded from area measurements, although nonenhancing areas surrounded by enhancement were included and presumed to represent necrotic or nonenhancing portions of tumor. The total volume of enhancement was determined from the sum of the area measurements of all sections according to the following formula:

$$\text{Vol (cm}^3\text{)} = [\text{Area/image (mm}^2\text{)}] \times \text{section thickness (mm)/1000}$$

Results

Eleven patients were enrolled in the clinical trial at our institution from October 1994 through January 1996. Serial MR images for seven patients who completed at least two cycles of gene therapy were evaluated for volume of enhancing tissue (Fig 3). Four patients did

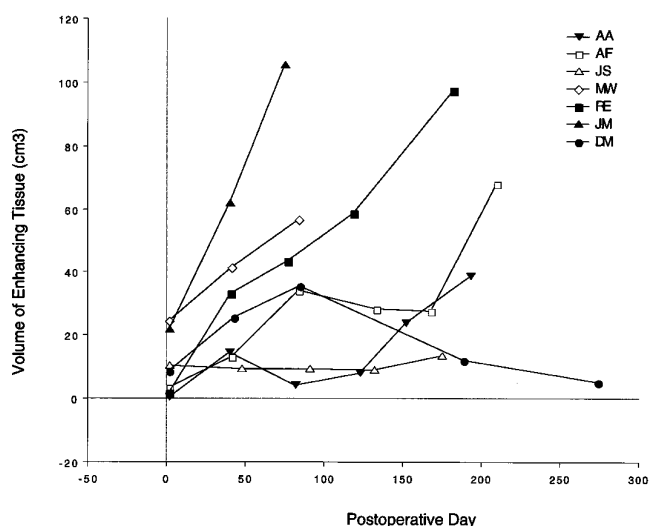


Fig 3. Volume of enhancing tissue (cm³) versus time (days) for seven patients. MR examination was performed 2 days after surgery and at approximately 40-day intervals thereafter during treatment.

not complete more than one gene therapy cycle and were excluded from the data analysis. Patient characteristics and outcomes are summarized in the Table. At surgery, all patients had evidence of recurrent glioblastoma multiforme based on histopathologic evaluation. At the time of data analysis, three patients were living (average postoperative survival, 326 days) and eight had died (average postoperative survival, 199 days). Seven deaths were due to progressive disease and one death was due to pulmonary thromboembolism. Among the patients excluded from eventual data analysis, initial postoperative MR images showed gross tumor resection, and subsequent images showed increasing volume of enhancing tissue, consistent with tumor progression.

The seven patients who completed at least two cycles of gene therapy were followed up for 83 to 588 days (average, 278 days). Four patients had residual enhancing tissue after surgical resection of 10 cm³ or less, one had a residual volume of 10 to 20 cm³, and the remaining two patients had residual volumes of 20 cm³ or greater.

In one patient (case 7), a transient increase in amount of tissue enhancement was followed by a sustained decrease in enhancement and was accompanied by a significant decline in mass effect and edema (Fig 4). Two patients (cases 2 and 4) had an early increase in the volume of enhancing tissue (approximately 80 days after treatment) followed by a transient plateau (case

Data for all patients undergoing gene therapy

Case	Age, y/Sex	No. of Cycles	Outcome
1 (RE)	39/M	4	Death on postoperative day 197 due to tumor progression
2 (AF)	71/M	4	Death on postoperative day 298 due to tumor progression
3 (JS)	50/M	4	Death on postoperative day 342; withdrawn from study because of communication between surgical cavity and ventricles
4 (AA)	25/M	3	Alive as of postoperative day 588; withdrawn from study because of communication between surgical cavity and ventricles
5 (MW)	64/F	2	Death on postoperative day 83 due to tumor progression
6 (JM)	54/M	2	Alive as of postoperative day 201; withdrawn from study because of communication between surgical cavity and ventricles
7 (DM)	45/M	2	Alive as of postoperative day 189; voluntary withdrawal from study
8 (GS)	46/M	1	Death on postoperative day 389; voluntary withdrawal from study
9 (DC)	53/F	1	Death on postoperative day 212; voluntary withdrawal from study
10 (SG)	46/M	1	Death on postoperative day 65 due to tumor progression
11 (LH)	71/F	<1	Death on postoperative day 3 due to pulmonary thromboembolism

2) or transient decrease (case 4) in the volume of enhancement. In another patient (case 3), the volume of enhancing tissue was stable for 132 days before showing a progressive increase. The remaining three patients (cases 1, 5, and 6) showed serial increases in volume of enhancing tissue, edema, and mass effect, consistent with tumor progression from the first postoperative MR examination onward (see Fig 5; case 1).

Discussion

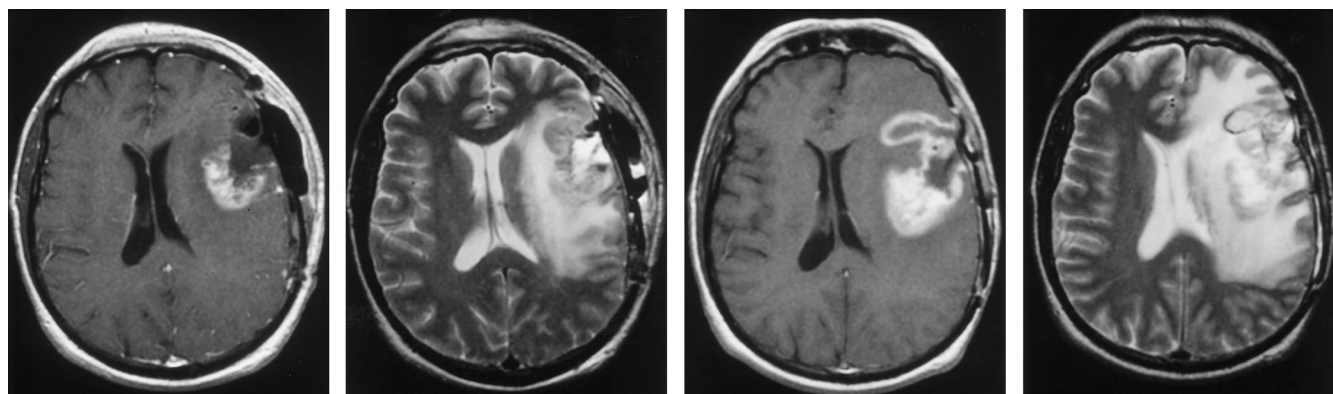
Gene therapy, as applied to the treatment of brain tumors in animal models, is an innovative strategy for selectively killing neoplastic cells in a background of nondividing neurons (7). Injected retroviral vectors transform dividing tumor cells and enable them to produce the enzyme thymidine kinase. Thymidine kinase converts the antiviral agent ganciclovir into phosphorylated derivatives that disrupt neo-

plastic cell division, leading to tumor cell death. Killing of adjacent nontransformed tumor cells has been observed and may be due to intercellular transfer of toxic ganciclovir metabolites via gap junctions (8). Human clinical trials of gene therapy can be justified on the basis of the theoretical mechanism of selective transfer of suicide genes into dividing neoplastic cells, promising animal studies, and the uniformly dismal prognosis of glioblastomas.

In our study, sustained tissue enhancement consistent with tumor progression was ultimately demonstrated in six of seven patients by 210 days. In the one patient with persistent decrease in tissue enhancement, the chronology of tissue enhancement may offer important clues for understanding the natural course of treatment with gene therapy. In three of the seven patients studied, a transient increase in the volume of enhancing tissue was seen between approximately 40 and 80 days after surgery. Over the next 80 days, the volume of enhancing tissue either decreased or remained unchanged, followed by progressive increases in enhancing volume in two of these three patients. In unpublished observations from initial phase I human clinical trials (Genetic Therapy Inc, December 1994), transient increases in volume of tissue enhancement were observed early in the course of gene therapy treatment. More recently, in a study of intralesional immunotherapy for recurrent high-grade astrocytomas, Smith et al (9) showed transient increases in enhancement and edema (termed a flare phenomenon) during therapy with tumor-infiltrating lymphocytes and interleukin 2.

In the patients we studied in whom transient enhancement was seen, local inflammatory changes related to the injection of vector-producer cells may be responsible. Proof of this hypothesis would require obtaining a biopsy sample to distinguish inflammation from residual tumor, which was not done in this study. Later progressive enhancement most likely represents superimposed continuing tumor growth.

The extent of surgical resection most likely influences the rate of observable tumor regrowth, as evidenced by increases in enhancing tissue at the margins of the resection cavity. Postoperative MR imaging has been shown to accurately reflect residual tumor in patients imaged within 3 days of surgery (10). The analysis of tumor measurements in the current study suggested a relationship between the extent of

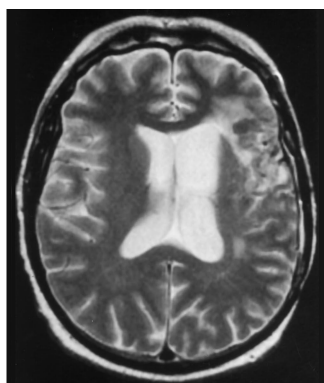
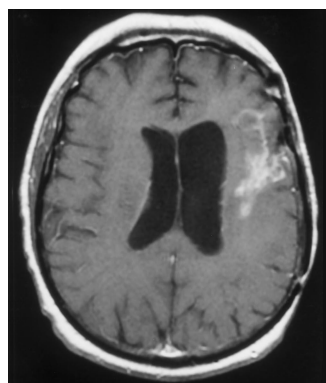


A

B

C

D



E

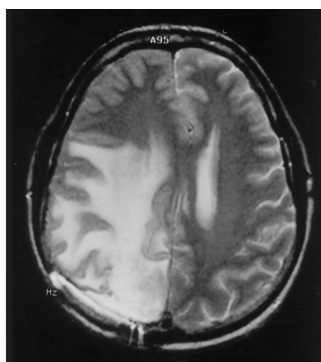
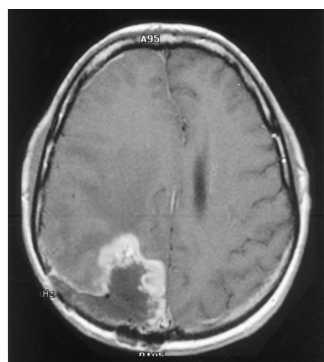
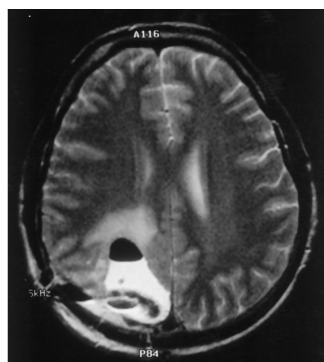
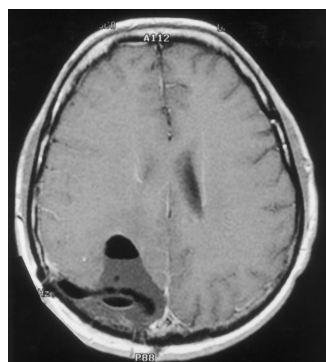
F

Fig 4. Case 7: Serial axial contrast-enhanced T1- and T2-weighted MR images after tumor resection and treatment with gene therapy.

A and B, Initial postoperative images obtained 2 days after resection.

C and D, Eighty days after resection, images show a transient increase in volume of tissue enhancement and edema.

E and F, Two hundred eighty days after resection, images show a sustained decrease in size, enhancement, and mass effect of the lesion.

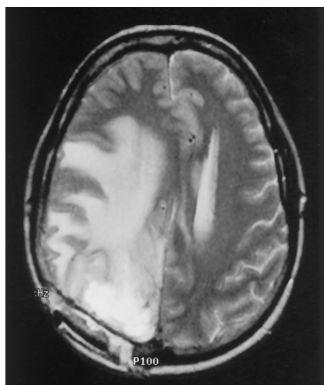
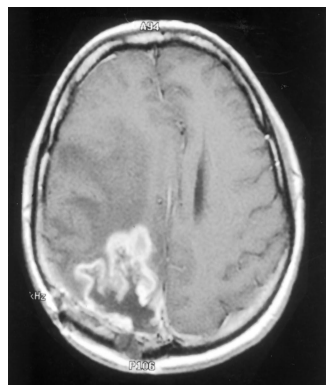


A

B

C

D



E

F

Fig 5. Case 1: Serial axial contrast-enhanced T1- and T2-weighted images after tumor resection and treatment with gene therapy.

A and B, Initial postoperative images obtained 2 days after resection.

C and D, Eighty days after resection, images show an increase in volume of tissue enhancement and edema.

E and F, One hundred eighty days after resection, images show a sustained increase in size, enhancement, and mass effect of the lesion.

surgical resection and the time to apparent tumor progression. Two patients with enhancing tissue volumes greater than 20 cm³ on the first postoperative examination (before gene therapy) showed progressive increases in enhancing tissue volume on all subsequent images. Three of four patients with postoperative enhancing tissue volumes less than 10 cm³ and the single patient with a volume between 10 and 20 cm³ showed prolonged (more than 120 days) stability or decreases of enhancing tissue volume, potentially indicating a response to treatment.

Several studies have shown the importance of the extent of resection in tumor regrowth and outcome. In a study of extent of resection on recurrence in patients with low-grade gliomas, patients with a volume of residual disease of greater than 10 cm³ had a higher frequency of recurrence and a shorter time to tumor progression than those with less than 10 cm³ in residual volume (11). In patients with high-grade gliomas and glioblastomas, gross total tumor resection as determined by MR imaging correlates with significant increases in survival (10, 12, 13).

The disparity between our results and the conclusions derived from published animal studies may be due to several factors. Significant differences exist between the experimental animal models and the clinical protocol, which was designed primarily to evaluate toxicity rather than efficacy. In the animal studies, experimental tumors were created by implanting tumors derived from several cell lines (rat C6 glioblastoma, rat 9L gliosarcoma), which may not be identical to human glioblastoma. Also, implanted tumors are likely to behave differently biologically from de novo glioblastoma, in effect acting more like localized metastases rather than primary infiltrating neoplasms. Success in the animal studies might have been attributable to the implanted tumors being more focal and accessible to the therapy than the treated, recurrent glioblastomas in the current study, which most likely had diffused throughout adjacent brain. Finally, differences in the amount of distribution of the genetic vector from producer cells into the tumor may vary between animal and human cells. In situ hybridization, which was not available in the current study, would be useful for determining whether a difference exists between the transfer of vector to human versus animal tumor cells.

Our initial observations showed a limited response to gene therapy in three of seven patients with recurrent glioblastomas. Early in treatment, increases in volume of enhancement might be due to transient inflammatory reaction or to actual tumor growth, rendering serial MR imaging indispensable. Since the present study protocol focused primarily on toxicity, larger studies evaluating the clinical outcome of patients treated with gene therapy will be necessary to determine fully gene therapy's potential efficacy.

References

1. Walker MD, Green, SB, Byar DP, et al. Randomized comparisons of radiotherapy and nitrosoureas for the treatment of malignant glioma after surgery. *N Engl J Med* 1980;303:1323-1329
2. Berger MS, Prados M, Van Gilder J. *Gene Therapy for the Treatment of Recurrent Glioblastoma Multiforme with In Vivo Tumor Transduction with the Herpes Simplex Thymidine Kinase Gene/Ganciclovir System: A Phase I/II Study*. Gaithersburg, Md: Genetic Therapy Inc; December 22, 1994, Version 3.0
3. Kun LE, Gajar A, Muhlbauer M, et al. Clinical protocol: stereotactic injection of herpes simplex thymidine kinase vector producer cells (PA317-G1Tk1SvNa.7) and intravenous ganciclovir for the treatment of progressive or recurrent primary supratentorial pediatric malignant brain tumors. *Hum Gene Ther* 1995; 6:1231-1255
4. Izquierdo M, Cortes M, deFelipe P, et al. Long-term rat survival after malignant brain tumor regression by retroviral gene therapy. *Gene Ther* 1995;2:66-69
5. Ram Z, Culver KW, Walbridge S, et al. In situ retroviral-mediated gene transfer for the treatment of brain tumors in rats. *Cancer Res* 1993;53:83-88
6. Culver KW, Ram Z, Walbridge S, et al. In vivo gene transfer with retroviral vector-producer cells for treatment of experimental brain tumors. *Science* 1992;256:1550-1552
7. Fine HA. Novel biologic therapies for malignant gliomas. *Neurol Clin* 1995;13:827-844
8. Wu KJ, Cano WG, Meylaerts SAG, et al. Bystander tumoricidal effect in the treatment of experimental brain tumors. *Neurosurgery* 1994;35:1094-1103
9. Smith MM, Thompson JE, Castillo M, et al. MR of recurrent high-grade astrocytomas after intralesional immunotherapy. *AJNR Am J Neuroradiol* 1996;17:1065-1071
10. Albert FK, Forsting M, Sartor K, et al. Early postoperative magnetic resonance imaging after resection of malignant glioma: objective evaluation of residual tumor and its influence on regrowth and prognosis. *Neurosurgery* 1994;34:45-61
11. Berger MS, Deliganis AV, Dobbins J, et al. The effect of extent of resection on recurrence in patients with low grade cerebral hemisphere gliomas. *Cancer* 1994;74:1784-1791
12. Nitta T, Sato K. Prognostic implications of the extent of surgical resection in patients with intracranial malignant gliomas. *Cancer* 1995;75:2727-2731
13. Forsting M, Albert FK, Kunze S, et al. Extirpation of glioblastomas: MR and CT follow-up of residual tumor and regrowth patterns. *AJNR Am J Neuroradiol* 1993;14:77-87