



## Discover Generics

Cost-Effective CT & MRI Contrast Agents



WATCH VIDEO

# AJNR

### **Embolization of an orbital varix after surgical exposure.**

A Weill, C Cognard, L Castaings, G Robert and J Moret

*AJNR Am J Neuroradiol* 1998, 19 (5) 921-923

<http://www.ajnr.org/content/19/5/921>

This information is current as  
of June 5, 2025.

## Embolization of an Orbital Varix after Surgical Exposure

Alain Weill, Christophe Cognard, Lina Castaings, Gilles Robert, and Jacques Moret

**Summary:** We report a case of primary orbital varix treated by embolization with coils after surgical exposure and puncture of the venous ectasia. This method of treatment has the advantage of limiting traumatic dissection and avoiding difficult venous catheterization.

Orbital varix is an intraorbital mass composed of abnormally large veins. It may be a single vessel with saccular or segmental dilatations or a tangled plexus of venous channels (1). Lloyd et al (2) differentiated primary and secondary varices. A secondary varix is acquired and may be caused by orbital trauma or related to a change in hemodynamics of the orbit induced by extraorbital lesions, such as carotid-cavernous fistula, dural fistula, brain arteriovenous malformation, or intracranial dural sinus occlusion. In fact, like Henderson (1), we believe that these secondary types should not be called varix but rather should be designated according to the primary lesion with which they are associated. A primary orbital varix, or more simply orbital varix, as previously stated, is a congenital venous malformation. It is manifest in infancy but its appearance may be delayed until the early part of the second decade (1). A transient and evanescent exophthalmos induced by Valsalva maneuver is the principal clinical sign, as orbital varices are usually in direct communication with the native venous system (3). There are only two indications for intervention: extreme orbital pressure with functional deficit or intractable pain, and cosmetic disfigurement (4). A varix rarely leads to visual loss or extreme pain unless there is spontaneous intraorbital hemorrhage or unexpected thrombosis.

### Case Report

A 21-year-old man reported left-sided exophthalmos, which increased markedly in the prone position, of 10 months' duration. At examination, visual field, ocular mobility, and visual acuity were normal; the fundi were unremarkable; and no bruit or pulsation was noted. While the patient was sitting upright, the left eye was exophthalmic by 2 mm. A CT study of the orbits showed a left-sided retrobulbar mass enhancing heterogeneously with small calcifications (Fig 1A and B). In the prone

position, the size of the mass increased dramatically, inducing a 6-mm exophthalmos (Fig 1C). T1-weighted MR imaging showed an intermediate signal mass with heterogeneous enhancement after contrast infusion (Fig 1D and E). Orbital venography clearly showed that the retrobulbar mass was consistent with a multilobulated venous pouch located at the junction of the second and third part of the left superior ophthalmic vein (Fig 1F). Treatment of the varix was undertaken to remedy cosmetic disfigurement.

A 4-cm left-sided frontotemporal craniectomy was performed to expose surgically the anterosuperior external portion of the varix. The visible portion of the venous dilatation was punctured with an 18-gauge catheter needle, and a microcatheter (Mag 2F/3F, Balt, France) was introduced. The microcatheterization and the embolization of the varix with free tungsten microcoils (Balt) were performed under fluoroscopic control in the operating room. Five punctures with different orientations of the needle were required to reach the different lobules of the venous pouch, and a dozen coils were necessary to achieve near complete filling of the varix.

The day after the procedure, the patient's left orbit became moderately painful. This pain was related to the thrombosis of the varix, and the patient was put on anticoagulant therapy for a week. Eight days after the surgery, orbital venography was performed and showed complete occlusion of the venous malformation (Fig 1G–I). At 6 months' follow-up, the patient was asymptomatic, and the exophthalmos had disappeared even in the prone position.

### Discussion

Methods of treatment of orbital varix include surgical excision, electrothrombosis, injection of sclerosing agents, and venous embolization with microcoils. To our knowledge, no large series of patients treated for orbital varix, regardless of the method, has been published. In cases treated by surgical excision, bleeding tends to complicate the dissection and to obscure the fine branches of the motor nerves to the extraocular muscles, which may inadvertently be cut, resulting in some degree of ophthalmoplegia (1). However, the surgical excision is rarely complete, and this treatment, according to Miller (5), is "only moderately successful." Even though electrothrombosis is the method of choice for the treatment of orbital varicosities (6), electrothrombosis alone cannot cure a large

Received March 20, 1997; accepted after revision August 26.

From the Departments of Interventional Neuroradiology (A.W., C.C., L.C., J.M.) and Neurosurgery (G.R.), Fondation Ophtalmologique Adolphe de Rothschild, Paris, France.

Address reprint requests to Dr Jacques Moret, Department of Interventional Neuroradiology, Fondation Ophtalmologique Adolphe de Rothschild, 27–29 rue Manin, 75019 Paris, France.

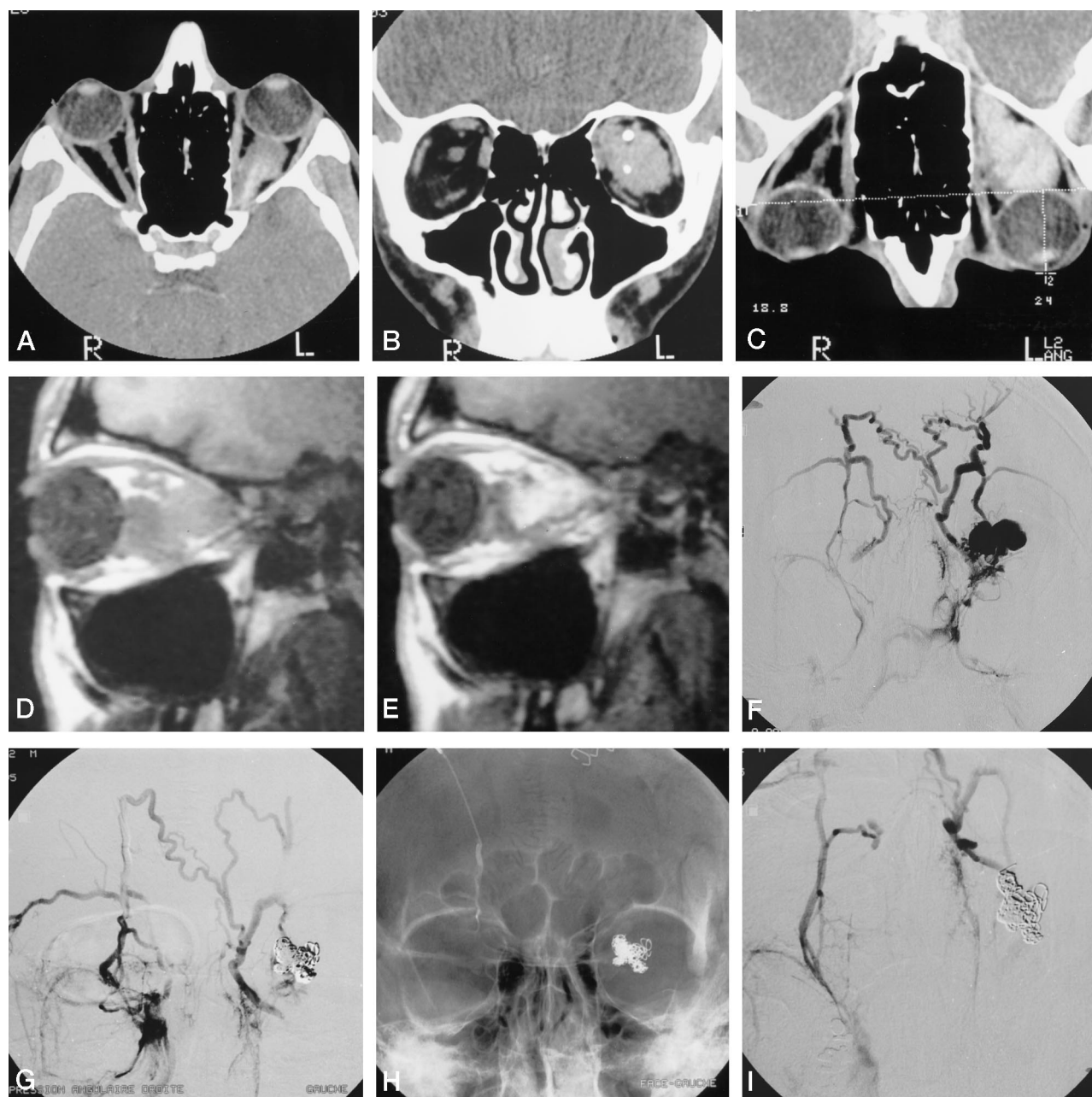


FIG 1. 21-year-old man with left-sided exophthalmos of 10 months' duration.

Axial (A) and coronal (B) contrast-enhanced CT scans of the orbits, and axial scan in the prone position (C). Note the calcifications on coronal view (B) and the increasing size of the mass in prone position (C).

Sagittal spin-echo T1-weighted (250/30 [TR/TE]) MR images of the left orbit before (D) and after (E) contrast infusion show an enhancing retrolbulbar isointense mass.

F, Orbital venogram before embolization shows a venous pouch at the junction of the second and third part of the left superior ophthalmic vein.

Orbital venograms obtained 8 days after embolization in frontal view with (G) and without (H) subtraction, and in base view (I), show an absence of opacification of the venous pouch now filled with coils.

orbital varix; it can, however, facilitate its surgical removal (7, 8). Injection of sclerosing agents is difficult to control even under fluoroscopy, and therefore is dangerous. As shown by Takechi et al (9), orbital venous embolization with microcoils can be performed by using an endovascular route after catheterization of the cavernous sinus via the jugular vein and the inferior petrosal sinus. Unfortunately, as mentioned by these authors, developmental varia-

tions may make this approach technically difficult, rendering it infeasible in some cases. Embolization of a primary orbital varix after surgical exposure has the advantage of limiting traumatic dissection and avoiding difficult catheterization. Nevertheless, embolization treatment is probably more useful for saccular or segmental venous dilations, as in our case, than for tangled plexus of venous channels. Embolization is clearly not the treatment for spontaneous intraorbital

hemorrhage or unexpected thrombosis due to an orbital varix.

### Conclusion

Most primary orbital varices do not require aggressive treatment. In cases of acute thrombosis or hemorrhage, surgery may be required to remove a hematoma or clotted vessel. For patients with severe intermittent exophthalmos and cosmetic disfigurement, treatment by embolization after surgical exposure is a safe and relatively easy procedure, particularly if the orbital varix is consistent with saccular or segmental venous dilatations.

### Acknowledgment

Thanks to Nelly Elbaz Weill for her review of the English.

### References

1. Henderson JW. *Orbital Tumors*. 3rd ed. New York: Raven Press; 1993:128–133
2. Lloyd GA, Wright JE, Morgan G. **Venous malformations in the orbit.** *Br J Ophthalmol* 1971;55:505–515
3. Rubin PA, Bilyk JR, Dunya IM, Weber AL. **Spiral CT of an orbital venous malformation.** *AJNR Am J Neuroradiol* 1995;16:1255–1257
4. Rootman J. *Diseases of the Orbit: A Multidisciplinary Approach*. Philadelphia: Lippincott; 1988:553–557
5. Miller NR. *Walsh and Hoyt's Clinical Neuro-Ophthalmology*. 4th ed. Baltimore: Williams & Wilkins; 1988:1503–1508
6. Ward PH. **The treatment of orbital varicosities.** *Arch Otolaryngol Head Neck Surg* 1987;113:286–288
7. Handa H, Mori K. **Large varix of the superior ophthalmic vein: demonstration by angular phlebography and removal by electrically induced thrombosis.** *J Neurosurg* 1968;29:202–205
8. Rivas JJ, Lobato RD, Cordobes F, Barcena A, Millan JM. **Intermittent exophthalmos studied with computerized tomography: report of two cases.** *J Neurosurg* 1982;57:290–294
9. Takechi A, Uozumi T, Kiya K, et al. **Embolization of orbital varix.** *Neuroradiology* 1994;36:487–489