



Discover Generics

Cost-Effective CT & MRI Contrast Agents



WATCH VIDEO

AJNR

Predictors of aneurysmal occlusion in the period immediately after endovascular treatment with detachable coils: a multivariate analysis.

F Turjman, T F Massoud, J Sayre and F Viñuela

This information is current as of June 21, 2025.

AJNR Am J Neuroradiol 1998, 19 (9) 1645-1651
<http://www.ajnr.org/content/19/9/1645>

Predictors of Aneurysmal Occlusion in the Period Immediately after Endovascular Treatment with Detachable Coils: A Multivariate Analysis

Francis Turjman, Tarik F. Massoud, James Sayre, and Fernando Viñuela

BACKGROUND AND PURPOSE: Complete intracranial aneurysmal occlusion by endovascular techniques is required for successful treatment and is presumably influenced by several parameters. The purpose of this study was to investigate whether operator experience and angiographic characteristics of intracranial aneurysms correspond to the degree of endovascular occlusion in the period immediately after treatment with Guglielmi detachable coils (GDCs).

METHODS: Pre- and posttreatment angiograms of 72 patients undergoing GDC treatment were reviewed retrospectively. The following angiographic characteristics of the aneurysms were evaluated: largest diameter of the sac, volume, neck size, shape, type, cerebrovascular site, surroundings, and likely direction of aneurysmal inflow as judged by a score developed by measuring aneurysm/parent artery angulation. The chronological sequence in which the aneurysms were treated was used as a measure of operator experience. A χ^2 -test was used to identify parameters that correlated with outcomes of total (100%) or partial (<100%) occlusion. A multivariate analysis was used to determine the factors most predictive of aneurysmal occlusion at therapy.

RESULTS: Parameters that correlated with the unsatisfactory result of partial occlusion were large aneurysmal diameter, volume, and neck size, more direct inflow (ie, increasingly obtuse aneurysm/parent artery angulation), and early chronological presentation in the series. The three factors most predictive of partial occlusion were large aneurysmal diameter, more direct inflow, and early chronological order of treatment.

CONCLUSION: Several morphologic features of aneurysms were identified to help predict the immediate outcome of occlusion with GDCs. This study underscores the existence of a steep learning curve associated with GDC use in treating aneurysms and the importance of operator experience in achieving optimal therapeutic results.

Aneurysmal neck size is known to be an important predictor of outcome in endovascular coil occlusion of intracranial aneurysms (1). To date, studies of other factors that may influence treatment outcome have received little attention in the literature. Our

aim was to examine several clinical, morphologic, and angiographic characteristics of intracranial aneurysms in terms of their effect on the extent of endovascular occlusion obtained in the period immediately after treatment with Guglielmi detachable coils (GDCs) (Target Therapeutics, Fremont, CA).

Received November 10, 1997; accepted after revision May 5, 1998.

Presented at the annual meeting of the American Society of Neuroradiology, Chicago, April 1995.

From the Department of Radiology, Hôpital Neurologique, Lyon, France (F.T.); and the Departments of Radiological Sciences (T.F.M., F.V.) and Biostatistics (F.V.), UCLA School of Medicine, Los Angeles, CA.

Address reprint requests to Francis Turjman, MD, PhD, Department of Radiology, Hôpital Neurologique, 59 Boulevard Pinel, 69003 Lyon, France.

© American Society of Neuroradiology

Methods

Over a 2-year period, a total of 79 patients harboring 79 aneurysms were referred to our institution for endovascular treatment with GDCs. Clinical details and angiograms obtained in the orthogonal plane before and immediately after GDC treatment were reviewed retrospectively in all cases. Seven patients with seven aneurysms were excluded, in three cases because the aneurysms were fusiform and in four cases because the procedure was interrupted (in one case because of coil migration into the parent vessel, in another because of aneurysmal rupture, and in two because of incomplete delivery

of coils attributed to technical mishaps). Clinical presentation included subarachnoid hemorrhage (34 patients), mass effect (18 patients), incidental findings (18 patients), carotid cavernous fistula (one patient), and headache (one patient).

Aneurysmal Characteristics

Angiographic characteristics that were evaluated are listed below.

Largest diameter of the aneurysmal sac.—The results were grouped into three categories according to a well-established and accepted classification (2): less than 12 mm (small), 12 to 25 mm (large), and more than 25 mm (giant).

Volume of the aneurysmal sac.—This characteristic was determined by the product of three diameters in the orthogonal plane. The result is proportional to the actual volume of an aneurysm that is spherical or ellipsoidal in shape, since the volume of a sphere with a radius r is $\frac{4}{3}\pi r^3$ and the volume enclosed in an ellipsoid with three diameters, $2a$, $2b$, $2c$, is $\frac{4}{3}\pi abc$. Three categories were determined: less than 100 mm^3 , 100 to 1000 mm^3 , and more than 1000 mm^3 . This subdivision of aneurysmal volume was performed in an arbitrary manner to reflect in a general way on the likely occurrence of aneurysms that were less than 5 mm, 5 to 10 mm, and more than 10 mm in size, respectively. This arbitrary subdivision was decided upon before the statistical analysis was performed and was not altered once established.

Neck size.—The aneurysms were divided into two groups according to the size of the aneurysmal neck, 4 mm being the cut-off value between small (<4 mm) and wide (>4 mm) necks (3). All measurements were made on the diagnostic angiograms according to a method that uses the average reported caliber of the major intracranial vessels (1). These measurements of neck size were made on the projection from which the neck could be easily identified and clearly measured with a translucent ruler to within an attempted accuracy of 0.25 mm. Given the reference value, A , 3 to 5 mm proximal to the internal carotid artery bifurcation ($A = 3.45$) or the basilar artery distal to the vertebrobasilar junction ($A = 3.27$ mm), in addition to the diameter of the contrast-filled lumen of the internal carotid artery or basilar artery (a) and the largest width of the neck (n) measured on the same angiographic film, the real neck width (N) was calculated according to the equation

$$N = (n \times A)/a$$

Aneurysmal shape.—This feature was characterized as round, oval, or multilobulated.

Aneurysmal type.—Aneurysms were considered to be lateral, bifurcation, or terminal, as determined by the parent vessel. Most intracranial aneurysms are bifurcation or terminal types. Truly lateral aneurysms may occur in the cavernous and supraclinoid segments of the internal carotid artery (4). Terai et al (5) found eight such aneurysms in 210 patients with internal carotid aneurysms.

Cerebrovascular site.—Five locations were possible: vertebrobasilar, carotid branches, cavernous sinus, carotid ophthalmic, and others. These groups were selected to address endovascular accessibility of the aneurysm as well as clinical implications.

Surroundings.—These were the subarachnoid space (eg, an internal carotid artery free-hanging in the subarachnoid cistern) or the brain (eg, anterior communicating artery or middle cerebral artery aneurysms embedded in cerebral tissue) (6). It has been surmised by Mizoi et al (6) and by Björkstén and Troupp (7) that, to some extent, these surroundings may (along with intraaneurysmal hemodynamics and the behavior of the aneurysmal wall) influence the growth and shape of aneurysms.

Aneurysmal flow.—A score based on the angles between the long axis of the aneurysm and the direction of flow in the parent vessel was devised and calculated in anteroposterior and lateral planes to evaluate the likely prominence, or direction, of

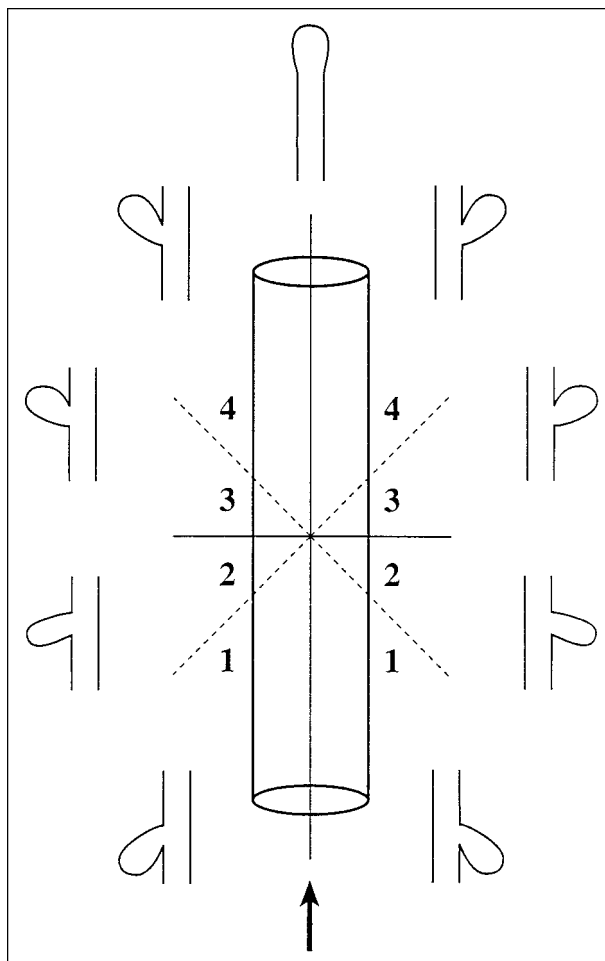


FIG 1. Schematic diagram of the scoring system devised for indirect assessment of the prominence, or direction, of aneurysmal inflow. This takes into consideration the angle formed by the long axis of the aneurysm relative to the long axis of the parent artery (which is considered to be the 0° line). Aneurysms found in zone 1 have an angulation of 0° to 45° relative to the long axis of the parent artery; zone 2, 45° to 90° ; zone 3, 90° to 135° ; and zone 4, 135° to 180° . For each aneurysm the score on the frontal angiographic view is added to that on the lateral view to give a combined score that varies from 2 to 8 (see text). Arrow indicates the direction of flow in the parent artery.

aneurysmal inflow (see Fig 1). The anteroposterior and lateral view scores were calculated, and the aneurysms were divided into three groups according to the sum of these scores: those with a total score of 4 or 5, a total score of 6 or 7, and a total score of 8.

In addition to the above morphologic and angiographic characteristics of the aneurysms under investigation, the chronological sequence in which the aneurysms were treated was used as a measure of accumulating operator experience. Four groups (ranging from the earliest to the most recent) were thus identified, with each group containing 18 treated aneurysms.

Statistical Methods

All aneurysmal characteristics, as well as the clinical presentation and chronological sequence of treatment, were subjected to statistical analysis. The correlation with one target variable was tested by means of a χ^2 -test. These characteristics were selected because they were deemed to have a possible influence on the result of aneurysmal occlusion, according to our own experience or as reported previously in the literature.

TABLE 1: Distribution of aneurysmal characteristics and chronology of treatment in 72 patients

Characteristics	No. of Aneurysms Completely Occluded (n = 28)	No. of Aneurysms Partially Occluded (n = 44)	Total No. of Aneurysms (n = 72)
Largest diameter of aneurysmal sac (mm)			
<12	20	12	32
12–25	8	27	35
>25	0	5	5
Aneurysmal site			
Vertebrobasilar	14	20	34
Carotid-opthalmic	4	7	11
Cavernous-sinus	2	2	4
Other locations	8	15	23
Inflow score			
4–5	13	14	27
6–7	4	20	24
8	11	10	21
Aneurysmal surroundings			
Brain	19	39	58
Subarachnoid space	9	5	14
Aneurysmal volume (mm ³)			
≤100	3	3	6
100–1000	19	16	35
>1000	6	25	31
Size of aneurysmal neck (mm)			
≤4	17	12	29
>4	11	32	43
Shape of aneurysmal sac			
Round	5	8	13
Oval	17	28	45
Multilobulated	6	8	14
Type of aneurysm			
Lateral	10	9	19
Bifurcation	8	18	26
Terminal	10	17	27
Chronology of treatment (patient no.)			
0–18	3	15	18
19–36	8	10	18
37–54	9	9	18
55–72	11	7	18

In case of a sample smaller than 10, a Yates' corrected test was used. The statistical level of significance was $P = .05$. The target variable was the completeness of aneurysmal occlusion, which allowed the identification of two groups of aneurysms: those occluded completely (100%) and those occluded partially (<100%; that is, a portion of the aneurysm, either a neck remnant or a section of the aneurysmal sac, filled with contrast medium) (1). Once significant vascular characteristics were identified, a stepwise multiple logistic regression model was developed using BMDP PLR statistical software (8). This model has the following general form:

$$\text{Probability (Y = 1/X}_1, \text{X}_2, \dots \text{X}_k) = \text{Exp} (\beta_0 + \beta_1 X_1 + \dots + \beta_k X_k) / 1 + \text{Exp} (\beta_0 + \beta_1 X_1 + \dots + \beta_k X_k)$$

in which $Y = 1$ if the aneurysmal occlusion was complete and $Y = 0$ if not; β is the logistic regression coefficient estimate, and X_1, \dots, X_k are possible independent variables as described above. Use of a forward stepwise approach allowed each variable to be considered sequentially in relation to other potentially significant variables. Only significant variables were kept in the model. Final estimates of the weight were based on maximum likelihood solutions. Estimated relative risks and 95% confidence intervals were calculated from the coefficient. Nominal qualitative variables were transformed into quantita-

tive variables (presence of characteristic = +1, absence of characteristic = 0).

From the point of view of variable selection, the analysis was based on model-building techniques. The adequacy of the fitted logistic model must address issues of variable selection with biological implications of the selected model accounted for as well as scale identification (9, 10). The upper limit of one confidence interval estimate was large, but these limits were based on asymptotic distributions. Estimates of the standard error for the various estimated parameters appeared quite reasonable.

The approach to variable selection was to use a stepwise forward selection with a test for backward elimination. The stepwise approach is useful and intuitively appealing in that it builds models in a sequential fashion and allows for a collection of models that might not otherwise have been examined. This was the approach used with selected interaction terms at various stages based on clinical judgment and biological significance.

Results

The angiographic/morphologic features of the 72 aneurysms examined in this study are summarized in

TABLE 2: Logistic regression coefficient estimates, standard error estimates, and odds ratio estimates with 95% confidence intervals

Characteristics	Logistic Regression Coefficient Estimate	Standard Error Estimates	Odds Ratio Estimates	95% Confidence Interval for Odds Ratio	
				Lower	Upper
Largest aneurysmal diameter	2.46	0.75	11.70	2.59	52.90
Inflow score	1.37	0.94	3.92	0.59	25.90
Chronology of treatment	-2.73	1.15	0.07	0.007	0.65

TABLE 3: Correlation matrix of coefficients

	Largest Aneurysmal Diameter (mm)	Inflow Score	Chronological Sequence
Largest aneurysmal diameter (mm)	1.0	0.413	-0.417
Inflow score		1.0	0.019
Chronological sequence			1.0

Table 1. Twenty-eight aneurysms were completely occluded and 44 were partially occluded, as determined on immediate posttherapeutic angiograms.

The following five parameters were found to correlate with an immediate unsatisfactory therapeutic result of partial aneurysmal occlusion: large diameter ($P = .006$), large volume ($P = .05$), large neck size ($P = .01$), more direct inflow (ie, increasingly obtuse aneurysm/parent artery angulation) ($P = .05$), and early chronological presentation in the series ($P = .0008$). For the first and last parameters, a statistical progression was demonstrated among the subgroups (ie, better results were achieved with small aneurysms than with large ones, and with large aneurysms than with giant ones).

Using a multivariate analysis, three factors were most predictive of unsatisfactory partial occlusion: large aneurysmal diameter, more direct inflow, and early chronological order in the treatment sequence. For each variable that entered the model, Table 2 gives the estimated logistic regression coefficient (β), the estimated standard error (SE [β]), the estimated odds ratios (OR), and the 95% confidence intervals for the relative risks. The relative risk indicates the likelihood that an aneurysm with a given characteristic will be incompletely occluded relative to an aneurysm without that parameter. The correlation matrix of coefficients is shown in Table 3.

Discussion

Complete occlusion of an intracranial aneurysm is a necessary goal of both surgical and endovascular treatment methods. Regrowth and/or rebleeding from aneurysms incompletely treated by surgery are well documented in the literature (11–23). Similar consequences have been reported after incomplete endovascular occlusion of aneurysms with detachable balloons (14–16) or coils (17).

The technique of occluding intracranial aneurysms by means of GDCs was developed to offer a control-

lable approach to aneurysmal treatment via the endovascular route (18, 19). With accumulating initial experience in the use of GDCs, it has become apparent that the best therapeutic results (complete occlusion) are obtained in aneurysms possessing small necks. Thus, the size of the aneurysm's neck is regarded as an important determinant of success for this particular form of treatment (1).

In the presence of a small aneurysmal neck, detached coils are held inside the aneurysmal sac, allowing dense packing with low risk of coil migration or impingement on the parent artery. Dense coil packing is especially important in the region of the aneurysmal neck. Bridging this area with coils appears to be crucial in preventing their compaction toward the fundus, which occurs as a consequence of the constant force of pulsating arterial blood flow (the "water-hammer effect" [20]) acting on the orifice of the aneurysm. Immediate and complete occlusion can thus be achieved in the great majority (about 85%) of small-necked aneurysms (1). On the other hand, wide-necked aneurysms cannot be densely packed because of the risk of depositing coils in the parent vessel or of their herniating into the parent vessel once detached appropriately within the sac. Inadvertent coil placement outside the aneurysm is a known potential complication of simple, nondetachable coils (21). However, this complication is usually avoided when using GDCs, owing to their inherent ability to be retrieved before they are detached. Thus, coils that are placed inside the aneurysmal sac but that herniate into the parent artery because the neck is too wide to contain them within the aneurysmal lumen are, therefore, retrieved before they are detached. Inevitably, this difficulty results in the detachment of fewer coils than may be desirable/ideal and in loose packing of the aneurysm, with less likelihood of bridging the entire neck region with coils. This imperfect packing together with exposure of a relatively large surface area of the aneurysmal neck to the water-hammer effect leads to incomplete occlusion in the majority of wide-necked aneurysms (about 85%) (1) and to progressive compaction of coils in the months after treatment, resulting in the formation of aneurysmal remnants.

Technical refinements, such as the so-called remodeling technique, have been proposed (22) to improve the endovascular occlusion of wide-necked aneurysms. The ability to identify aneurysms that are incompatible with immediate and complete packing

may help us to select those aneurysms that would benefit from a more sophisticated approach.

It is not known at present whether the natural history of aneurysmal remnants left from surgical clipping differs from that of those left from endovascular coiling. Along with the increasing use of exact figures (expressed as a percentage of aneurysmal volume) to describe the extent of aneurysmal occlusion after GDC treatment (and an apparent ability to discern a degree of occlusion to the nearest fifth percentile) (23–25) is an accompanying lack of agreement as to what percentage of occlusion may be regarded as “satisfactory.” For example, Martin et al (26) regarded 90% occlusion as signifying a satisfactorily coiled aneurysm, whereas Spetzger et al (25) used a figure of more than 95% occlusion. In reality, it is debatable whether an exact percentage of occlusion to the nearest fifth percentile can be determined reliably and reproducibly by different investigators. Moreover, any knowledge of which exact percentage of occlusion may be regarded as satisfactory is likely to emerge only after long-term follow-up of aneurysmal remnants of different sizes. For these reasons, and to avoid any further confusion, we have chosen to divide the treated aneurysms in our series into those that were occluded completely (100%) and those that were occluded partially (<100%), a strategy that was adopted previously by Zubillaga et al (1).

The general consensus is that posttherapeutic aneurysmal remnants are not benign entities. This is not only so for remnants that are evident at long term follow-up but also in the short-term period after treatment. Suzuki et al (27) reported the rupture of an aneurysmal remnant after surgical clipping that occurred postoperatively while the patient was still hospitalized. Hence, this early risk of rebleeding illustrates the importance of this study in analyzing the determinants of complete or incomplete aneurysmal occlusion in the immediate period after GDC treatment. Clearly, predictors of the extent of aneurysmal occlusion at long-term follow-up also are of paramount importance, since it is the persistence of aneurysmal obliteration that governs the success of any particular form of therapy for intracranial aneurysms. It should be possible to perform such an analysis with further accumulation of data from those patients treated with GDCs in the past several years.

A further justification for the need to establish and study those predictors of aneurysmal occlusion in the immediate period (as opposed to later periods) after GDC treatment arises from an understanding of the frequency with which incomplete (<100%) aneurysmal occlusion spontaneously progresses to complete (100%) occlusion. If this frequency is low, it could be argued that awareness of the anatomic result (the percentage) of aneurysmal occlusion is just as important immediately after treatment as at later follow-up because there is a low likelihood of it progressing to 100%. Progression of aneurysmal remnants to complete thrombosis appears to be rare after surgical clipping. In a series of 578 clipped aneurysms with 41 cases of aneurysmal remnants, Suzuki et al (27) found

a natural complete disappearance of remnants in two patients within 6 months of initial treatment. On the other hand, among a small series of 12 patients who had angiographic follow-up, Martin et al (26) noted the progression of one incompletely (80%) occluded aneurysm with GDCs to 100% occlusion at 3 and 6 months after initial treatment. It is acknowledged that the mechanisms of progression of thrombosis within postsurgical and postendovascular aneurysmal remnants may differ considerably. A striking example of the dynamic nature of thrombosis/thrombolysis within aneurysms partially treated with GDCs was provided by Renowden and Molyneux (28). Nevertheless, as judged by the above examples (26, 27), immediate *incomplete* anatomic results of aneurysmal treatment usually appear to persist as incomplete; that is, progression of thrombosis may occur, but this infrequently evolves to *complete* occlusion, demonstrating the importance of establishing predictors of success in the period immediately after treatment as well as at later follow-up.

Three of five parameters (large aneurysmal diameter and volume, and large neck size) that we found to correlate with an immediately unsatisfactory therapeutic result (partial aneurysmal occlusion) are clearly related to one another. Thus, large and giant aneurysms with large volumes also tend to have wide necks (26). This association may explain why only one of these parameters (large diameter) was found to be a predictor of incomplete aneurysmal occlusion when using multivariate analysis. It is not surprising that of these three parameters only neck size continues to receive the most attention as a predictor of aneurysmal occlusion (1). This is a direct reflection on the specific characteristics of the GDC system and the biomechanical interaction of these coils with their surroundings once released in the aneurysmal sac. Because GDCs do not appear to induce immediate and pronounced formation of firm or adherent thrombus (29) that might help fix their position within the sac, they are liable to remain unstable in the presence of a wide neck (as described above), leading to possible herniation into the parent artery. The issue of neck size in relation to stability of intrasaccular coils has been highlighted recently by Martin et al (26), who described the use of the ratio A/N (the aneurysm's largest diameter/neck size) in predicting the stability of GDCs in aneurysms. If A/N is 2 or less, the stability of coils within an aneurysm becomes uncertain. This uncertainty is usually anticipated beforehand by the operator, resulting in deliberate underfilling of the aneurysm and an immediate postembolization result of partial aneurysmal occlusion.

A further predictor of occlusion of aneurysms in the period immediately after treatment was the prominence of aneurysmal arterial inflow; that is, the presence of an increasingly obtuse aneurysm/parent artery angulation. Clearly, the score that we developed to describe the spatial relationship between an aneurysm and its parent artery is an indirect one that will require validation in future prospective evaluations. This simple model does not take into account other

factors influencing the arterial inflow, such as geometry of the parent artery proximal to the aneurysm with respect to the formation of eddy currents and slip streams. Nevertheless, it was conceived as a simple means of assessing the hemodynamic impact of the arterial blood in the parent artery in the region of the aneurysmal neck and the contents of the aneurysmal sac. The more obtuse the angle, the greater the flow separation at the distal lip of the aneurysm, resulting in a greater contribution to aneurysmal inflow (30) and a greater water-hammer effect on coils at the neck or within the sac. Recently, Raymond et al (31) described their angiographic results for GDC treatment of basilar tip aneurysms (score = 8 in our study). Fifty-eight percent of these aneurysms were incompletely obliterated on the immediate postembolization angiogram. There exists the theoretical possibility that this water-hammer effect could accentuate the compaction of GDCs in aneurysms because of the softness of these particular coils (21, 24). However, no studies exist that correlate the time course of coil compaction in aneurysms with the firmness of the coils and the hemodynamic conditions leading to the water-hammer effect. Although this factor is more relevant for long-term follow-up of aneurysms, it is a usual clinical finding that inflow aneurysms require denser packing to achieve complete occlusion. This suggests the influence of the water-hammer effect even in immediate occlusion of aneurysms. A more elaborate assessment of the prominence of this aneurysmal inflow might entail direct or indirect measurements of flow velocities within the parent artery and in the aneurysmal sac; evaluations that may be possible in future, more comprehensive, studies.

The results of our statistical analysis confirmed the existence of a definite, steep learning curve in the application of the GDC system to the endovascular treatment of aneurysms (21). Early clinical experience is statistically associated with less favorable results, especially when considering specifically the issue of extent of aneurysmal occlusion. In this study we did not analyze the influence of operator experience on other measures of unfavorable outcome, such as the occurrence of complications. The simple method we used to analyze the influence of operator experience on the results of treatment (dividing our patients into equal consecutive groups of 18) was a slight variation on the technique adopted previously by Suzuki et al (27) in examining this issue in relation to results of aneurysmal clipping (dividing their 15-year experience into equal consecutive groups of 5 years). Our findings emphasize the need for adequate training in the use of the GDC system; Nichols has stated that "the endovascular treatment of intracranial aneurysms should not be performed by a novice" (21). It should be necessary to acquire and develop both cognitive and technical skills in GDC occlusion of intracranial aneurysms, as is the case for other complex or demanding interventional neuroradiologic techniques (32).

We acknowledge that exclusion of seven patients from our analyses represents an overall limitation of

the study, since these patients constitute about 10% of the total population studied. Strictly speaking, a better approach would have been to also include data in the statistical analysis from patients in whom treatment failed. However, our intention from the outset was to examine predictors of immediate outcome for those aneurysms in which treatment was performed without obvious complications or significant anatomical handicaps (eg, fusiform aneurysms). Although the size of the cohort was adequate from a statistical point of view, it should be possible to arrive at more definitive conclusions by studying much larger populations, as may be possible through multicenter pooling of data. However, our analysis was not intended to be exhaustive by nature, and clearly there are many other factors that could affect immediate outcome after GDC treatment of aneurysms that will need to be taken into account in future investigations; for example, the occurrence of complications during the procedure, the degree of anticoagulation, the type of anesthetic used, the presence/absence of vasospasm, and the effects of evolving technology and newer devices.

Conclusion

Several morphologic features of aneurysms (large size, volume, and neck, and increasingly obtuse angulation between the long axis of the aneurysm and the parent artery) were identified to help predict the immediate outcome of occlusion with GDCs. Knowledge of these parameters may help in the selection of patients most likely to benefit from this endovascular treatment. Our study underscores the existence of a steep learning curve associated with GDC treatment of intracranial aneurysms and the importance of operator experience in achieving optimal therapeutic results.

Acknowledgments

We are grateful to G. Duckwiler and G. Guglielmi for their assistance in collecting the clinical data.

References

1. Zubillaga AF, Guglielmi G, Vinuela F, et al. **Endovascular occlusion of intracranial aneurysms with electrically detachable coils: correlation of aneurysm neck size and treatment results.** *AJNR Am J Neuroradiol* 1994;15:815-820
2. Guglielmi G, Vinuela F. **Intracranial aneurysms. Guglielmi electrothrombotic coils.** *Neurosurg Clin N Am* 1994;5:427-435
3. Yasargil MG. **Pathological considerations.** In: Yasargil MG, ed. *Microneurosurgery*. Stuttgart: Thieme; 1984:280-281
4. Strother CM, Graves VB, Rappe A. **Aneurysm hemodynamics: an experimental study.** *AJNR Am J Neuroradiol* 1994;13:1089-1095
5. Terai Y, Sugiu K, Mandai S. **Unbranched-site aneurysm of internal carotid artery.** *Neurol Surg* 1992;20:741-748
6. Mizoi K, Kwak R, Sakamoto T. **Angiographical study of intracranial saccular aneurysms with particular reference to their size and shape.** In: Suzuki J, ed. *Cerebral Aneurysms: Experience with 1000 Directly Operated Cases*. Tokyo: Neuron Publishing; 1979:619-630
7. Björkstén G, Troupp H. **Changes in the size of intracranial arterial aneurysms.** *J Neurosurg* 1962;19:583-588
8. Dixon WJ. *BMDP Statistical Software*. Berkeley: University of California Press; 1990

9. Afifi AA, Clark V. *Computer-Aided Multivariate Analysis*. New York: Van Nostrand Reinhold; 1990
10. Hosmer DW, Lemeshow S. *Applied Logistic Regression*. New York: Wiley; 1980
11. Ebina K, Suzuki M, Andoh A, et al. **Recurrence of cerebral aneurysm after initial neck clipping.** *Neurosurgery* 1982;11:764-768
12. Feuerberg I, Lindquist C, Lindquist M, et al. **Natural history of postoperative aneurysm rests.** *J Neurosurg* 1987;66:30-34
13. Lin T, Fox AJ, Drake CG. **Regrowth of aneurysm sacs from residual neck following aneurysm clipping.** *Neurosurgery* 1989;70:556-560
14. Fox AJ, Drake CG. **Aneurysm neck remnant following balloon embolization.** *J Neurosurg* 1987;67:321-322
15. Hodes JE, Fox AJ, Pelz DM, et al. **Rupture of aneurysms following balloon embolization.** *J Neurosurg* 1990;72:567-571
16. Heilman CB, Kwan ESK, Wu JK. **Aneurysm recurrence following endovascular balloon occlusion.** *J Neurosurg* 1992;77:260-261
17. Casasco AE, Aymard A, Gobin P, et al. **Selective endovascular treatment of 71 intracranial aneurysms with platinum coils.** *J Neurosurg* 1993;79:3-10
18. Guglielmi G, Vinuela F, Sepetka I, et al. **Electrothrombosis of saccular aneurysms via endovascular approach, 1: electrochemical basis, technique, and experimental results.** *J Neurosurg* 1991;75:1-7
19. Guglielmi G, Vinuela F, Dion J, et al. **Electrothrombosis of saccular aneurysms via endovascular approach, 2: preliminary clinical experience.** *J Neurosurg* 1991;75:8-14
20. Kwan ESK, Heilman CB, Shucart WA, et al. **Enlargement of basilar artery aneurysms following balloon occlusion: "water-hammer effect."** *J Neurosurg* 1991;75:963-968
21. Nichols DA. **Endovascular treatment of the acutely ruptured intracranial aneurysm.** *J Neurosurg* 1993;79:1-2
22. Moret J, Cognard C, Weill A, Castaings L, Rey A. **The "remodeling technique" in the treatment of wide neck intracranial aneurysms: angiographic results and clinical follow-up in 56 cases.** *Intervent Neuroradiol* 1997;3:21-35
23. Gurian JH, Martin NA, King WA, et al. **Neurosurgical management of cerebral aneurysms following unsuccessful or incomplete endovascular embolization.** *J Neurosurg* 1995;83:843-853
24. Richling B, Gruber A, Bavinski G, et al. **GDC-system embolization for brain aneurysms: location and follow-up.** *Acta Neurochir* 1995;134:177-183
25. Spetzger U, Reul J, Weis J, et al. **Microsurgically produced bifurcation aneurysms in a rabbit model for endovascular coil embolization.** *J Neurosurg* 1996;85:488-495
26. Martin D, Rodesch G, Alvarez H, et al. **Preliminary results of embolization of non surgical intracranial aneurysms with GD coils: the 1st year of their use.** *Neuroradiology* 1996;38:S142-S150
27. Suzuki J, Kwak R, Katakura R. **Angiographical consideration of residual aneurysms following direct operations on intracranial aneurysms.** In: Suzuki J, ed. *Cerebral Aneurysms: Experience with 1000 Directly Operated Cases*. Tokyo: Neuron Publishing; 1979:619-630
28. Renowden SA, Molyneux AJ. **Thrombosis in giant basilar tip aneurysms during coil embolization.** *AJNR Am J Neuroradiol* 1995;16:866-871
29. Tenjin H, Fushiki S, Nakahara Y, et al. **Effect of detachable coils on experimental carotid artery aneurysms in primates.** *Stroke* 1995;26:2075-2080
30. Graves VB, Strother CM, Partington CR, et al. **Flow dynamics of lateral carotid artery aneurysms and their effects on coils and balloons: an experimental study in dogs.** *AJNR Am J Neuroradiol* 1992;13:189-196
31. Raymond J, Roy D, Bojanowski M, et al. **Endovascular treatment of acutely ruptured and unruptured aneurysms of the basilar bifurcation.** *J Neurosurg* 1997;86:211-219
32. Massoud TF, Ji C, Vinuela F, et al. **Laboratory simulations and training in endovascular embolotherapy with a swine arteriovenous malformation model.** *AJNR Am J Neuroradiol* 1996;17:271-279