



## **Computed Tomography of Blow-Out Fracture of the Medial Orbital Wall**

Albert Zilkha

*AJNR Am J Neuroradiol* 1981, 2 (5) 427-429

<http://www.ajnr.org/content/2/5/427>

This information is current as  
of July 3, 2025.

# Computed Tomography of Blow-Out Fracture of the Medial Orbital Wall

Albert Zilkha<sup>1</sup>

Computed tomographic (CT) findings in four patients with isolated blow-out fracture of the medial orbital wall are reported. CT delineated the fracture site and its extent in each case, and clearly demonstrated medial rectus muscle entrapment in two. This was confirmed by surgery. CT was found superior to polytomography and proved to be the best radiologic means for the diagnosis of medial orbital wall fracture and muscle entrapment.

Blow-out fractures of the medial orbital wall are not uncommon but entrapment of the medial rectus muscle is rare. About 50% of blow-out fractures of the orbital floor are associated with a similar fracture of the medial orbital wall. The plain radiographic and tomographic findings have been described [1-4]. Recently the value of computed tomography (CT) in the evaluation of orbital trauma and particularly blow-out fracture of the orbital floor and muscle entrapment has been emphasized [5, 6]. In this paper, CT findings in blow-out fracture of the medial orbital wall with and without muscle entrapment are described.

## Materials and Methods

During the past 3 years, four patients were found to have evidence on polytomography and CT of isolated blow-out fracture of the medial orbital wall. Plain films were available in each case. The age of the patients was 23-55 years. There were three men and one woman. All patients had obvious trauma to the orbit. Two patients were hit by a fist during a fight, one was hit by a bottle, and one suffered a dashboard injury in a car accident. Clinically, medial rectus muscle entrapment was suspected in cases 1 and 2 and thought unlikely in cases 3 and 4.

CT scanning was performed after a thorough assessment of the plain films and polytomograms. The scans were obtained immediately after trauma in cases 1 and 4, and 1 day after trauma in cases 2 and 3. A GE CT/T 8800 was used in three patients and a GE CT/T 7800 in one (case 2). A 5 mm collimator, 10 sec scanning time, and 320 × 320 matrix were used. The patients were scanned in the axial projection and one patient was also scanned in the coronal projection (case 1). Three patients underwent surgery.

## Results

Plain radiographs revealed unilateral clouding of the ethmoid sinus in all four cases and orbital emphysema in one. A fracture was not identified in any of the cases. Polytomography revealed a blow-out fracture of the medial orbital wall in all four cases and confirmed the presence of orbital emphysema in one (fig. 1A). CT showed a blow-out fracture in all four cases. The medial rectus muscle was found trapped in two cases (figs. 1 and 2), and normal in the other two (figs. 3 and 4). In case 1, entrapment of the medial rectus muscle was better demonstrated on coronal than axial scans (fig. 1C). In case 2, muscle entrapment was demonstrated on the axial scan (fig. 2). In cases 2 and 3, there was opacification

Received January 19, 1981; accepted after revision March 23, 1981.

<sup>1</sup> Department of Radiology, State University of New York at Stony Brook School of Medicine, and Nassau County Medical Center, East Meadow, NY 11554.

This article appears in September/October 1981 *AJNR* and November 1981 *AJR*.

*AJNR* 2:427-429, September/October 1981  
0195-6108/81/0205-0427 \$00.00

© American Roentgen Ray Society



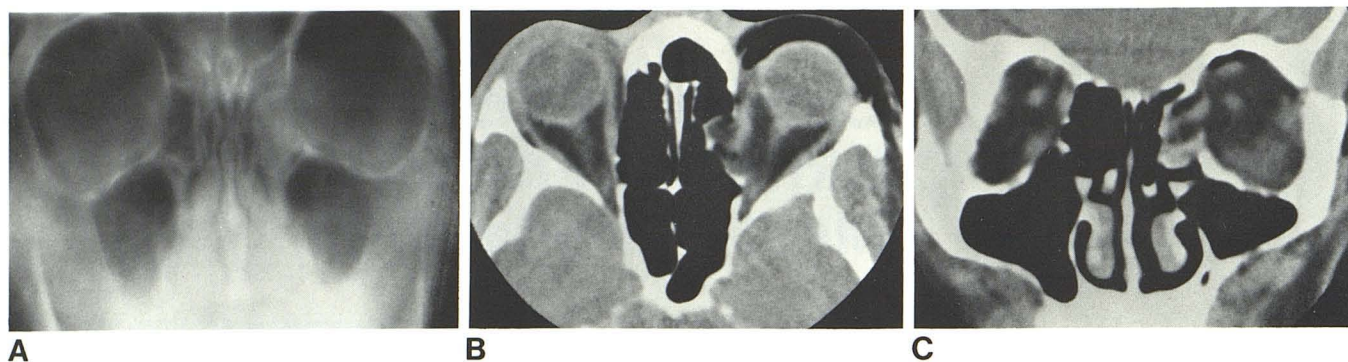

Fig. 1.—Case 1. Blow-out fracture of medial orbital wall with entrapment of medial rectus muscle. **A**, Polytomogram. Fracture of medial orbital wall and orbital content herniation in ethmoid sinus on left. **B**, Axial scan. Blow-

out fracture of medial orbital wall and poor delineation of middle segment of medial rectus muscle on left. Note orbital air. **C**, Coronal scan. Entrapment of medial rectus muscle in ethmoid sinus.

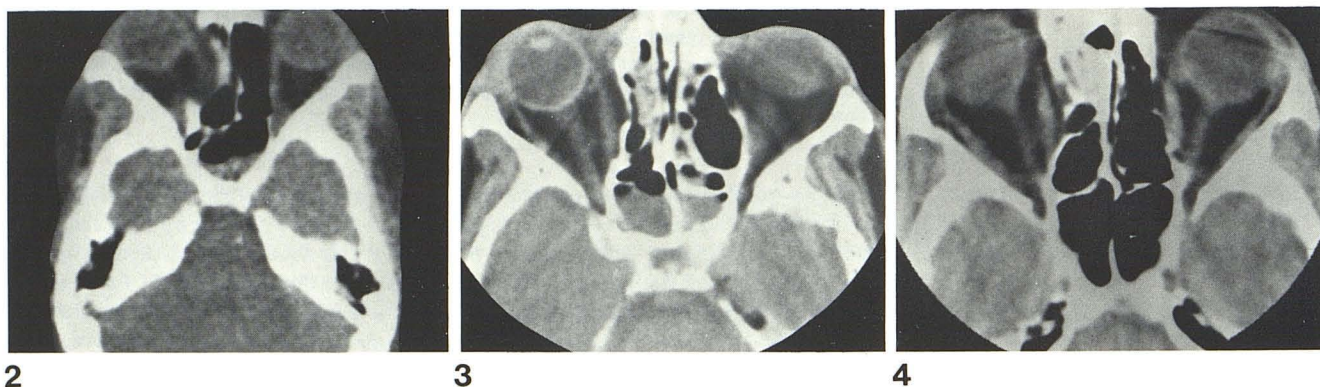


Fig. 2.—Case 2, axial scan. Blow-out fracture of medial orbital wall and entrapment of medial rectus muscle on right. Partially clouded sphenoid sinus.

Fig. 3.—Case 3, axial scan. Blow-out fracture of medial orbital wall and clouded ethmoid sinus on right. Partial opacification of left ethmoid and

sphenoid sinuses. Right medial rectus muscle is well defined and intact. Slight obliquity at scanning level.

Fig. 4.—Case 4, axial scan. Blow-out fracture of medial orbital wall and clouded ethmoid sinus on right. Medial rectus muscle is normal.

of the sphenoid sinuses. This was felt to represent blood accumulation in the most dependent part of the paranasal sinuses, which had probably originated from the ethmoid sinuses and nasal cavities.

Cases 1 and 2 underwent surgery and muscle entrapment was confirmed. In both cases, the depressed fracture was found to be relatively extensive and comminuted with acute margins and impinging on the medial rectus muscle. Case 3 developed progressive enophthalmos and corrective surgical intervention was performed for cosmetic reasons. A normal medial rectus muscle was found. No surgery was undertaken in case 4.

## Discussion

Blow-out fractures of the medial orbital wall are less common than those of the orbital floor. Fracture of the medial orbital wall may occur alone, but is frequently associated with fracture of the orbital floor [1, 4, 7, 8].

The main clinical significance in blow-out fracture of the medial orbit wall lies in the fact that entrapment of the medial rectus muscle may occur. Clinically, the diagnosis of muscle entrapment may be suspected [9, 10]. However, because of marked swelling and edema, eye movements may be markedly restricted, resulting in inadequate ocular evaluation. Nerve damage, orbital edema, or hemorrhage may confuse further the clinical picture and may mimic muscle entrapment. In these instances, the clinical diagnosis of muscle entrapment can be difficult, delayed, or overlooked [4, 5, 11–15].

Plain radiographs may demonstrate clouded ethmoid sinus and orbital emphysema, but often fail to visualize a fracture [1, 3, 14, 15]. Tomography is usually necessary to demonstrate involvement of the medial orbital wall [1–3, 14]. Hypocycloidal tomography is superior to linear tomography in the demonstration of medial orbital wall fracture [4].

In the present series, CT demonstrated a blow-out fracture of the medial orbital wall in all four patients and clearly



identified muscle entrapment in two. This was confirmed at surgery. It is of interest to note from the CT scans of cases 1 and 2 and also from the surgical findings, that muscle entrapment may occur with a relatively extensive blow-out fracture that may involve a significant part of the medial orbital wall (figs. 1B, 1C, and 2). The reason lies in the fact that muscle entrapment may occur in a markedly displaced and comminuted fracture with sharp margins, easily resulting in muscle injury and incarceration. On the other hand, muscle entrapment is unlikely to occur in a smoothly and homogeneously displaced fracture (figs. 3 and 4). Either coronal or axial scanning may be used to evaluate the medial orbital wall. However, whenever the conventional tomographic study is omitted, the CT assessment must include coronal sections in order to rule out the association of a blow-out fracture of the orbital floor.

The diagnosis of muscle entrapment was uncertain on the axial scans in case 1. Coronal scan demonstrated acute change in the course of the medial rectus muscle at the level of the fracture, thus establishing the diagnosis of muscle entrapment. In case 2, the axial scan demonstrated marked medial displacement of the medial rectus muscle at the level of the fracture and acute change in the course of the muscle as it proceeded posteriorly to its normal position at the orbital apex. It is possible that coronal scan would have added more information but was not obtained in light of strong clinical impression of muscle entrapment. In medial orbital wall fracture associated with a mere displacement of the orbital structures, the medial rectus muscle would be expected to follow a more gentle medial curve without sudden change in course. Such a finding was not encountered in any of the cases. In cases 3 and 4, the medial rectus muscle was in normal position.

CT has allowed rapid and conclusive assessment in medial orbital wall trauma and has greatly facilitated the clinical management of these patients. Medial orbital wall fracture and muscle entrapment are readily apparent on CT. Five or six slices, 5 mm each, are usually sufficient to cover the orbit, and the study is completed in a few minutes. It is anticipated that with easy access to CT scanning, and its ready availability as a routine diagnostic tool in orbital

trauma, tomography may be found unnecessary. Thus, in an appropriate clinical setting, coronal CT may be performed after adequate plain film radiography. It is also expected that with the increasing use of CT in orbital trauma, blow-out fracture of the medial orbital wall will be found to be more common than has been previously realized.

#### REFERENCES

1. Gould HR, Titus CO. Internal orbital fractures: the value of laminagraphy in diagnosis. *AJR* **1966**;97:618-623
2. Valvassori GE, Hord GE. Traumatic sinus disease. *Semin Roentgenol* **1968**;3:160-171
3. Trokel SL, Potter GD. Radiographic diagnosis of fracture of the medial wall of the orbit. *Am J Ophthalmol* **1969**;67:772-773
4. Dodick JM, Galin MA, Littleton JT, Sod LM. Concomitant medial wall fracture and blowout fracture of the orbit. *Arch Ophthalmol* **1971**;85:273-276
5. Grove AS Jr, Tadmor R, New PFJ, Momose KJ. Orbital fracture evaluation by coronal computed tomography. *Am J Ophthalmol* **1978**;85:679-685
6. Grove AS Jr. Orbital trauma evaluation by computed tomography. *Comput Tomogr* **1979**;3:267-278
7. Fueger GF, Milauskas AT, Britton W. The roentgenologic evaluation of orbital blow-out injuries. *AJR* **1966**;97:614-617
8. Potter GD. Radiological examination of the orbit. *CRC Crit Rev Diagn Imaging* **1971**;2:145-173
9. Miller GR, Glaser JS. The retraction syndrome and trauma. *Arch Ophthalmol* **1966**;76:662-663
10. Duane TD, Schatz NJ, Caputo AR. Pseudo-Duane's retraction syndrome. *Trans Am Ophthalmol Soc* **1976**;74:122-132
11. Edwards WC, Ridley RW. Blowout fracture of medial orbital wall. *Am J Ophthalmol* **1968**;65:248-249
12. Fischbein FI, Lesko WS. Blowout fracture of the medial orbital wall. *Arch Ophthalmol* **1969**;81:162-163
13. Davidson TM, Olesen RM, Nahum AM. Medial orbital wall fracture with rectus entrapment. *Arch Otolaryngol* **1975**;101:33-35
14. Mirsky RG, Saunders RA. A case of isolated medial wall fracture with medial rectus entrapment following seemingly trivial trauma. *J Pediatr Ophthalmol Strabismus* **1979**;16:287-290
15. Thering HR, Bogart JN. Blowout fracture of the medial orbital wall, with entrapment of the medial rectus muscle. *Plast Reconstr Surg* **1979**;63:848-852