



Providing Choice & Value
Generic CT and MRI Contrast Agents

**FRESENIUS
KABI**

CONTACT REP

AJNR

**Arachnoiditis simulating acoustic neuroma on
air-CT cisternography.**

E F Downey, Jr, D R Buck and J W Ray

AJNR Am J Neuroradiol 1981, 2 (5) 470-471

<http://www.ajnr.org/content/2/5/470.citation>

This information is current as
of July 5, 2025.

Arachnoiditis Simulating Acoustic Neuroma on Air-CT Cisternography

Edward F. Downey, Jr.,¹ David R. Buck,¹ and Joel W. Ray²

Routine thin-section CT after contrast enhancement may fail to demonstrate small acoustic neuromas, usually those smaller than 10 mm [1, 2]. Metrizamide CT cisternography has demonstrated such small acoustic neuromas, but cannot demonstrate an intracanalicular tumor accurately [3]. Pantopaque cisternography can demonstrate an intracanalicular mass, but has a high percentage of inconclusive examinations and a risk of inducing arachnoiditis [4–6]. The newest procedure, air-CT cisternography (air-CTC), has been reported to be more sensitive in demonstrating the small intracanalicular tumor [7, 8]. We describe a case of nonfilling of the acoustic canal on air-CTC caused by arachnoiditis simulating an acoustic neuroma.

Case Report

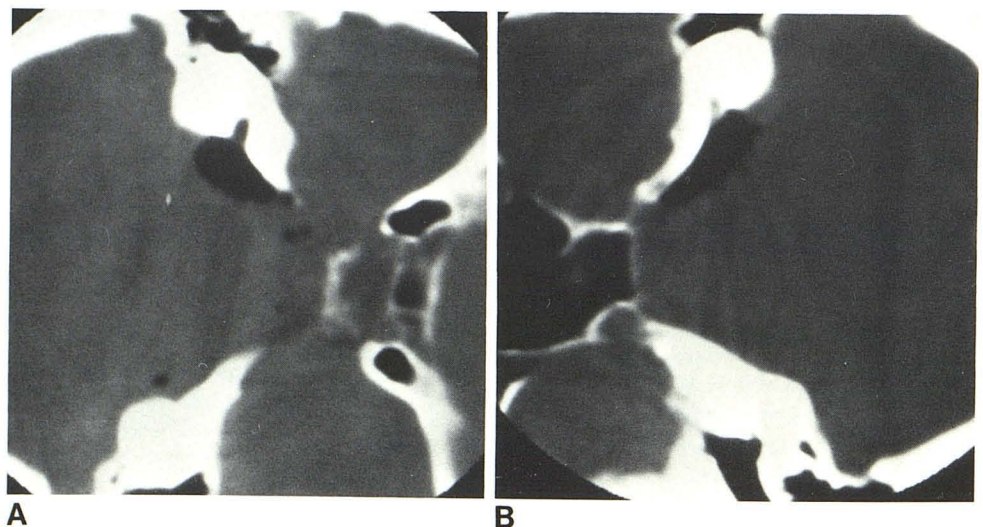
A 59-year-old woman had a 3 year history of progressive left-sided hearing loss, and for 6 months had been experiencing dizziness

and headaches. Audiovestibular examination was consistent with a left retrocochlear lesion. Routine thin-section contrast-enhanced CT was normal. Air-CT was performed with 7 cm³ of air injected intrathecally via lumbar puncture. Thin-section scans of the internal auditory canals in each lateral decubitus position were obtained on a General Electric CT/T 8800 scanner. The right internal auditory canal (IAC) filled normally with air (fig. 1A). The left IAC failed to fill; no air entered the canal despite three attempts after increasingly vigorous head thumping (fig. 1B). At surgery, arachnoiditis surrounding the seventh-eighth nerve complex was found. There was no evidence of an intracanalicular tumor. The patient continued to experience mild left-sided hearing loss post-operatively.

Discussion

With the difficulty in visualizing small acoustic neuromas on contrast-enhanced CT, the inability of metrizamide CTC to demonstrate intracanalicular lesions, and the high inci-

Fig. 1.—Air-CT cisternograms. A, left lateral decubitus position. Air in right cerebellopontine angle cistern and right internal auditory canal. B, Left internal auditory canal in right lateral decubitus position. No air in canal. Preoperative diagnosis was acoustic neuroma.



Received December 4, 1980; accepted December 29, 1980.

This article is the opinion of the authors and in no way reflects the opinion of the United States Navy or the Department of Defense.

¹Department of Radiology, National Naval Medical Center, Bethesda, MD 20014. Address reprint requests to E. F. Downey, Jr.

²Department of Neurosurgery, National Naval Medical Center, Bethesda, MD 20014.

dence of nondiagnostic studies with Pantopaque, air-CTC seems to be a better and safer study. Two series in which air-CTC was performed on a total of 32 patients have been reported [7, 8]. All but one of these patients had normal contrast-enhanced routine CT, and all were suspected of having acoustic neuroma by clinical and audiovestibular testing. Eight were found to be positive on air-CTC (seven surgically proven and one with other positive studies), and 22 were negative with air in the cisterns and canals. One study was nondiagnostic due to technical problems and the other was a false-negative study in a small tumor earlier diagnosed by metrizamide CTC. There were no false-positive studies.

Kricheff et al. [8] believed that air-CTC was superior to the other methods in excluding acoustic neuroma, but postulated that a false-positive study could occur with a very narrow canal or arachnoid webs [8]. The arachnoid webs apparently were the cause of the false-positive study in our case. While air-CT cisternography is the best method for diagnosing or excluding small acoustic neuromas with a high degree of accuracy, the possibility of a false-positive study secondary to arachnoiditis must always be considered.

REFERENCES

1. Dubois PJ, Drayer BP, Bank WO, Deeb ZL, Rosenbaum AE. An evaluation of current diagnostic radiologic modalities in the investigation of acoustic neurilemmomas. *Radiology* **1978**;126:173-179
2. Davis KR, Parker SW, New PFJ, et al. Computed tomography of the acoustic neuroma. *Radiology* **1977**;124:81-86
3. Rosenbaum AE, Drayer BP, Dubois PJ, Black O. Visualization of small extracanalicular neurilemmomas by metrizamide cisternographic enhancement. *Arch Otolaryngol* **1978**;104:239-243
4. Fisch VP, Neozoleki J, Wellaver J. Diagnostic value of meato-cisternography. *Arch Otolaryngol* **1975**;101:339-343
5. Bergeron RT, Rumbaugh CL, Fang H, Cravioto H. Experimental Pantopaque arachnoiditis in the monkey. *Radiology* **1971**;99:95-101
6. Punto L, Svolonen J. Testing of myelographic contrast media using the pig as an experimental animal. *Invest Radiol* **1976**;11:331-334
7. Sortland O. Computed tomography combined with gas cisternography for the diagnosis of expanding lesions in the cerebellopontine angle. *Neuroradiology* **1979**;18:19-22
8. Kricheff II, Pinto RS, Bergeron RT, Cohen N. Air-CT cisternography and canalography for small acoustic neuromas. *AJNR* **1980**;1:57-63