



## Discover Generics

Cost-Effective CT & MRI Contrast Agents



FRESENIUS  
KABI

WATCH VIDEO

# AJNR

## **Parietal Lipoma Associated with Cortical Dysplasia and Abnormal Vasculature: Case Report and Review of the Literature**

Isil Saatci, Cengiz Aslan, Yavuz Renda and Aytekin Besim

*AJNR Am J Neuroradiol* 2000, 21 (9) 1718-1721

<http://www.ajnr.org/content/21/9/1718>

This information is current as  
of June 26, 2025.

## Case Report

# Parietal Lipoma Associated with Cortical Dysplasia and Abnormal Vasculature: Case Report and Review of the Literature

Isil Saatci, Cengiz Aslan, Yavuz Renda, and Aytekin Besim

**Summary:** We present the case of an unusually located intracranial lipoma in a 17-year-old patient with partial epilepsy who was being controlled with medication. The lipoma was located deep in the left sylvian fissure, in the inferior parietal lobule, associated with cortical dysplasia of the surrounding supramarginal gyrus. Abnormal vasculature was detected adjacent to and within the adipose mass. The findings of the imaging studies that included CT, MR imaging, and MR angiography, are described along with a brief review of the literature.

Intracranial lipomas are rare lesions, assumed to be resulting from abnormal persistence and maldifferentiation of the meninx primitiva, as first proposed by Verga (1) and then supported by Truwit and Barkovich (2). The majority of the lesions occur at or near midline, mostly in the pericallosal cistern. Other locations include the quadrigeminal/superior cerebellar, suprasellar/interpeduncular, cerebellopontine angle, and sylvian cisterns. More than half the lesions are associated with brain malformations of varying degree (2). Lipomas on the cerebral surface, however, are extremely rare (3–7). We report an unusual case of intracranial lipoma located deep in the left sylvian fissure, in the inferior parietal lobule, associated with cortical dysplasia of the supramarginal gyrus and abnormal vasculature, as shown by CT, MR imaging, and MR angiography.

## Case Report

A 17-year-old male patient was admitted with a complaint of partial epilepsy that first started at the age of 3 years. During the previous 6 months, he had experienced an epileptic attack lasting a few minutes, with right-sided hemiparesis. The results of the physical and neurologic examinations performed at the time of admission were normal. The patient had been born after a normal-term pregnancy and uncomplicated delivery and had been healthy except for partial epilepsy that was controlled by medication.

Received January 20, 2000; accepted after revision April 19.

From the Hacettepe University Hospital, Departments of Radiology (I.S., C.A., A.B.) and Pediatric Neurology (Y.R.), Ankara, Turkey.

Address reprint requests to Isil Saatci, MD, Hacettepe University Hospital, Radiology Department, Sıhhiye 06100, Ankara, Turkey.

Unenhanced CT of the brain showed a hypodense mass in the left hemisphere, with attenuation characteristics of adipose tissue (–55 to –60 HU). There was no calcification or hemorrhage (Fig 1). The mass was surrounded by abnormally thick cortex. After the administration of contrast medium, there was no enhancement except for millimetric nodular enhancement lateral to the mass, extending for consecutive sections, consistent with a vascular structure. Based on the CT findings, the diagnosis of intracranial lipoma was established. For better evaluation of the associated cortical malformation, MR imaging was performed and revealed the extraaxial mass to be situated deep in the left sylvian fissure. The mass was hyperintense compared with brain on T1-weighted images (Fig 2A and B) and hypointense on standard T2-weighted spin-echo images (Fig 2C). It was also hyperintense on proton density-weighted, T1-weighted inversion-recovery, and turbo spin-echo T2-weighted images, confirming the diagnosis of lipoma. With the advantage of MR imaging evaluation in several planes, the lipoma was precisely located and the surrounding abnormal cortex was clearly seen. The inferior parietal lobule (the supramarginal gyrus in particular) was affected; the cortex was thickened with irregular margins within the white matter, and the sulcal pattern was abnormal. On spin-echo T2-weighted images, millimetric nodular signal void structures were identified in the lateral aspect of the lipoma (Fig 2C). No correspondent calcification was present on CT scans. Contrast-enhanced MR images showed an enhancing vascular structure extending from the mass to the hemispheric surface. MR angiography performed using the time-of-flight technique did not reveal much because of the superimposed intrinsically hyperintense mass. Phase-contrast MR angiography confirmed the presence of abnormal arterial branches originating from the middle cerebral artery (Fig 3). Also seen was an abnormally large vessel, possibly representing an enlarged drainage vein. Cerebral angiography was not performed because the patient's epilepsy was being controlled with medication and surgery was not considered at that time.

## Discussion

The most common site of intracranial lipomas is the callosal cistern, accounting for 50% of a large series reviewed by Maiuri et al (8). An off-midline location is a rare occurrence for lipomas, and the sylvian fissure is an uncommon location (2, 9–11), with an incidence of 3.4% in the series presented by Maiuri et al and 5% of the 44 intracranial lipomas reported by Truwit and Barkovich (2). Very rarely, lipomas may be encountered on the cerebral hemispheric surface (5–7). They are often associated with various anomalies of the CNS, such as agenesis/dysgenesis of the corpus callosum, absence of septum pellucidum, cranium bifidum, spina bifida, encephalocele, myelomeningocele, hy-

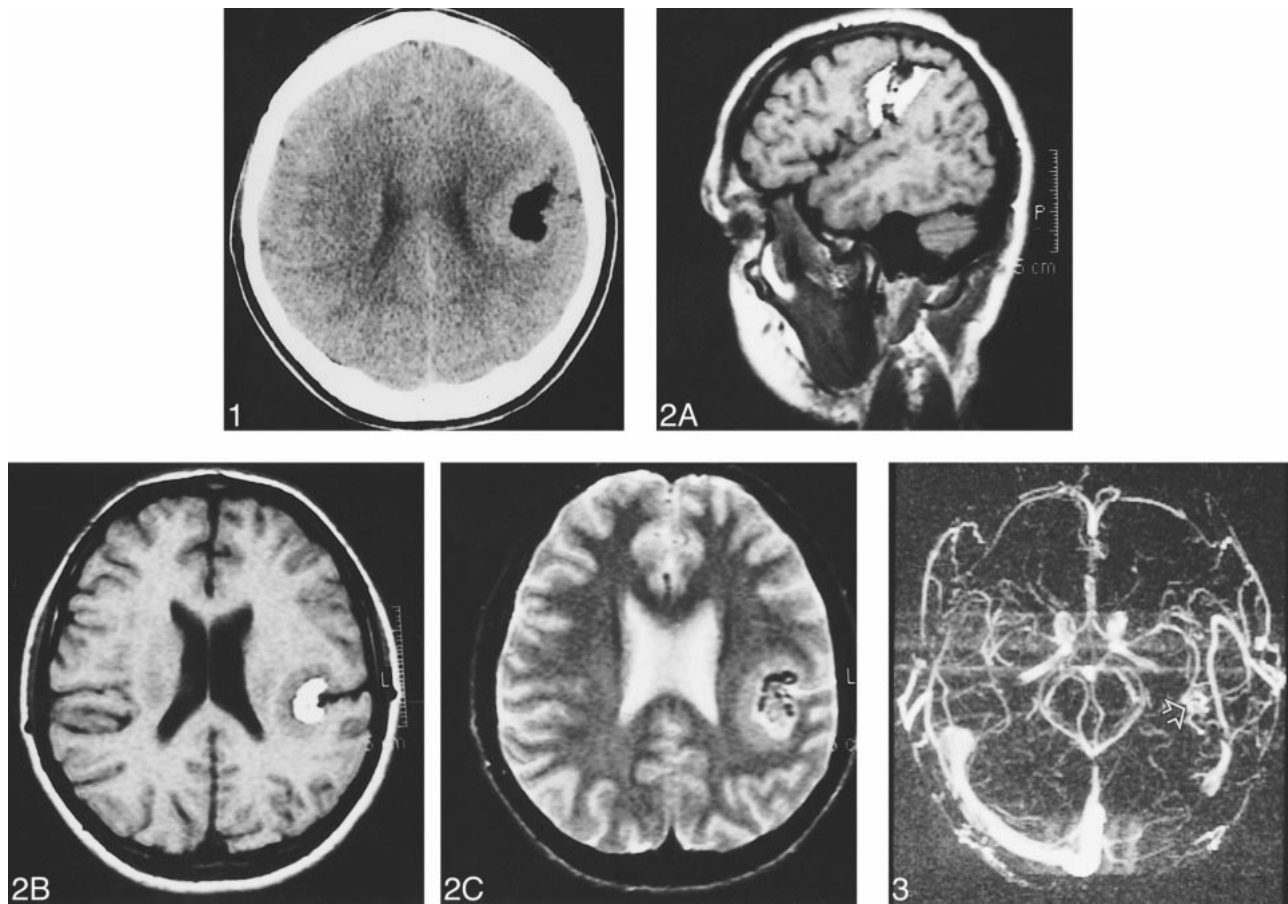


FIG 1. Unenhanced CT scan shows a very hypodense lesion located within a thickened layer of infolding cortex in the left hemisphere.

FIG 2. A, T1-weighted left parasagittal MR image shows a hyperintense mass deep in the sylvian fissure surrounded by abnormal cortex.

B, T1-weighted left axial MR image shows a hyperintense mass deep in the sylvian fissure surrounded by abnormal cortex.

C, Spin-echo T2-weighted MR image shows the hypointense mass within the infolded cortex. Note the low intensity tubular and rounded structures within the mass. Adjacent sulcus is extending deeper to the margin of the mass.

FIG 3. MR angiogram, obtained by using the phase-contrast technique, shows abnormal arterial branches originating from the middle cerebral artery on the left (open arrow).

poplasia of vermis, and malformation of the cortex (7).

In their most comprehensive report on the pathogenesis of the intracranial lipomas, Truwit and Barkovich (2) supported the postulations presented by Verga (1) of these lesions being congenital malformations resulting from abnormal persistence and maldifferentiation of meninx primitiva during the development of the subarachnoid cisterns. Sites of neural tube flexion are sites of redundant meninx primitiva so that lipoma may grow in the sylvian fissure. The sylvian fissure appears as a groove on the side of the primitive cerebral hemisphere after approximately 4 months of gestation, and the folding and growth of the surrounding tissues continue until the opercula completely cover the insula to meet in a line that is the definitive sylvian fissure. Therefore, the lipoma (*maldifferentiated subarachnoid space*, as described by Truwit and Barkovich) may interfere with the growth of cortical tissue during the ongoing formation of the sylvian fissure, resulting in cortical dysplasia in the vicinity.

Abnormal or prominent drainage has been described in association with cortical dysplasia (12). Abe et al (13) reported arterial vascular abnormality accompanying cerebral cortical dysplasia, although it is a rare occurrence. That particular case showed tortuous arteries in the opercular segments of the middle cerebral artery with an abnormal network in a patient with cortical dysplasia in the perisylvian region. The possibility that the overlying vasculopathy was caused by leptomeningeal damage during neuronal cell migration was suggested. The association of arterial abnormalities with intracranial lipomas, including aneurysms (fusiform or saccular), and arteriovenous malformations has also been reported (7, 14). Sasaki et al (7) presented the angiographic findings of a frontal lipoma, including dilation and tortuosity of the feeding arteries associated with tumor stain, hypovascularity of the surrounding areas, and dilated bridging veins draining the areas around the tumors. However, cortical dysplasia was accompanying the lipoma, as in our case, and it is not clear whether angiographic find-

ings represent features of tumoral vasculature or are related to the presence of cortical dysplasia. The authors suggest that the preexistence of the lipoma contributes to the formation of the focal cortical dysplasia because of physical interruption and focal perfusion insufficiency and that, therefore, angiographic findings represent tumoral vasculature. However, in the case of cortical dysplasia presented by Abe et al, similar angiographic findings (ie, dilated, abnormal arterial network with abnormal venous drainage) in the absence of accompanying lipoma imply that the mentioned findings do not represent abnormalities of lipoma but cortical dysplasia. Futami et al (14) proposed explanations for the presence of arterial abnormality that accompanies intracranial lipoma. The first explanation is that aneurysm may also occur because of congenital structural deficiency, sharing the same malformative origin with lipoma (ie, persistence and abnormal differentiation of the primitive meninx). The second explanation is that tumor might secrete some factors, weakening the arterial wall. Another explanation could be that lipoma itself degenerates the arterial wall as the presence of the lipoma interferes with the nutrition to the cerebral arterial wall incorporated within the tumor. This is based on the fact that cerebrovascular smooth muscle does not have vasa vasorum and receives its nutrition via diffusion from subarachnoid CSF.

In our case, abnormal arterial vasculature, as well as venous abnormality (Fig 3) accompanying the lipoma and the surrounding cortical dysplasia, was shown by MR angiography, with no evidence of aneurysm (although aneurysm cannot be totally ruled out based on MR angiographic results). It is not surprising to see middle cerebral artery branches coursing through the lipoma (2). The nature of the vascular structures within the mass may not be clearly identified using MR sections; however, MR angiography showed abnormal vasculature, more than just the normal middle cerebral artery branches coursing through the tumor. Also note that abnormal vasculature was obscured by the intrinsic hyperintensity of the lipoma on the MR angiogram obtained using the time-of-flight technique but was revealed by phase-contrast MR angiography. Also seen was an associated abnormal vein, which provided another example of abnormal drainage accompanying cortical dysplasia. Because surgical intervention was not considered, selective cerebral angiography was not justified. However, follow-up of the patient, possibly with MR angiography, is planned in consideration of the possibility of aneurysm formation.

In the majority of cases of intracranial lipoma, the most reported locations are in the pericallosal region or cerebellopontine angle. However, the risks of surgical intervention far outweigh the potential benefits (15, 16). One of the reasons is that attempts at complete extirpation will almost invariably result in neural or vascular damage due to strong attachment of tumor to surrounding struc-

tures. Furthermore, the majority of the tumors do not cause life-threatening symptoms. Therefore, it is questionable whether tumor removal is necessary. In our case, the seizures were well controlled with medication, except for infrequent attacks. This lessened the devastation to the quality of life for the patient. Therefore, surgical intervention was not considered, although it was mentioned to the patient as a therapeutic option.

To our knowledge, 12 cases of sylvian fissure lipoma (2, 5, 9–11, 14, 17) and five cases of cerebral surface lipoma, located off midline, all of which were sporadic case reports, had been reported (3–7) until the recent report presented by Bakshi et al (18). In contradiction to the previous reports, six cases of cerebral convexity lipoma comprised the second most common site in their series (19%). Additionally, they had two cases of sylvian lipomas. None of them had any associated cortical or vascular abnormality. However, the authors noted abnormal contrast enhancement of the meninges and associated intracranial hypotension in a patient with convexity lipoma, which had not been previously reported. However, three of the previously reported convexity lipomas were associated with cortical dysplasia. In 1936, Scherer (3) first found a left parietotemporooccipital convexity lipoma and polymicrogyria at autopsy. Britt et al (5) reported the first clinically diagnosed and operated case of a symptomatic left frontal lobe lipoma in an abnormally formed fissure and cortex. In 1996, Sasaki et al (7) presented a report of two lipomas located in an unusual fissure of the right frontal convexity and under the right frontal lobe associated with surrounding focal cortical dysplasia.

In conclusion, this case report is a reminder that intracranial lipomas may rarely be located in the cortical sulci, which may be associated with cortical dysplasia and abnormal vasculature. MR imaging and MR angiography using the phase-contrast technique provide the necessary information.

## References

1. Verga P. Lipoma ed osteolipomi della pia madre. *Tumori* 1929; 15:321–357
2. Truwit CL, Barkovich AJ. Pathogenesis of intracranial lipoma: an MR study in 42 patients. *AJR Am J Roentgenol* 1990;155: 855–865
3. Scherer E. Über die pialen Lipome des Gehirns: Beitrag eines Falles von ausgedehnter meningealer Lipomatose einer Grosshirnhemisphäre bei Mikrogryrie. *Z Ges Neurol* 1936;154:45–61
4. Demuse H. Neue Gesichtspunkte zur Entstehung der pialen lipome. *Arch Psychiat Nervenkr* 1967;209:426–442
5. Britt PM, Bindal AK, Balko MG, Yeh HS. Lipoma of the cerebral cortex: Case Report. *Acta Neurochir (Wien)* 1993;121:88–92
6. Fujii Y, Konishi Y, Kriyama M, Hori C, Sudo M. Lipoma on surface of centroparietal lobes. *Pediatr Neurol* 1993;9:144–146
7. Sasaki H, Yoshida K, Wakamoto H, Otani M, Toya S. Lipomas of the frontal lobe. *Clin Neurol Neurosurg* 1996;98:27–31
8. Maiuri F, Cirillo S, Simonetti L, De Simone MR, Gangemi M. Intracranial lipomas: diagnostic and therapeutic considerations. *J Neurosurg Sci* 1988;32:161–167
9. Dyck P. Sylvian lipoma causing auditory hallucinations: case report. *Neurosurgery* 1985;16:64–67
10. Hatashita S, Sakakibara T, Ischii S. Lipoma of the insula: case report. *J Neurosurg* 1983;58:300–302

11. Maiuri F, Cirillo S, Simonetti L. **Lipoma of the sylvian region.** *Clin Neurol Neurosurg* 1989;91:321–323
12. Barkovich AJ. **Abnormal vascular drainage in anomalies of neuronal migration.** *AJNR Am J Neuroradiol* 1988;9:939–942
13. Abe T, Singer RJ, Marks MP, et al. **Arterial vascular abnormality accompanying cerebral cortical dysplasia.** *AJNR Am J Neuroradiol* 1997;18:144–146
14. Futami K, Kimura A, Yamashita J. **Intracranial lipoma associated with cerebral saccular aneurysm: case report.** *J Neurosurg* 1992;77:640–642
15. Kazner E, Stochdorph O, Wende S, Grumme T. **Intracranial lipoma: diagnostic and therapeutic considerations.** *J Neurosurg* 1980;52:234–245
16. Eghwudjakpor PO, Kurisaka M, Fukuoka M, Mori K. **Intracranial lipomas: current perspectives in their diagnosis and treatment.** *Br J Neurosurg* 1992;6:139–144
17. Hadecke J, Buchfelder M, Triebel HJ, Schneyer U. **Multiple intracranial lipoma: a case report.** *Neurosurg Rev* 1997;20:282–287
18. Bakshi R, Shaikh ZA, Kamran S, Kinkel PR. **MRI findings in 32 consecutive lipomas using conventional and advanced sequences.** *J Neuroimaging* 1999;9:134–140