



**Providing Choice & Value**  
Generic CT and MRI Contrast Agents

**FRESENIUS  
KABI**

**CONTACT REP**

**AJNR**

## **Cutaneous Emphysema and Craniocervical Bone Pneumatization**

Bernard Turowski, Juergen Rettig, Peter Raab and  
Friedhelm E. Zanella

*AJNR Am J Neuroradiol* 2001, 22 (7) 1398-1400  
<http://www.ajnr.org/content/22/7/1398>

This information is current as  
of July 29, 2025.

## Case Report

# Cutaneous Emphysema and Craniocervical Bone Pneumatization

Bernard Turowski, Juergen Rettig, Peter Raab, and Friedhelm E. Zanella

**Summary:** We report a case of pneumatization of the upper cervical spine and the craniocervical junction, including the occipital bone, accompanied by extensive soft tissue emphysema. There was no history of trauma or surgery. Follow-up X-ray and CT demonstrated the development of those changes. A combination of a developmental abnormality and the unusual habit of frequent Valsalva's maneuvers may have led to those findings. Clinical consequences will be discussed.

The air cells of the temporal bone develop as out-pouchings from the tympanic cavity, epitympanon, antrum, and eustachian tube (1). Epithelium-lined soft tissue projects between the spicules of forming bone and the marrow dedifferentiates into loose connective tissue, which is then invaded by pneumatic pockets (2). Subepithelial bone resorption further enlarges the air cells, but apparently only in the presence of air (3). Pneumatization begins late in fetal life, accelerates at birth, and continues through infancy, early childhood, and occasionally early adult life. The extent and pattern of pneumatization vary greatly among individuals, with a tendency toward symmetry in a given individual. Pneumatization of the occipital bone is rare and, to our knowledge, has only been reported three times before (1, 4–6). In two of the three cases (1, 4) there was a pneumatization of both the occiput and the atlas. It has been postulated that in these instances, a communication between the temporal bone, occiput, and atlas must be present. The third case described an intraosseous pneumatocyst in a vertebral body of unknown etiology (7).

## Case Report

A 38-year-old man presented with a moderate swelling and pain in the dorsal neck. Three weeks before, he felt pain and swelling in his neck for the first time after working in his garden. For many years, the patient had performed Valsalva's maneuver once per hour because of problems with his eustachian tube. He kept that habit, including the time when he

became symptomatic, but the onset of pain was not closely linked to Valsalva's maneuver.

During clinical examination, a swelling below the occipital bone and surrounding soft tissue emphysema were found. Neurologic examination results were normal. The patient denied experiencing headaches.

Plain-film X-rays showed structural changes in the spongiosa of the first three vertebral bodies, with increased radiolucency. There was a large bubble of gas within the nuchal soft tissue and muscle fibers were delineated by emphysema.

X-rays taken 5 years before showed similar bony changes in only the first and second cervical vertebra, with small gas inclusions in the soft tissue. This follow-up demonstrates the impressive progression of these changes in the bone and in the soft tissue.

MR imaging revealed a complete loss of normal bone marrow signal within those vertebral bodies, including the arch of the first and second cervical vertebra. In addition to these changes, there was a large, sharply bordered mass within the nuchal soft tissue corresponding to the previously described gas bubble.

Mastoidal pneumatization with extension into the occipital bone close to the foramen magnum was found on CT scanning (Fig 1). On more caudal slices, pneumatization of the second (Fig 2A) and third vertebral bodies were shown.

There were no therapeutic consequences. An otolaryngeal examination revealed no pathologic abnormalities. There was normal hearing and no sign of inflammation. Because of the problems with the eustachian tube, tympanic drainage was performed. The patient was discharged with the recommendation to reduce the frequency of Valsalva's maneuvers. Follow-up CT scanning performed 4 months later showed regression of the bone pneumatization (Fig 2B).

## Discussion

The presented case is an example of atypical pneumatization of the occiput and the first three cervical vertebra. Furthermore, there was an extensive craniocervical and nuchal soft tissue emphysema. The recent examination showed impressive progression of the bony changes and the soft tissue emphysema compared with X-rays obtained 5 years before.

It can be suggested that the emphysema itself was caused by a microtraumatic rupture of an occipital air cell during repeated Valsalva's maneuvers. The pain was probably not caused by the initial rupture of an air-filled space, but by the increasing extent of gas accumulating after the rupture, producing increasing pressure within the tissue. The extended craniocervical pneumatization crossing bony borders is still difficult to explain.

It has been postulated that occipital pneumatization is a consequence of communication between

Received December 13, 2000; accepted February 9, 2001.

From the Institute of Neuroradiology (B.T., P.R., F.E.Z.) and the Clinic of Neurosurgery (J.R.), University of Frankfurt, Frankfurt, Germany.

Address reprint requests to Bernd Turowski, MD, Institut für Neuroradiologie, Johann Wolfgang Goethe-Universität, Schleusenweg 2-16, 60528 Frankfurt am Main, Germany.

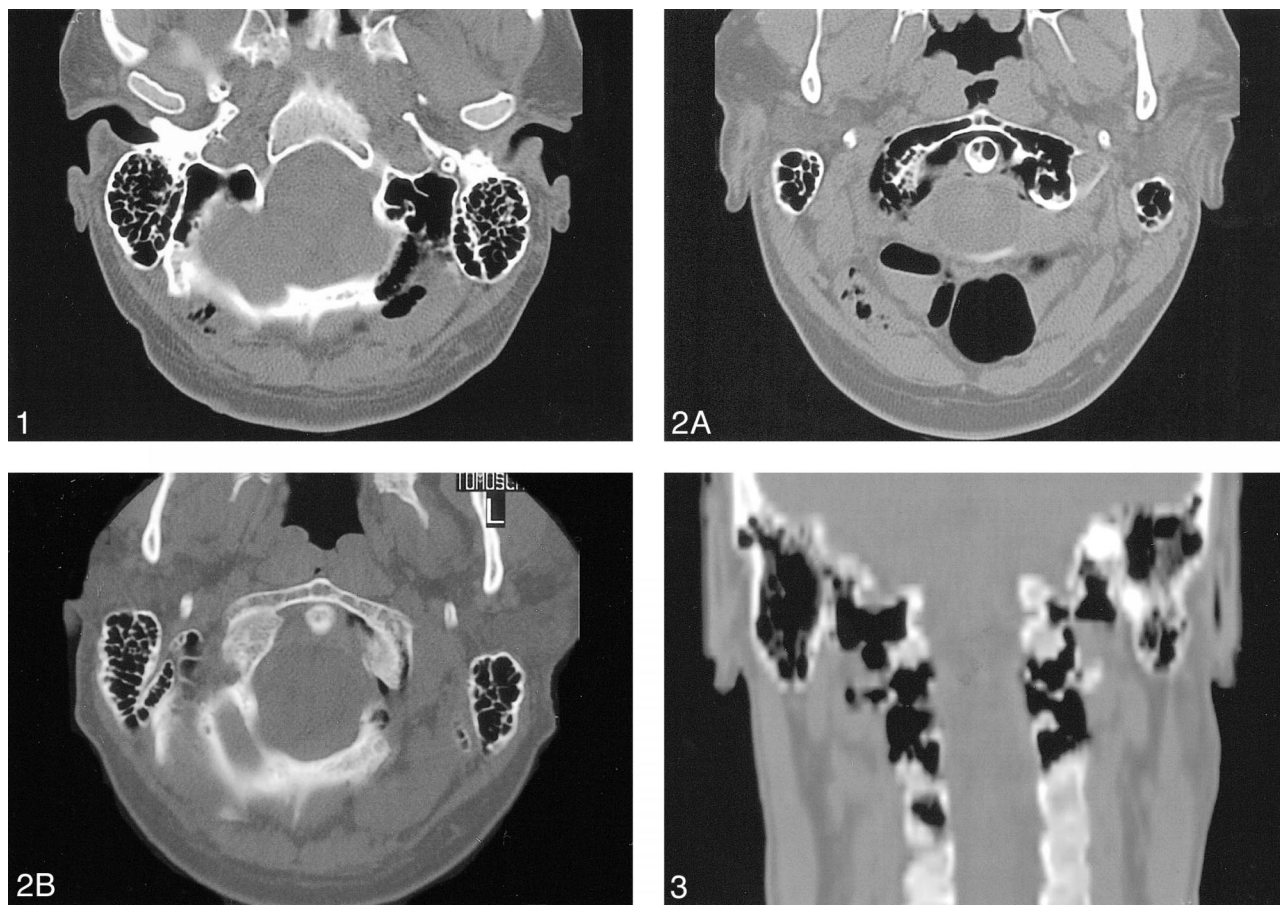


FIG 1. CT of the occipital bone demonstrates extension of mastoid pneumatization to the occipital bone.

FIG 2. CT follow-up shows pneumatization of the second vertebra and surrounding soft tissue emphysema at first presentation (A) and regression of those changes and only small residual soft tissue emphysema four months later (B).

FIG 3. Coronal reconstruction of CT suggests connections between the aerated bony structures of the occiput and the first three vertebral bodies.

the temporal and occipital bones. Atlanto-occipital assimilation as a developmental abnormality could explain pneumatization of the atlas by extension from the temporal and occipital bones (4). Sadler et al (4) described in their case report an apparent communication between the occipital condyle and the atlas air cells, best seen on CT coronal reconstructions.

In our case, there also seemed to be a communication between all of the involved bony structures, as demonstrated in the CT coronal reconstructions (Fig 3). In addition to communication in areas of close bony contact, eg, articulations, a communication via gas-filled spaces in the soft tissue could be possible. In the presented case, the findings of occipito-cervical bone pneumatization, including the first three vertebrae, are much more extensive than in the three previously described cases.

Finally, there may have been a communication between all involved bony structures. Regarding the large extent of the changes including three cervical vertebrae, an alternative explanation of pneu-

matization occurring independently in separate bones, eg, pneumatocysts, seems less probable. Intraosseous pneumatocysts with unknown etiology are described only in a single vertebral body (7). Follow-up imaging showing progressive pneumatization could be an argument for the theory of expanding communicating spaces.

In addition to the etiology of the described changes, the clinical aspect of that extensive pneumatization should be taken into account. In our case, the patient was very active in different sports, eg, skiing. In spite of some accidents in former years, there was never a fracture or any problem concerning the craniocervical junction. Our patient's long history without craniocervical complications argues against an aggressive intervention, ie, external fixation, as discussed by Sadler et al (4).

We found it very interesting that the pneumatization in the second and third vertebral bodies regressed 4 months after the first presentation of the patient in our clinics (Fig 2B). Treatment of the malfunction of the eustachian tube by tympanic drainage and the reduction of frequency

of Valsalva's maneuvers may have led to this effect.

### References

1. Lo WWM, Zapanta E. **Pneumatization of the occipital bone as a cause of radiolucent skull lesions.** *AJNR Am J Neuroradiol* 1983;4:1249-1250
2. Shambaugh GE, Glasscock ME. *Surgery of the Ear*. 3rd ed. Philadelphia: Saunders;1980:24-25
3. Beaumont GD. **The effects of exclusion of air from pneumatized bone.** *J Laryngol Otol* 1966;80:236-249
4. Sadler DJ, Doyle GJ, Hall K, Crawford PJ. **Craniocervical bone pneumatisation.** *Neuroradiology* 1996;38:330-332
5. Hogg DA. **The developement of pneumatisation in the postcranial skeleton of the domestic fowl.** *J Anat* 1984;139:105-113
6. Sener RN. **Air sinus in the occipital bone.** *AJR Am J Roentgenol* 1992;159:905
7. Laufer L, Schulman H, Hertzanu Y. **Vertebral pneumatocyst. A case report.** *Spine* 1996;21:389-391