

Generic Contrast Agents

Our portfolio is growing to serve you better. Now you have a *choice*.



[VIEW CATALOG](#)

AJNR

Treatment of Iatrogenic Internal Carotid Artery Laceration and Carotid Cavernous Fistula with Endovascular Stent-Graft Placement

Naci Kocer, Osman Kizilkilic, Sait Albayram, Ibrahim Adaletli, Fatih Kantarci and Civan Islak

This information is current as of May 21, 2025.

AJNR Am J Neuroradiol 2002, 23 (3) 442-446

<http://www.ajnr.org/content/23/3/442>

Case Report

Treatment of Iatrogenic Internal Carotid Artery Laceration and Carotid Cavernous Fistula with Endovascular Stent-Graft Placement

Naci Kocer, Osman Kizilkilic, Sait Albayram, Ibrahim Adaletli, Fatih Kantarci, and Civan Islak

Summary: The risk of fatal injury of the internal carotid artery (ICA) and surrounding anatomy during transsphenoidal surgery for pituitary adenoma is the most severe potential complication associated with this particular approach. We present a case in which iatrogenic injury to a patient's ICA and resultant carotid cavernous fistula and massive hemorrhage was successfully managed with the emergency placement of an endovascular stent-graft. Both findings in the relevant literature and practical considerations concerning both stent-grafts and other more commonly used options for the treatment of iatrogenic ICA injury are discussed.

Although experience and thorough knowledge of the relevant anatomy can prevent many potential complications associated with transsphenoidal surgery (TSS), the risk of arterial injury cannot be completely eliminated, especially given the large number of such procedures performed and the complexity of certain cases. The most serious complication of TSS is injury and/or laceration of the internal carotid artery (ICA). The presentation of this potentially fatal complication includes severe peri- or postoperative bleeding and a false aneurysm of the ICA and carotid cavernous fistula (CCF) (1). Immediate diagnosis and treatment of these symptoms is essential to prevent a fatal complication.

Traditionally, emergency surgical ligation has been used to treat ICA injury. This treatment itself, however, is associated with an unacceptable incidence of major complications, such as death and stroke (1–3), and it is often an ineffective or even harmful treatment for ICA injury. Recent advances in endovascular techniques have, however, created alternatives to this traditionally high-risk technique (2). We present findings from our successful experience with one such endovascular alternative: the placement of a stent-graft to resolve massive ICA hemorrhage and CCF resulting from iatrogenic injury of the ICA.

Case Report

A 58-year-old woman was admitted to an outside institution for the treatment of long-standing galactorrhea. MR imaging revealed a microadenoma in the pituitary gland. Transsphenoidal resection with unilateral submucosal septal dissection was proposed and performed with lateral fluoroscopic control at an outside institution. The sphenoid sinus mucosa was exenterated, and a rectangular window was made in the sellar floor. The surgeon then made an incision into what was presumed to be the adenoma; however, this resulted in profuse bleeding, and injury to the cavernous segment of the right ICA was suspected. The surgeon attempted to control the bleeding with local packing, but this measure was not completely successful. A continuous nasal hemorrhage developed, and the operation was stopped. At this point, the patient was transferred to our institution for diagnosis and potential endovascular treatment for arterial injury.

Standard cerebral angiography was performed with general anaesthesia by using a unilateral femoral approach. This examination revealed contrast material extravasation into the sphenoid sinus resulting from a laceration in the cavernous segment of the right ICA and a high-flow CCF with some retrograde cortical venous drainage (Fig 1A and B). Detachable balloon embolization was initially proposed; however, selective left ICA injection with external compression of the right common carotid artery resulted in a prominent delay (6-s delay) in the arterial, parenchymal, and venous phases in the right hemisphere (Fig 1C and D). Since the collateral circulation was not sufficient for balloon occlusion, we decided to attempt coronary stent-graft placement to treat the injury. A microcatheter (Rapid Transit-21; Cordis, Miami, FL) was passed through the injured segment of the ICA by using an angled guidewire (Terumo-16; Terumo, Tokyo, Japan). The microcatheter was then replaced with a 0.014-in exchange guidewire (Luge; Boston Scientific, Maple Grove, MN), and a Jostent coronary stent-graft (4 × 12 mm; Jomed International, Helsingborg, Sweden) was hand mounted onto a coronary angioplasty balloon (4-mm balloon diameter, 20-mm balloon length; Freeway, Jomed International). The Jostent covered stent-graft consisted of an ultrathin (75-μm) polytetrafluoroethylene graft material layered between two stents with reduced wall thickness. (The “CE” mark on this device certifies the manufacturer's confirmation that the device satisfies both German and European safety and/or quality requirements.) The stent-graft and balloon were advanced to the injured segment of the ICA over the exchange guidewire that had been advanced into the right supraclinoid ICA (Fig 2A). The loaded balloon catheter was positioned at the level of the ICA injury. After a control angiogram was obtained, the stent-graft was inflated to 8 atm. The balloon was then deflated while negative pressure was applied, and the balloon was removed (Fig 2B). A repeat diagnostic arteriogram showed total closure of the lacerated portions of the ICA and CCF. Two spasmodic areas—one distal to the stent-graft and one at the cervical portion of the ICA—were noted (Fig 2C). These were assumed to be associated with irritation resulting from the advancement of the

Received July 27, 2001; accepted after revision October 8.

From the Division of Neuroradiology, Department of Radiology, Cerrahpasa Medical School, Istanbul, Turkey.

Address reprint requests to Naci Kocer, MD, Department of Radiology, Division of Neuroradiology, the Cerrahpasa Medical School, 34300 Kocamustafapasa, Istanbul, Turkey.

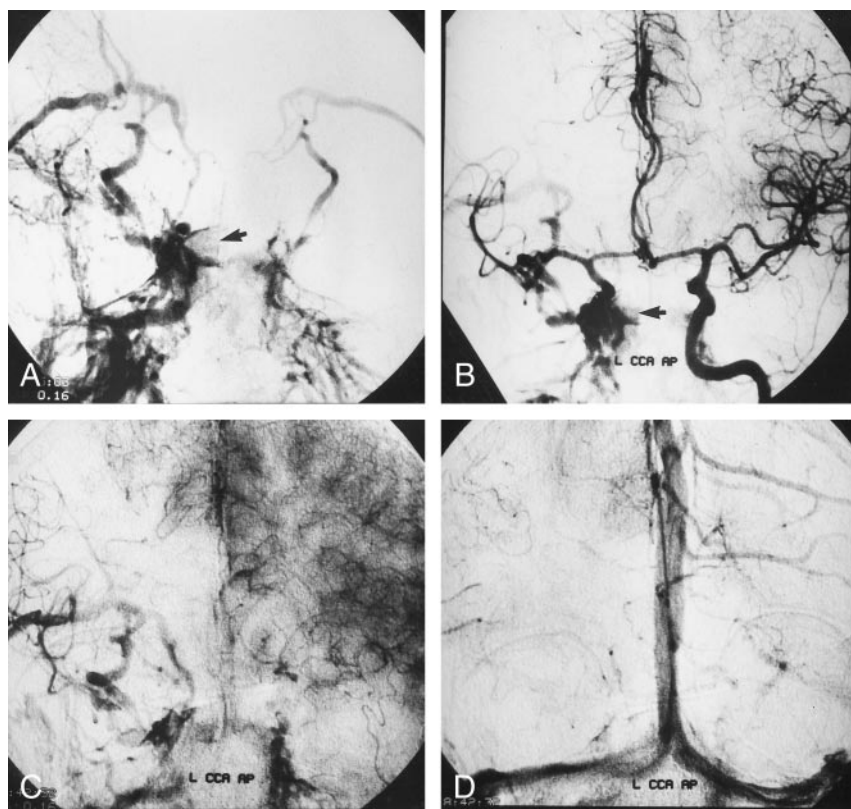


FIG 1. Angiograms obtained with external compression of the right CCA in a 58-year-old woman with iatrogenic right ICA injury associated with TSS.

A and B, Right (A) and left (B) CCA angiograms, anteroposterior projections, reveal contrast material extravasation within the sphenoid sinus (arrow) and show a high-flow CCF draining toward the superior ophthalmic vein, pterygoid plexus, and petrosal sinuses.

C and D, Left CCA angiograms reveal prominent circulation delays in the capillary (C) and venous (D) phases on the right side in comparison with the left side.

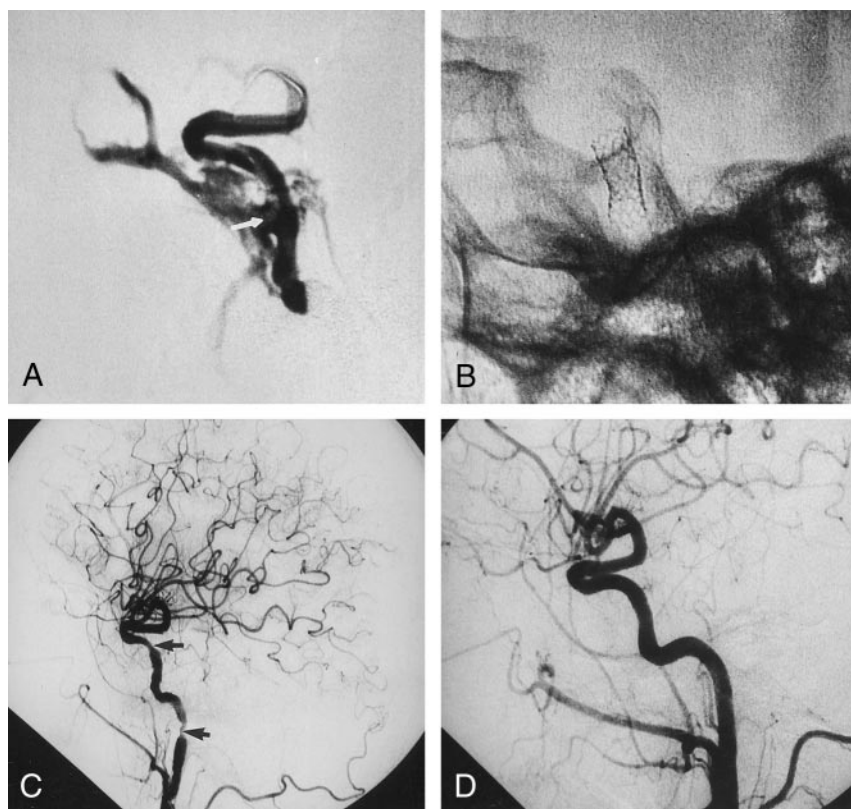


FIG 2. Coronary stent-graft placement to treat an iatrogenic ICA injury.

A, Contrast material injection from the guiding catheter reveals the lacerated segment of the right ICA (arrow) on this angiogram. Note that the stent-graft and microguidewire are in the ICA lumen during the injection.

B, Fluoroscopic image obtained after removal of the microballoon and microguidewire shows the expanded stent-graft in the lacerated ICA.

C, Postprocedural right CCA angiogram obtained after deployment of stent-graft reveals cessation of contrast material extravasation and closure of the CCF. Note the focal transient spasm distal to the stent-graft and at the subpetrous portion of cervical ICA (arrows).

D, Right CCA angiogram obtained 3 mo after the procedure demonstrates patency of the ICA, with no contour irregularity.

stent. Because spasm could have compromised the flow, 100 mg of a mixture of papaverine and isotonic sodium chloride solution was administered by means of manual injection. Upon completion of the procedure, the nasal hemorrhage ceased,

and the patient was transferred to the intensive care unit. Follow-up arteriograms, obtained 3 mo after the patient was discharged, showed absent filling of the CCF, with normal patency of the ICA. The follow-up angiographic study showed

no evidence of intimal hyperplasia or concomitant vessel stenosis (Fig 2D).

Discussion

Hemorrhage resulting from the injury of the ICA is one of the most severe complications associated with TSS for pituitary lesions (1). Although it is commonly believed that this complication occurs infrequently, reports in the recent literature suggests otherwise. Responses to a survey conducted by Ciric et al (4) suggest that the incidence of this complication is higher than previously thought: Of 958 neurosurgeons who responded, 12% reported that they had caused injury to the ICA during TSS. Incidences of CCF, false aneurysm, and carotid occlusion were also documented in this survey. Raymond et al (1) reported that arterial injuries during or after TSS occurred in about 1% of cases and that they were associated with notable morbidity (24%) and mortality (14%).

Certain factors associated with the size, shape, and location of the pituitary adenoma predisposes the patient to surgical arterial injury. When the adenoma is large or invasive or when it is in close lateral proximity (even when it is small) to the cavernous sinus and cavernous segment of the carotid artery, arterial injury is more likely to occur (3). Hemorrhagic complications also are more likely to occur in patients whose medical history includes either previous TSS or radiation therapy (3).

Anatomic variations in the carotid arteries and surrounding anatomy may also predispose the patient to arterial injury during TSS. Right and left carotid arteries that are located within the sella and relatively close to each other pose a risk for injury during TSS; in some patients, the distance between the left and right carotid arteries may be as short as 4 mm (5). Variations in the structure of the sphenoid sinus, such as a honeycomb configuration or an opacified sphenoid sinus, may also complicate TSS (3). If any such variations in the carotid arteries or surrounding anatomy are suspected in a patient who is scheduled to undergo TSS, the patient's individual anatomy must be thoroughly assessed before surgery. MR angiography or digital subtraction angiography may be used for this task, especially in patients in whom an aneurysm in the cavernous sinus or sella is suspected.

Angiographic findings of iatrogenic ICA injury after TSS may include the following: contrast material extravasation within the sphenoid sinus, carotid artery occlusion and/or stenosis, false aneurysm in the carotid artery, and CCF (1). CCF is a rare complication associated with TSS, and it is reported infrequently in the literature (6, 7). In their study of 1800 patients undergoing TSS for pituitary adenomas, Raymond et al (1) reported 23 arterial injuries; however, none resulted in CCF. Carotid artery injury occurs most frequently a few millimeters below the origin of the ophthalmic artery (1), and in patients with ipsilateral carotid artery stenosis, anterior or middle cerebral

artery occlusion resulting from emboli may also be revealed at angiography.

Iatrogenic ICA injury may create a communicating channel between the sphenoid and/or cavernous sinus and the sidewall of ICA. Such an event may present as an acute hemorrhage, false aneurysm, or CCF. If the fissure communicates with only the cavernous sinus, the result is a CCF. Ongoing hemorrhage and false aneurysm occur when the fissure communicates with only the sphenoid sinus. As was the case with our patient, injury to the ICA resulted in communication with both the sphenoid and cavernous sinuses, which led to hemorrhage, false aneurysm, and CCF. Recognizing and distinguishing between these three entities are essential for successful endovascular treatment of ICA injury. CCF is the only type of arterial injury for which treatment with detachable balloons or coils is appropriate. In this situation, the parent artery will most likely be preserved, and this injury is somewhat less urgent than other arterial injuries. Preserving the parent artery through the use of detachable balloons or coils is not possible in the case of a false aneurysm in the sphenoid sinus, and treatment of this particular injury is urgent.

Despite the well-documented risk of cerebral ischemia and the resultant neurologic morbidity and mortality associated with traditional methods of emergency surgical occlusion without diagnostic testing, for a long time these methods have been the only therapeutic option for ICA injury during or after TSS. Over the past several years, however, therapeutic endovascular techniques for ICA occlusion have been developed for the treatment of ICA injury. Such techniques are simple, and they can be performed immediately after the diagnostic angiographic study; the detachable balloon technique is well established, and it has been used for many years. The results of controlled endovascular occlusion are more predictable than those of intraoperative occlusion, and controlled occlusion allows for balloon test occlusion of the carotid artery, which minimizes the risk of ischemic complications.

Urgent diagnosis and treatment of an iatrogenic injury of the ICA is essential, as any delay may result in the patient's death. Despite its advantages, emergent endovascular occlusion is by no means risk-free. Although expedient treatment is of paramount importance, all treatment options should be thoroughly considered and discussed before a treatment decision is made. If severe hemorrhage occurs during TSS, intraoperative packing is the first and often only immediate step that can be taken. If the bleeding is totally controlled, postoperative angiography should be performed. If the findings are negative, angiography should be repeated after the packing is removed. When packing completely fails to control the hemorrhage, the situation is acutely life threatening, and surgical occlusion of the ICA must be performed immediately. If intraoperative packing partially controls the hemorrhage and if a subsequent angiography reveals a lacerated ICA, occlusion of the ICA must

then be performed with either surgical or endovascular means.

Surgical closure of the ICA is not frequently chosen as an option because of the well-documented risk of cerebral ischemia and associated major neurologic morbidity and mortality (2). An additional drawback of the surgical method is the lack of angiographic data that show the exact site and type of arterial injury. Because of these disadvantages, the endovascular approach with balloon occlusion has become the preferred treatment for carotid artery injury associated with TSS.

Before endovascular occlusion, a test balloon occlusion should be performed. If the patient tolerates the test, endovascular permanent balloon occlusion can be performed. About 75% of patients safely tolerate occlusion of ICA without neurologic deficit (8). However, a small subset of patients has ischemic complications despite negative findings with the test occlusion (2).

The treatment of patients in whom the initial balloon test occlusion fails (as determined with either clinical or cerebral blood-flow imaging) is challenging, and such patients are candidates for some form of surgical bypass. Skull-base bypass surgery may be attempted with a saphenous vein bypass or an external carotid artery and/or middle cerebral artery bypass (1, 9, 10). However, bypass surgery is not without risk, especially in patients with severe hemorrhage. Also, patients with ICA injury may be hemodynamically unstable, a factor that further complicates perioperative treatment with surgical bypass (1, 9, 10). In addition, the value of bypass surgery in preventing ischemic complications remains controversial, and these operations are much longer than any endovascular procedure (1, 9, 10). All of these factors cast doubt on whether the potential benefit of surgical bypass outweigh the risks. Nonetheless, surgical bypass is considered in some patients because other surgical or endovascular methods are eliminated as potential treatment options. To successfully treat such patients, a different method must be explored.

Within the last decade, transluminal placement of endovascular stent-grafts has evolved as a promising alternative to most surgical repair techniques. Transluminal endovascular placement of stent-grafts within the aorta, peripheral, visceral, and coronary arteries have been reported as safe and effective alternatives to surgery (10–12). Thus far, the literature includes reports of the successful use of this type of stent to treat percutaneously inaccessible anomalies such as fistulas, aneurysms, and coronary ruptures (12, 13). A few reports document the use of stent-grafts in the supraaortic arteries (14–16). Macdonald et al (10) recently reported their successful use of a cover stent in the treatment of acute carotid blowout syndrome. These reports suggest that the use of stent-grafts could be the easiest and most efficient way to preserve a parent artery; they allow immediate exclusion of the possibility of a pseudoaneurysm, preservation of the carotid artery, cessation of hemorrhage, and

rapid (within 15 min in our case) stabilization of the patient's condition.

On the basis of these reports, we attempted a new technique for treating iatrogenic ICA injury associated with TSS. Packing could not control our patient's sphenoid sinus hemorrhage, and although balloon occlusion of the ICA at the site of injury was technically possible, the patient's ability to tolerate the procedure was in doubt. We did not consider coil occlusion because the arterial injury extended into the sphenoid sinus. Because of the continuous hemorrhage, emergency stent-graft placement was proposed. An additional benefit associated with the use of this treatment in our case was the low risk of stroke with, as compared with that of balloon occlusion; the patient's angiographic examination had revealed a 6-s venous delay, which indicated that she had a particularly high risk for stroke. The placement of the stent-graft was successful in treating our patient's massive hemorrhage and high-flow CCF.

The main technical limitation associated with the placement of stent-grafts within the ICA is the limited longitudinal flexibility of the stent-graft. Adapting a semirigid stent-graft designed for coronary use to the curves of the ICA is somewhat difficult. In our patient, we believe that incompatibility of the stent with the shape of the carotid artery was the cause of the arterial spasm that we detected when the stent was advanced into the proximal portion of the ICA. However, arterial spasms can be successfully managed with the injection of papaverine into the ICA, and interventionalists should be aware of this. We hypothesize that the use of a stent that is too large or too rigid to conform to the shape of the ICA can also cause arterial dissection and rupture; however, future technical developments are likely to improve stent-graft designs and offer more sophisticated delivery systems that address the current limitations of stent-grafts that are used intracranially.

Although many treatment options for acute hemorrhage associated with TSS have intermediate or long-term risks of neurologic deficit or stroke, these concerns must become secondary in a potentially fatal situation in which time is of paramount importance. A recent global survey revealed that patients have a 4.4% risk stroke within 30 d after carotid stent placement (17); however, we are not aware of any data that specifically documenting the long-term results and the risk of stroke associated with stent-graft placement within the ICA or supraaortic arteries. We hypothesize that the risk of neurologic damage with the use of a covered stent to preserve the parent vessel and prevent arterial injury is smaller than that of parent vessel occlusion in patients who could not tolerate the balloon occlusion test.

Polytetrafluoroethylene has been used for many years as a graft material during vascular surgery. Polytetrafluoroethylene-covered stents effective in a variety of clinical settings, with an acceptably low incidence of complications, including acute stent thrombosis (18). Use of these stents is the therapy of choice for acute coronary rupture, because a procedure such as

this can replace other high-risk emergency operations that were previously the only treatment options (18). Some have suggested that the microporous nature of the polytetrafluoroethylene layer could reduce the rate of stent-related coronary stenosis by inhibiting plaque protrusion and migration of inflammatory cells and by attenuating the diffusion of cytokines. Also, neointimal proliferation has been reported to occur predominantly at the edges that are not covered by the membrane (19, 20). However, available data about restenosis rates are limited because of the small number of patients treated with coronary stents who are followed-up after their procedures.

Conclusion

We present the possibility of using endovascular stent-grafts for the treatment of iatrogenic ICA laceration—a use not previously mentioned in the literature. In our case, the use of stent-grafts proved expedient, safe, and effective in the emergency treatment of a massive hemorrhage resulting from ICA injury that occurred during TSS. If the patient's ability to tolerate balloon occlusion after ICA injury is in doubt, the stent-graft option represents a viable low-risk alternative that, unlike other treatment options, substantially reduces the risk of stroke. The long-term patency of stent-graft placement for the treatment of iatrogenic ICA injury is still unknown; however, we expect an overall positive outcome from our initial experience. In addition, future technical developments will most likely improve stent-grafts designs and offer more sophisticated delivery systems that address some of the current limitations.

Acknowledgment

We are grateful to Mr Cenk Acar from Formed, Turkey, for his technical assistance.

References

1. Raymond J, Hardy J, Czepko R, Roy D. **Arterial injuries in trans-sphenoidal surgery for pituitary adenoma; the role of angiography and endovascular treatment.** *AJNR Am J Neuroradiol* 1997;18:655–665
2. Chaloupka JC, Putman CM, Citardi MJ, Ross DA, Sasaki CT. **Endovascular therapy for the carotid blowout syndrome in head and neck surgical patients: diagnostic and managerial considerations.** *AJNR Am J Neuroradiol* 1996;17:843–852
3. Hardy J, McCutcheon IE. **Pituitary microadenomas.** In: Apuzzo MLJ, ed. *Brain Surgery: Complications Avoidance and Management.* New York, NY: Churchill Livingstone; 1992;33–122
4. Ciric I, Ragin A, Baumgartner C, Pierce D. **Complications of transsphenoidal surgery: results of a national survey, review of the literature, and personal experience.** *Neurosurgery* 1997;40:225–236
5. Lee KJ. **The sublabial transsphenoidal approach to the hypophysis.** *Laryngoscope* 1978;88:1–65
6. Pigott TJ, Holland IM, Punt JA. **Carotico-cavernous fistula after trans-sphenoidal hypophysectomy.** *Br J Neurosurg* 1989;3:613–616
7. Ahuja A, Guterman LR, Hopkins LN. **Carotid cavernous fistula and false aneurysm of the cavernous carotid artery: complications of transsphenoidal surgery.** *Neurosurgery* 1992;31:774–778
8. Linskey ME, Sekhar LN, Horton JA, Hirsch WL Jr, Yonas H. **Aneurysms of the intracavernous carotid artery: a multidisciplinary approach to treatment.** *J Neurosurg* 1991;75:525–534
9. The EC/IC Bypass Study Group. **Failure of extracranial-intracranial arterial bypass to reduce the risk of ischemic stroke: results of an international randomized trial.** *N Engl J Med* 1985;313:1191–1200
10. Macdonald S, Gan J, McKay AJ, Edwards RD. **Endovascular treatment of acute carotid blow-out syndrome.** *J Vasc Interv Radiol* 2000;11:1184–1188
11. Parodi JC. **Endovascular repair of abdominal aortic aneurysms and other arterial lesions.** *J Vasc Surg* 1995;21:549–555
12. Elsner M, Auch-Schwelk W, Britten M, Walter DH, Schachinger V, Zeiher AM. **Coronary stent grafts covered by a polytetrafluoroethylene membrane.** *Am J Cardiol* 1999;84:335–338
13. Roongsritong C, Laothavorn P, Sanguanwong S. **Stent grafting for coronary arteriovenous fistula with adjacent atherosclerotic plaque in a patient with myocardial infarction.** *J Invasive Cardiol* 2000;12:283–285
14. Marotta TR, Buller C, Taylor D, Morris C, Zwimpfer T. **Autologous vein-covered stent repair of a cervical internal carotid artery pseudoaneurysm: technical case report.** *Neurosurgery* 1998;42:408–412
15. Van Nieuwenhove Y, Van den Brande P, van Tussenbroek F, Debing E, von Kemp K. **Iatrogenic carotid artery pseudoaneurysm treated by an autologous vein-covered stent.** *Eur J Vasc Endovasc Surg* 1998;16:262–265
16. Martin JB, Bednarkiewicz M, Christenson JT, Rufenacht DA. **Endovascular repair using vein-covered stents in the carotid artery bifurcation.** *Cardiovasc Surg* 2000;8:499–502
17. Wholey MH, Wholey MH, Jarmolowski CR, Eles G, Levy D, Buechel J. **Endovascular stents for carotid artery occlusive disease.** *J Endovasc Surg* 1997;4:326–338
18. Storger H, Haase J. **Polytetrafluoroethylene-covered stents: indications, advantages, and limitations.** *J Interv Cardiol* 1999;12:451–456
19. Elsner M, Auch-Schwelk W, Britten M, Walter DH, Schachinger V, Zeiher AM. **Coronary stent grafts covered by a polytetrafluoroethylene membrane.** *Am J Cardiol* 1999;84:335–338
20. Campbell PG, Hall JA, Harcombe AA, de Belder MA. **The Jomed covered stent graft for coronary artery aneurysms and acute perforation: a successful device, which needs careful deployment and may not reduce restenosis.** *J Invasive Cardiol* 2000;12:272–276