

# Generic Contrast Agents

Our portfolio is growing to serve you better. Now you have a choice.



FRESENIUS  
KABI

[VIEW CATALOG](#)

# AJNR

## Device Malfunction in Endovascular Treatment of Intracranial Aneurysms: Shared Responsibilities of Physician and Manufacturer

Ajay K. Wakhloo and Baruch B. Lieber

*AJNR Am J Neuroradiol* 2002, 23 (8) 1265-1267

<http://www.ajnr.org/content/23/8/1265>

This information is current as of May 5, 2025.

# Device Malfunction in Endovascular Treatment of Intracranial Aneurysms: Shared Responsibilities of Physician and Manufacturer

Ajay K. Wakhloo and Baruch B. Lieber

... the war is too important to leave it to the generals, the medicine is too important to leave it to the doctors, the science is too important to leave it to the scientist. . .

In this issue of the *AJNR*, Kwon et al describe "technical problems associated with new designs of Guglielmi Detachable coil [GDC]"; namely, device malfunction, such as the spontaneous detachment of GDC coils, coil backsliding into the microcatheter, and protrusion of small proximal parts of coils into the parent vessels after detachment. Only 12 events were reported out of many coils inserted. Unfortunately, the exact number of total coils used is not provided. Kwon et al reported these events in 10 (14.5%) of 69 recently treated patients. None of those patients had an adverse clinical outcome after endovascular treatment. The authors propose that the malfunctions they encountered are associated with the new SynerG GDC system (Boston Scientific/Target, Fremont, CA), particularly with the subtype, the stretch-resistant SR. Other complications, such as thromboembolism, aneurysmal rupture, coil migration, and coil stretching, were excluded from this report.

The authors present a nonstandard in vitro evaluation of both the GDC system and the new SynerG GDC system in which they used different coils (3D, 2D, SR, Soft, Ultrasoft). Manual force was used to bend and fracture the coils during placement in an aneurysmal model rather than by using mechanical testing systems to quantify the force. Coil jamming within the delivery system was also explored. The authors provide some elegant solutions for overcoming these problems in the clinical setting.

The major goal of the SynerG GDC system is to reduce the detachment time from several minutes, with the standard GDC system, to a few seconds, with the SynerG, thus reducing the overall procedural time. As the authors describe in detail, this reduction is achieved by the manufacturer's modification of the detachment zone. Figures 1 and 2 illustrate the major differences between the old and the new system.

Two major forces are involved with coil malfunction, and an experienced interventionalist appreciates the difference:

1. The force required to *push* a coil into the aneurysm is generally high and increases with the amount of coils already placed in the aneurysm. This force,  $F_1$ , can also be high if coils are pushed through an extremely tortuous vascular system because of increased intracatheter friction.  $F_1$  is transmitted through the

pusher wire to deploy the coil, but the force is also transmitted to the weakest area of the coil system, which is the detachment zone (Figs 1 and 2), if the coil meets resistance. This may cause the bending or fracturing of the detachment zone as well as a subsequent *premature coil detachment* within the catheter or the aneurysm. The force required to *fracture* the coil within the delivery catheter is higher than is the force exerted during intraaneurysmal coil placement, because the coil is confined within the catheter, and no deflection occurs. A broken coil can be pushed out of the delivery system, depending on the inner lumen of the catheter. An overlapping of the coil pusher and the proximal segment of the coil may occur, depending on the relation of the inner lumen of the catheter to the coil diameter used; this will increase the deployment force.

2. If a coil is *pulled* back for whatever reason, and caught within the aneurysm-coil mass or the delivery catheter, a *stretching* (unraveling) of the coil may occur. The physician recognizes the pull force,  $F_2$ , the weakest of all forces. Of course, continuous stretching will ultimately lead to fracture of the coil; this requires an extremely high force followed by the sudden drop of said force.

$F_1$  and  $F_2$  highlight the vital role of the coil detachment zone and the contradictory requirements for successful coil deployment. On one hand, we require a strong junction. On the other hand, we require a quick detachment time. Some new coil manufacturers attempt to address these issues.

Analysis of all the units returned to the manufacturer (Target/BSC) from clinical sites shows that the number of complaints regarding GDC performance over the past 5 years can be summarized as follows:

Confirmed unintentional detachment or breakage (% of units sold):

1997: 0.06%  
1998: 0.05%  
1999: 0.02%  
2000: 0.02%  
2001: 0.03%

In addition, the "spontaneous coil detachment" failure mode exemplified by the broken core wire that was reported to have occurred five times in Kwon et al's investigation has been confirmed to have occurred in fewer than 3% of the GDC centers worldwide. This figure is based on field returns to the manufacturer during 2001.




FIG. 1

With regard to multiple coils becoming jammed inside the “14” microcatheters, as cited in the article, most “14” catheters have a nominal inner diameter of 0.017 inch. The nominal inner diameter of GDC-10 coils is 0.010 inch; two GDC-10 coils side by side would total 0.020 inch. It has been demonstrated in Kwon et al’s bench top study that when enough force is used, two such coils can be jammed into the tip of “14” microcatheters. This phenomenon can only be induced *ex vivo* when the proximal tip of the previous coil is still within the distal tip of the microcatheter and is securely held in place, while the next coil is forced beyond the first coil’s proximal tip. This phenomenon is much more difficult, if not impossible, to induce in a “10” catheter, which generally has a nominal diameter of 0.014 inch. If this problem is repeatedly confronted, one should consider using “10” catheter systems for GDC-10 coil deliveries. Beyond the cases specified by the authors, a total of four such complaints were reported to the manufacturer and confirmed in 2001.

In several of Kwon et al’s reported cases, the authors state that the coils were deployed against significant resistance and subsequently fractured. The GDC device is and has always been delicate; if advanced against sufficient resistance, it will ultimately fracture at its weakest point. The manufacturer’s instructions for use clearly state, “do not advance the coil with force” and “remove the coil if unusual friction or scratching is noted” and “if resistance is noted during GDC coil delivery, remove the catheter-coil system.”

Our experience with the SynerG GDC System (SR, Soft, Ultrasoft) has resulted in only two instances of early coil detachment in over 2000 coils used. So far we have not had coils jam within the delivery catheter. However, toward the end of a coiling procedure, we have frequently seen the microcatheter being pushed out of the aneurysm. We overcome this problem by increasing axial force on the microcatheter, which generally pushes the most proximal part of the coil

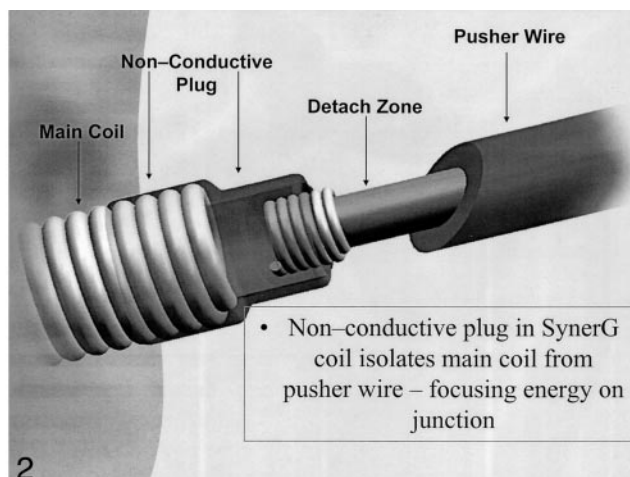


FIG. 2.

back into the aneurysm. Kwon et al encountered all of their technical problems by using Excelsior (Target/BSC, Fremont, CA) and Rebar 14 (MTI, CA) catheters. At our institution, we only use Prowler 10 or 14 catheters (Cordis J&J, Miami Lakes, FL). Modification of the most distal part of the Excelsior and Rebar catheters by their respective manufacturers may improve these technical pitfalls. On the basis of information we received, the manufacturer, Target/BSC, has developed certain process enhancements that should further reduce the potential for premature detachment of the GDC coils, which is already occurring at a very low rate.

The treatment of diseases of the human vascular system, including coronary, peripheral, and central nervous system, has reached a turning point. Sophisticated engineering tools and the development of effective drugs have mastered many critical issues and are now used for the treatment of complex vascular diseases through a minimally invasive, catheter-based approach. This endovascular approach has proved beneficial in short- and long-term results and is progressively replacing the standard surgical method. Findings of multicenter randomized trials underscore the effectiveness of endovascular treatments.

As techniques and tools to treat vascular diseases grow more complex, the interdisciplinary approach poses a challenge to scientists, engineers, and physicians who should learn more about each other’s disciplines. This involves the establishment of a forum wherein problems can be openly discussed.

Training physicians how to use endovascular devices and the participation of engineers in the clinical environment is vital. This collaboration is shaping biomedical engineering departments now mushrooming worldwide. As biomedical companies are predominantly involved in the generation of new tools and devices, the flux of information must be improved. The responsibility has to be shared on both sides:

physicians should learn more about the materials used, as they are becoming more complex, and biomedical engineering companies should disclose more about the construction of tools and devices to ensure their proper use. Regular training of engineers and physicians and the presence of the manufacturing engineers in mortality and morbidity conferences is

imperative for the proper use of endovascular devices, and most importantly, for the safety of our patients.

AJAY K. WAKHLOO  
BARUCH B. LIEBER  
*University of Miami  
Miami, FL*

## **Apparent Diffusion Coefficient and Hematoma: “Dose-Dependent” Relationship between Hemorrhage and Edema**

In this issue of *AJNR*, Carhuapoma et al report on the relationship between the size of acute intracerebral hematomas and the severity of vasogenic edema in adjacent brain. The authors measured changes in the apparent diffusion coefficient (ADC) in brain tissue adjacent to hematomas and found a correlation between ADC and hematoma size that indicates a “dose-dependent” relationship between hemorrhage and edema. They also discovered that ADC increased in contralateral homologous brain.

Why is this important? It is old news to neuroradiologists that peripheral edema develops around acute hematomas and that the extent of edema correlates with hematoma size. One simple answer is that while we “know” from clinical experience that this relationship exists, we have not collected data that quantify this relationship. Radiologic studies have been criticized, often unjustly, for their lack of quantitative rigor; therefore, it is edifying when intuitions based on clinical experience are verified by more rigorous scientific analysis. Carhuapoma et al, however, surpass simple verification of a long-standing clinical observation. These investigators are asking a new question by quantifying severity rather than extent of edema. The authors did not measure the volume of edematous brain but rather the change in ADC within the edematous brain (as defined by hyperintensity on T2-weighted images). Although the measurement of volume of edematous brain can be performed with either CT or MR imaging, measurement of severity of edema within affected brain can only be accomplished with MR imaging. The same is true for the notable (that is to say unexpected) finding in this study; namely, the presence of increased ADC in homologous brain tissue contralateral to the intracerebral hematoma. The authors believe that this phenomenon represents a reaction of the brain to this distant insult.

Therefore, diffusion-weighted MR imaging provides information concerning hematomas that is unavailable with CT. Does that mean that all acute hemorrhages should be imaged with MR? Most radiologists and clinicians are justifiably reluctant to adopt this strategy. Improvements in availability of

MR systems, study time, and patient monitoring have been matched by improvements in CT scanners. Despite enormous advances in MR technology, it is still faster and easier to perform CT scanning in a critically ill patient, and CT scans are easier to interpret than are MR images. Nonetheless, I must confess to a fondness for and fascination with the MR imaging features of intracranial hemorrhage. I have always thought that the complexity of MR findings in hemorrhage reflect, more accurately than CT, the complex events occurring in or around hematomas. But is the increased effort required to perform and interpret MR studies worth it? Carhuapoma and colleagues suggest that it might be. The authors encourage us to think of blood as a neurotoxin with a dose-dependent deleterious effect on brain, an effect that might be prevented or at least ameliorated by medical or surgical intervention. This will require a cognitive shift for clinicians and neuroradiologists.

We tend to think of hemorrhage as an undesirable end result rather than as a dynamic process whose course can be changed. Hemorrhage is what we don't want to see on an image obtained in someone with an acute neurologic event, because this finding exposes the patient to the possibly disastrous complication of medical or surgical therapy. Currently, limited treatment options are available, such as stereotactic hematoma removal, but we do not know their efficacy. Medical treatments have yet to be devised and tested. Carhuapoma and colleagues point to animal data indicating that thrombin is the major culprit in the inflammatory reaction that produces perihematoma edema. Medical treatment aimed at reducing thrombin's effects is just one of many possible treatment options. An understanding of the biochemical and physiologic changes associated with hemorrhage will be required if new effective therapies are to be devised. The ability of MR imaging to display the complex processes occurring in and around hematomas offers us a unique opportunity to study the effects of hemorrhage in vivo.

As the authors state, quantitative data from MR images will probably turn out to be critical to research



of the efficacy of therapeutic options and clinical decision making. Treatment of acute vascular neurologic events will always be stuck between the rock of infarction and the hard place of hemorrhage. Procedures that limit infarction increase the risk of hemorrhage and vice versa. Qualitative assessment of images will not be accurate enough to make decisions about whom, when, and how to treat acute vascular events. We will need hard data, and MR imaging is the technique most likely to provide these data. Assessment of a variety of parameters including relaxation times, susceptibility effects, perfusion, ADC, tissue anisotropy, magnetization transfer, and brain metabolites can be obtained with MR imaging. It is unclear which of these parameters singly or in combination will prove most effective, but if we are to make headway in the treatment of this common cause of stroke, we must begin to study hemorrhage in a systematic way.

Carhuapoma et al have presented us with data from a small number of patients with acute hematomas. They have assessed a single variable, ADC, at a single and somewhat variable time point. As with any good science, the study raises more questions than it answers. What is the effect of ADC change on prognosis? Which is more important for outcome: the volume of the edematous brain or the severity of edema within that brain? How does edema progress during the initial hours and days of ictus? Are treatment options time-sensitive (as they are in acute infarction)? Does the cause of hemorrhage determine the extent of edema? Hypertension and cerebral amyloid angiopathy produce focal hematomas that displace normal brain, whereas hemorrhagic infarction and contusions produce hemorrhage into and exten-

sive destruction of brain tissue. Does this alter the time course and severity of edema? Could it affect treatment options?

The most fascinating finding in this study is the increase in ADC in the brain contralateral to the hematoma. Hematomas are quintessentially focal lesions, yet we are now told that they have distant effects. The authors speculate that this represents a remote response to neurotoxic effects of blood products. This is probably true, but we don't know how this response is mediated and what effect this action at a distance has on brain function. The data in this study do point to another advantage that MR imaging offers us in the assessment of pathologic processes. We can measure global and regional changes with parameters such as ADC with relative ease. In this study, the authors compared the ADC in the contralateral homologous brain. Were the effects limited to this region or were they global? The answer to this question might assist us in determining the cause of this phenomenon and its functional consequences.

This study is important, because it points us in a new direction. We now can think of hemorrhage in a new way. This will inevitably lead to new challenges. I am certain that many of the questions I have posed will turn out to be unimportant, but I am equally certain that important questions will persist, and the answers will aid in developing effective therapies for intracranial hemorrhage. MR imaging, with its high intrinsic information content, will be our tool for investigation, and eventually, for clinical decision making.

ROBERT D. ZIMMERMAN, MD  
*New York Presbyterian Hospital  
New York, NY*