

# Generic Contrast Agents

Our portfolio is growing to serve you better. Now you have a *choice*.



FRESENIUS  
KABI

[VIEW CATALOG](#)

# AJNR

## **Intracanalicular Meningioma Mimicking Vestibular Schwannoma**

Katsuyuki Asaoka, David M. Barrs, John H. Sampson, John T. McElveen, Jr, Debara L. Tucci and Takanori Fukushima

*AJNR Am J Neuroradiol* 2002, 23 (9) 1493-1496

<http://www.ajnr.org/content/23/9/1493>

This information is current as of May 5, 2025.

## Intracanalicular Meningioma Mimicking Vestibular Schwannoma

Katsuyuki Asaoka, David M. Barrs, John H. Sampson, John T. McElveen Jr.,  
Debara L. Tucci, and Takanori Fukushima

**Summary:** Three cases of intracanalicular meningioma mimicking vestibular schwannoma are presented. In each case, a contrast-enhancing mass filling the internal auditory canal was identified on MR images and was originally diagnosed as a vestibular schwannoma. Although it is difficult to differentiate definitively between these lesions preoperatively, imaging findings inconsistent with a diagnosis of vestibular schwannoma can be identified. Preoperative identification of intracanalicular meningiomas permits alterations in surgical planning that allow for the more complete resection of these rare tumors.

Meningiomas that occupy the cerebellopontine angle usually arise from the posterior surface of the petrous bone or the petrotentorial junction. Although, in some instances, a large cerebellopontine angle meningioma secondarily involves the internal auditory canal (IAC), meningiomas primarily arising from and mainly confined to the IAC are rare (1–10). We herein present three cases of intracanalicular meningioma, each with a different type of extracanalicular extension, that were initially suspected to be cases of vestibular schwannoma, and we discuss the diagnostic and therapeutic issues related to this disease entity.

### Case Reports

#### Case 1

A 66-year-old man had a 3-month history of decreased hearing and high-pitched tinnitus in the left ear. He was seen by the local otologic service and the diagnosis of a vestibular schwannoma in the left IAC was made on the basis of MR imaging findings (Fig 1). He was referred to our institute for tumor resection. The preoperative audiologic examination showed that hearing on the left side was decreased to 50 dB pure tone average (500–3000 Hz), with a word recognition score of 56%. Because the patient's hearing was still serviceable, we decided to use the middle fossa approach to attempt tumor eradication with hearing preservation. In the IAC, a tan, multilobulated, soft tumor with abundant vascularity was seen

displacing the facial nerve posteriorly. The tumor did not appear to be a vestibular schwannoma and on frozen section was confirmed to be a meningioma. The tumor was meticulously dissected, with preservation of the facial and vestibulocochlear nerves. The origin of the tumor was the anterior wall of the IAC. The tumor, including the dural attachment, was totally removed. Postoperatively, the patient's hearing worsened to a word recognition score of 20%, but the facial nerve function was normal. The final histologic examination revealed a meningioma with numerous psammoma bodies.

#### Case 2

A 39-year-old man noted a 1-year history of progressive decrease in hearing in his left ear, which had been of relatively sudden onset. He did not have tinnitus or dizziness. His MR images showed an enhancing mass occupying the left IAC and extending toward the petrous apex (Fig 2A and B). The preoperative audiogram showed a complete hearing loss in his left ear at 106 dB pure tone average. With a preoperative diagnosis of vestibular schwannoma, the tumor was removed by means of a translabyrinthine approach. Because of the anterior extension of the tumor, the facial nerve was completely skeletonized from the descending segment in the mastoid to the IAC. After incising the IAC dura, a friable, hypervascular tumor was exposed. The tumor entirely engulfed and was severely adherent to the facial nerve, with invasion into the anterior petrosal bone. A frozen histologic section showed a meningioma. The facial nerve was sharply dissected from the tumor and was rerouted inferiorly after cutting the greater superficial petrosal nerve. The invaded petrosal bone, including the cochlea, was extensively drilled away toward the petrous apex to totally remove the tumor. After surgery, mild left facial weakness (House-Brackmann grade III) was observed, which gradually returned to normal. The permanent pathologic specimen revealed a meningioma with tumor invasion into bone (Fig 2C). Immunohistochemistry showed that the tumor cells stained strongly for vimentin and did not stain for S-100 protein, features consistent with meningioma.

#### Case 3

A 67-year-old woman who had left hearing loss approximately 20 years previously gradually developed left facial weakness over a 2- to 3-year period. As a result, she underwent MR imaging that revealed an enhancing mass occupying the IAC and extending out to the porus acoustics (Fig 3) and was then referred to our institute with a diagnosis of vestibular schwannoma. Neurologic examination showed left facial weakness (House-Brackmann grade III) and left deafness. On the basis of our experience with the former two cases, we suspected a possibility of meningioma as a differential diagnosis because of the broad-based extension pattern of the tumor, which is unusual for vestibular schwannoma, and the association of facial weakness with a small intracanalicular tumor. The patient underwent surgery by means of translabyrinthine approach. The tumor was hypervascular and showed the typical appearance of meningioma under the operating microscope with numerous small calcifications. The frozen histologic section also revealed

Received February 5, 2002; accepted after revision April 2.

From the Carolina Neuroscience Institute for Skull Base Surgery (K.A., T.F.) and the Carolina Ear Research Institute (D.M.B., J.T.M.), Raleigh, and the Divisions of Neurosurgery (J.H.S.) and Otolaryngology (D.L.T., J.T.M.), Duke University Medical Center, Durham, NC.

Address reprint requests to Katsuyuki Asaoka, MD, PhD, Carolina Neuroscience Institute for Skull Base Surgery, 4030 Wake Forest Road, Suite 115, Raleigh, NC 27609.

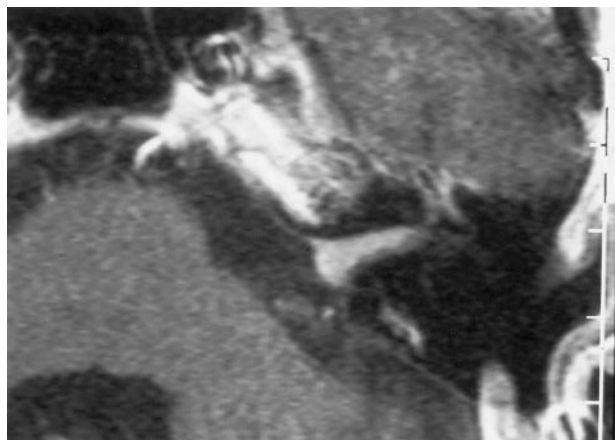

FIG 1. Case 1: 66-year-old man with an entirely intracanalicular meningioma. Contrast-enhanced axial T1-weighted MR image (450/14 [TR/TE]) reveals a homogeneously enhancing mass filling the IAC.

a meningioma. The origin of the tumor was the dura near the porus acoustics in the IAC. Because the tumor severely adhered to the facial nerve in the IAC, we had to leave a small amount of the tumor tissue on the nerve to avoid its damage. The histologic diagnosis was meningioma.

### Discussion

The development of high-spatial-resolution MR imaging has facilitated detection of small intracanalicular lesions. Although vestibular schwannomas account for most intracanalicular lesions, other, less common pathologic abnormalities including meningioma should always be considered, because they have implications for management strategy (1, 11–13). Intracanalicular meningioma, which originates from and mainly occupies the IAC, is a rare entity. To the best of our knowledge, 14 cases have been reported in the literature before our three cases. Eleven of 17 cases, including ours, were diagnosed by using contrast-enhanced MR imaging.

#### *Origin of the Tumor*

It is known that the origin of meningiomas is the arachnoid villi that are primarily found along major venous sinuses, especially around the superior sagittal sinus. Meticulous histologic study has shown that these arachnoid villi can also be within the IAC and could serve as a site of origin for intracanalicular meningiomas. Nager and Masica (14) found that arachnoid villi were distributed not only along the dural sinuses and in the gasserian envelopes but also along the greater superficial petrosal nerve, within the IAC, around the geniculate ganglion of the facial nerve, and within the jugular foramen. Guzowski et al (15) histologically examined 200 randomly selected temporal bones and confirmed the presence of arachnoid granulations around the petrous apex, near the trigeminal impression, and in the sulcus for the greater superficial petrosal nerve. Although they could not find true arachnoid granulations in the

IAC, there were small clusters of arachnoid epithelium that could also serve as an origin of meningioma.

#### *Diagnostic Considerations*

It is difficult to differentiate small intracanalicular meningiomas from vestibular schwannomas preoperatively. The clinical symptoms caused by intracanalicular meningiomas are mostly identical to those caused by vestibular schwannomas and other lesions that occupy the IAC. Most of the cases initially manifest a hearing problem. The subtle difference is that facial nerve symptoms are more likely to occur with meningiomas than with vestibular schwannomas when the size is small. Four of 17 cases presented facial nerve symptoms, three with facial paralysis and one with hemifacial spasm, yet vestibular schwannomas of a similar size rarely cause facial paresis. Needless to say, the facial nerve schwannoma should also be considered when the patient presents with facial nerve symptoms.

Signal intensity of these masses on MR images will not contribute to the accurate radiographic diagnosis of the intracanalicular meningioma. Both lesions are isointense to hypointense on T1-weighted MR images and are of variable signal intensity on T2-weighted MR images. They will also both brightly enhance after administration of contrast medium. Vestibular schwannomas that originate from the IAC comprise approximately 90% of cerebellopontine angle tumors (16). In this context, when a patient is found to have an enhancing mass in the IAC, it is usually assumed to be a vestibular schwannoma. Most of the reported cases of intracanalicular meningiomas, including our three cases, were initially suspected to be vestibular schwannomas (3, 5–10).

Nonetheless, there are some radiographic findings that should raise the suspicion of intracanalicular meningioma. Calcification and a “dural tail” may be helpful, although these findings are also nonspecific (1, 17). In our second case, we retrospectively discovered intracanalicular dural enhancement in the coronal section of contrast-enhanced MR images. Another key is the extension pattern of the tumor. On the basis of the reported 17 cases, we categorized the extension patterns into following four types: 1) entirely intracanalicular (seven cases); 2) intracanalicular with cerebellopontine angle extension (five cases); 3) intracanalicular with both cerebellopontine angle extension and invasion into surrounding bone (three cases); and 4) intracanalicular with bone invasion but no cerebellopontine angle extension (two cases). Although it is very difficult to differentiate a meningioma from a vestibular schwannoma if an entirely intracanalicular type is encountered, other extension patterns may provide some information leading to the correct diagnosis. When the tumor extends out to the cerebellopontine angle, as in our third case, the growing pattern outside the IAC deserves attention. We think that broad-based extension into the petrous bone and a rugged medial tumor surface are valuable clues to the diagnosis of meningiomas, whereas ves-

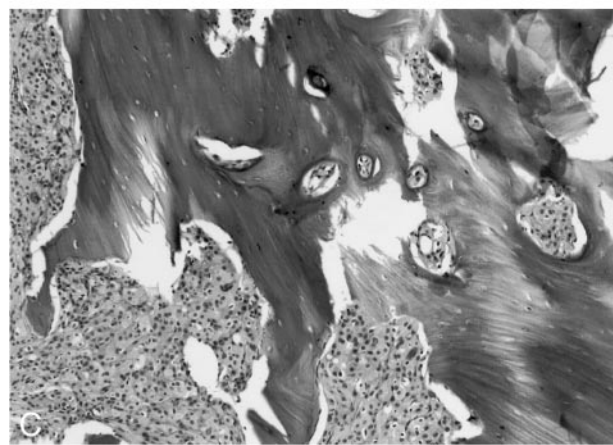
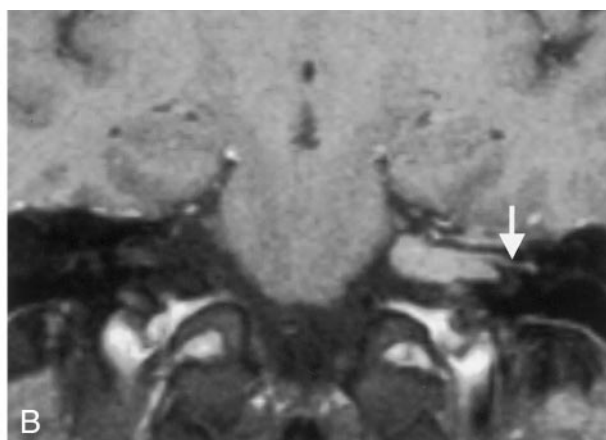
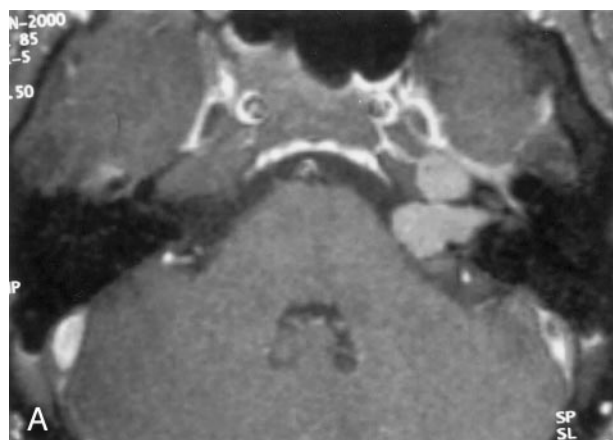


FIG 2. Case 2: 39-year-old man with an intracanalicular meningioma.

A, Contrast-enhanced axial T1-weighted MR image (540/12) shows an enhancing mass in the IAC extending toward the petrous apex and the cerebellopontine angle.

B, Contrast-enhanced coronal T1-weighted MR image (540/12) shows dural enhancement (arrow) in the IAC, which was noticed retrospectively.

C, Photomicrograph of specimen shows meningioma infiltrating into bone. (hematoxylin and eosin, original magnification  $\times 100$ )

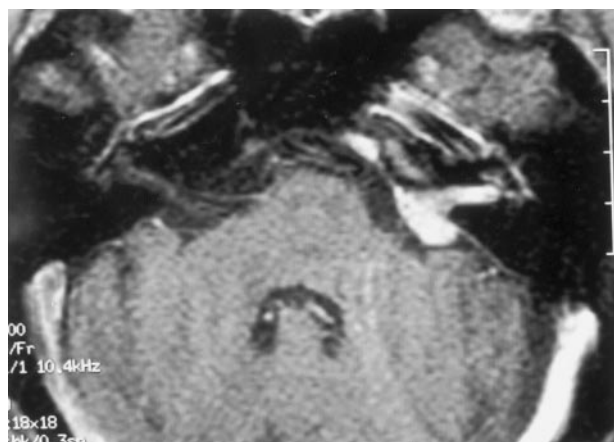


FIG 3. Case 3: 67-year-old woman with an intracanalicular meningioma. Contrast-enhanced axial T1-weighted MR image (600/9) shows an enhancing mass occupying the IAC and extending out to the cerebellopontine angle.

tibular schwannomas usually have a more spherical shape and have a smoother surface. Meningiomas in the IAC also have a tendency to involve adjacent nerve tissues or bones, (1, 2, 7, 9) as presented in our second case. Nager and Masica (14) showed, by histologic examination, that meningiomas located in the IAC can invade the labyrinth and cochlea by following their individual nerve fibers to their ends. Meningiomas can also infiltrate widely into surrounding petrous bone marrow spaces and air cells. Conversely,

dilatation of the IAC due to bone erosion is a more common radiologic finding with vestibular schwannomas and extensive bone invasion is unusual. Thus, the presence of bone invasion around the IAC is suggestive the diagnosis of meningioma.

### *Therapeutic Issues*

Preservation of facial nerve function is one of the most important issues in the surgery of intracanalicular lesions. It is important to note that the anatomic relationship between the tumor and the facial nerve in cases of intracanalicular meningioma is different from that in cases of vestibular schwannoma. With vestibular schwannoma, the facial nerve is compressed and classically displaced rostrally and medially by the tumor mass in the IAC. However, in our experience with these three cases of intracanalicular meningiomas, the tumor did not just compress the facial nerve but intimately involved it. Both in our second and third cases, the facial nerve was totally engulfed in the tumor. The adhesions between meningiomas and the facial nerve are also much more difficult to separate, even for smaller tumors, than those found in cases of vestibular schwannoma. Meticulous sharp dissection is very important to avoid damage to the facial nerve, even in cases of small intracanalicular meningiomas.



## Conclusion

Complete resection of these tumors is important, because meningiomas are also more likely to recur than vestibular schwannomas. One of the reasons for this characteristic is considered to come from invasiveness into the adjacent structures, as mentioned above. Surgery of an intracanalicular meningioma, therefore, should be more extensive, resecting the tumor mass along with the attached dura and the invaded petrous bone. Because the preoperative differential diagnosis of intracanalicular lesions is usually difficult to make, intraoperative histologic diagnosis is essential. If meningioma is found, a more radical resection is accomplished to attempt to prevent recurrence. Preoperative suspicion of intracanalicular meningioma will assist the surgeon by allowing alterations in surgical planning that permit better exposure and more extensive resection of these difficult lesions.

## References

1. Atlas MD, Fagan PA, Turner J. **Calcification of internal auditory canal tumors.** *Ann Otol Rhinol Laryngol* 1992;101:620–622
2. Brookler KH, Hoffman RA, Camins M, Terzakis J. **Trilobed meningioma: ampulla of posterior semicircular canal, internal auditory canal, and cerebellopontine angle.** *Am J Otol* 1980;1:171–173
3. Caylan R, Falcioni M, De Donato G, et al. **Intracanalicular meningiomas.** *Otolaryngol Head Neck Surg* 2000;122:147–150
4. Dinh DH, Clark SB, Whitehead M, Amedee R, Bhattacharjee MB. **Intracanalicular meningioma.** *South Med J* 2000;93:618–621
5. Haught K, Hogg JP, Killeffer JA, Voelker JL, Schochet SS Jr. **Entirely intracanalicular meningioma: contrast-enhanced MR findings in a rare entity.** *AJNR Am J Neuroradiol* 1998;19:1831–1833
6. Hodgson TJ, Kingsley DP. **Meningioma presenting as a mass in the internal auditory canal.** *Neuroradiology* 1995;37:479–480
7. Ishikawa N, Komatsuzaki A, Tokano H. **Meningioma of the internal auditory canal with extension into the vestibule.** *J Laryngol Otol* 1999;113:1101–1103
8. Langman AW, Jackler RK, Althaus SR. **Meningioma of the internal auditory canal.** *Am J Otol* 1990;11:201–204
9. Singh KP, Smyth GD, Allen IV. **Intracanalicular meningioma.** *J Laryngol Otol* 1975;89:549–552
10. Zeitouni AG, Zagzag D, Cohen NL. **Meningioma of the internal auditory canal.** *Ann Otol Rhinol Laryngol* 1997;106:657–661
11. Ajal M, Roche J, Turner J, Fagan P. **Unusual lesions of the internal auditory canal.** *J Laryngol Otol* 1998;112:650–653
12. Bohrer PS, Chole RA. **Unusual lesions of the internal auditory canal.** *Am J Otol* 1996;17:143–149
13. Han MH, Jabour BA, Andrews JC, et al. **Nonneoplastic enhancing lesions mimicking intracanalicular acoustic neuroma on gadolinium-enhanced MR images.** *Radiology* 1991;179:795–796
14. Nager GT, Masica DN. **Meningiomas of the cerebello-pontine angle and their relation to the temporal bone.** *Laryngoscope* 1970;80:863–895
15. Guzowski J, Paparella MM, Nageswara K, Hoshino T. **Meningiomas of the temporal bone.** *Laryngoscope* 1976;86:1141–1146
16. Brackmann DE, Bartels LJ. **Rare tumors of the cerebellopontine angle.** *Otolaryngol Head Neck Surg* 1980;88:555–559
17. Lunardi P, Mastronardi L, Nardacci B, Acqui M, Fortuna A. **“Dural tail” adjacent to acoustic neuroma on MRI: a case report.** *Neuroradiology* 1993;35:270–271