

Generic Contrast Agents

Our portfolio is growing to serve you better. Now you have a *choice*.



[VIEW CATALOG](#)

AJNR

Vascular and Interventional Radiology: Principles and Practice

AJNR Am J Neuroradiol 2003, 24 (4) 776-777
<http://www.ajnr.org/content/24/4/776>

This information is current as
of May 24, 2025.

Vascular and Interventional Radiology: Principles and Practice

Curtis W. Bakal, James E. Silberzweig, Jacob Cynamon, and Seymour Sprayregen. New York, NY: Thieme Medical Publishers; 2002. 480 pages. 19 tables, 712 illustrations. \$139.

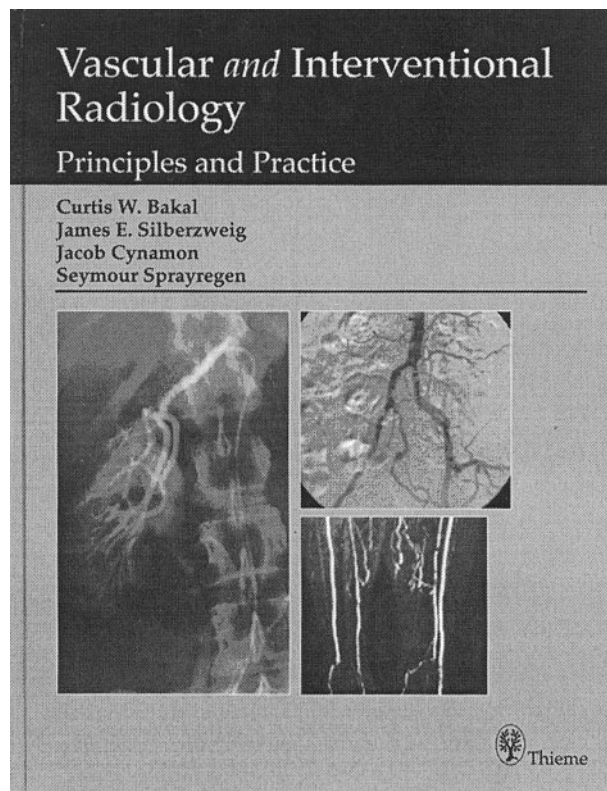
The goal of this multi-authored text was to write a “book to be read in a month of evenings by radiology residents on a vascular interventional radiology rotation” that would allow the reader “to gain the essence and approaches for these therapies without the overwhelming detail.” It was intended to be a text composed of a collection of monographs presenting a current spectrum of interventional procedures. There are several observations that can be made regarding individual chapters and the book overall.

In the preface, the authors admit that the book really consists of separate articles providing the basics of the field. I found this book to be a little disorganized, with several introductory chapters starting off, then very specific chapters on biopsy, drainage, embolization, and gastrostomy procedures, then another set of introductory chapters on radiation protection and health and safety.

The first chapter presents a whirlwind tour of vascular interventional radiology’s >60 years in six paragraphs. Next is a chapter on catheters and guidewires. It provides an excellent introduction for the radiology resident but could benefit from illustrative diagrams of less commonly used puncture sites and techniques. Chapter three, Filming and Injection Techniques, is really geared for residents and reviews basic injection and filming rates, delayed filming, and contrast media. This chapter organizes into tables and puts into words the numbers we have all come to learn from experience. The coverage of contrast material, nephrotoxicity, and contrast reactions is minimal, with those subjects being mentioned only in passing.

Chapter four, Conscious Sedation and Monitoring, is concise and outlines pertinent information, using tables to highlight commonly used drugs and to detail the American Society of Anesthesiologists patient classification system. An excellent chapter on MR angiography and CT angiography details the strengths and weaknesses of each technique and indications. The images in this chapter are excellent. The chapter falters somewhat, I think, in its treatment of CT angiography in the diagnosis and workup of pulmonary embolism. Considering how profoundly that imaging technique has changed the diagnostic algorithm of pulmonary embolism and how it has resulted in a marked decrease in the volume of pulmonary angiography, it probably deserves more than two paragraphs.

The clinical and noninvasive evaluation of peripheral vascular disease is a much-needed chapter in basic vascular interventional radiology texts. The review of segmental limb pressures, Doppler evaluation, plethysmography, exercise testing, and vascular sonography is excellent. The photographs in this



chapter would have been more useful if reproduced in color.

The chapters on radiation protection and health and safety in the interventional suite touch on topics every resident and fellow should know before performing invasive radiologic procedures. Vascular anatomy chapters are interspersed between procedural text. The diagrams and photographs are very clear and helpful. Considering that this is an introductory text, I think these chapters in particular would benefit from additional illustrations, especially when a named structure is mentioned. For example, the arc of Barkow is mentioned but there is no illustration of this collateral pathway. Chapters on pulmonary and bronchial arteriography are presented and are again notable for the absence of CT angiography in the discussion of pulmonary embolism. The chapter on carotid, vertebral, and spinal angiography is basic but is well illustrated.

The chapter on atherosclerotic disease of the aorta, pelvis, and lower extremities is very clinically oriented and provides an excellent, focused discussion on the clinical management of acute and chronic limb isch-

emia and lists surgical and interventional treatment options.

The section on inferior vena cava filters is organized in an odd fashion. The author dedicates nine pages to the types of inferior vena cava filters but only three paragraphs to placement technique. Vascular anomalies of the vena cava and landmarks are only mentioned in a passing sentence. I think the emphasis should be reversed, especially in an introductory text.

The discussion of renovascular hypertension and renal vascular trauma is pertinent and well organized. On the other hand, the focus of the next chapter seems reversed. Nephrostomy catheter placement technique is barely touched on, but the details of ureteral stent placement are examined at length. The pelvic and obstetric hemorrhage chapter is very well written and illustrated. Traumatic and obstetric hemorrhage and uterine fibroids, arteriovenous malformations, and AVF of the pelvis are discussed.

Pudendal arteriography is discussed briefly regarding the treatment of impotence and priapism. This is definitely a chapter that, if included in a basic text, should include diagrams of the somewhat confusing anatomy, especially considering the quality of the arteriograms provided. I think that pudendal arteriography should receive a more lengthy and proper treatment but may be out of the scope of the first year radiology resident.

Venography and percutaneous treatment of varicocele and female infertility have increased significantly in the recent past. As such, they deserve to have their own chapter. This section details the diagnosis and percutaneous treatment of varicocele for 11 pages but, strangely enough, does not even mention pelvic congestion syndrome, its female counterpart. This is incredible, considering the similarities of the two diseases and the amount of attention pelvic congestion syndrome has garnered in recent times. The chapter goes on to briefly describe hysterosalpingography and fallopian tube recanalization.

The chapter on non-variceal upper gastrointestinal bleeding is comprehensive. The next chapter on liver and spleen includes some lovely illustrations of hepatic tumors but pretty much ignores the subject of portal hypertension and its percutaneous diagnosis

and management, providing only a couple of paragraphs on transjugular intrahepatic portosystemic shunt. In contradistinction, a whole chapter is devoted to the treatment of gastrointestinal strictures. The emphasis should be reversed.

The chapter on arteriography and venous sampling of the parathyroid glands, pancreas, and adrenal glands is nothing short of amazing. There are diagrams, arteriograms, and venograms galore. The book would be of greater value if the rest of the chapters were illustrated like this chapter. It is even more outstanding in that these are procedures that are not that commonly performed these days. Overall, the remainder of the book is not as heavily illustrated as it should be. The reader often finds himself slogging through seemingly endless text before he gets to the next photograph or diagram, which makes for hard reading at times.

The text is pertinent to the neuroradiology audience only in that it provides a general review for those who may have "gotten rusty" over the years. It is pertinent to radiology residents as part of their introduction to invasive radiology.

This book is similar in scope to other books that have been published recently but does not go consistently into the detail that some of the others do, detail that would be necessary when preparing for the oral board examination or vascular interventional radiology certificate of added qualification examination. This book also emphasizes several areas that are not typically covered in most texts, such as radiation protection, safety, venous sampling, pelvic hemorrhage, and pudendal arteriography. The chapter on the clinical and noninvasive examination of the patient with peripheral vascular disease is outstanding and not often found in basic texts. The book also has several diagnostic arteriograms of renal and hepatic tumors that are not often included in modern texts.

In conclusion, *Vascular and Interventional Radiology* does largely what it intends to do. It is not a board review text, it is not a manual to carry in your pocket late at night, and it is not an encyclopedia—nor was it intended to be. It provides a series of lecture monographs strung together that serve to introduce residents to the world of vascular interventional radiology.