



Discover Generics

Cost-Effective CT & MRI Contrast Agents



FRESENIUS
KABI

WATCH VIDEO

AJNR

The Human Hippocampus: Functional Anatomy, Vascularization and Serial Sections with MRI, 3rd edition

AJNR Am J Neuroradiol 2005, 26 (10) 2702
<http://www.ajnr.org/content/26/10/2702>

This information is current as
of June 27, 2025.

Book Review

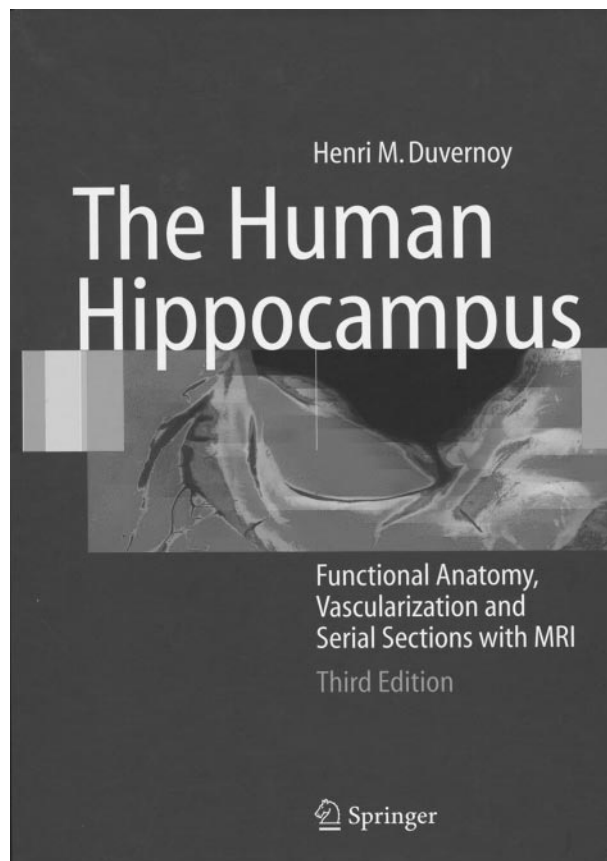
***The Human Hippocampus: Functional Anatomy, Vascularization and Serial Sections with MRI*, 3rd edition**

By Henri M. Duvernoy, F. Cattin, T.P. Naidich, C. Raybaud, P. Y. Risold, U. Salvolini, and U. Scarabine New York: Springer-Verlag; 2005. 232 pages, 260 illustrations, \$199

When initially published in 1988, *The Human Hippocampus* immediately became a necessary book. The third edition of this wonderfully illustrated book is no different. For neuroscientists, neurologists, neurosurgeons, and neuroradiologists involved in understanding memory or epilepsy or having a need to understand the hippocampus, this book is essential.

The third edition contains 7 chapters. There are 2 short chapters initially: an Introduction and a brief chapter on Materials and Methods. The rest of the chapters are the essence of the book and are divided into 5 sections. The first section (chapter 3) is devoted to the structure, function, and connections of the hippocampus. A concise but well-written description of anatomy and function accompany a superbly illustrated chapter. Figures consist of a mix of gross anatomy photographs, histologic sections, and colored diagrams to help introduce the reader to hippocampal anatomy and its related function. The second section (chapter 4) is a description of the anatomy of the hippocampus and adjacent structures. This chapter provides an abundant display of gross hippocampal anatomy with related diagrams as needed. The third section (chapter 5) is devoted to the vascularization of the hippocampus. A rich quantity of color diagrams and beautifully rendered photographs of the hippocampus with intravascular injections is supplied. The fourth section (chapter 6) contains coronal, sagittal, and axial histologic sections of the hippocampus after intravascular India ink injection. This section contains 18 carefully labeled figures. The last section (chapter 7) is devoted to sectional anatomy with corresponding MR images. This chapter contains 20 "plates" or different sectional regions of the brain. In each plate, there are at least 4 figures. The initial figure is set to help guide the reader to a cross-sectional location by demonstrating the section within a 3D drawing of the hippocampus. Corresponding India ink, histologic, and gross section studies and one more MR imaging study are included with each plate. The MR imaging studies are from images acquired on a 3T and/or 9.4T scanner. There is some overlap between chapters 6 and 7. However, chapter 6 is organized so that one can view the gross sectional anatomy in a linear fashion (ie, each successive figure advances to the next slice), whereas chapter 7 is organized so that one views multiple corresponding images (such as diagrams, gross anatomy, histologic sections, and MR images) before proceeding to the next slice.

The strength of this book is the abundance of stunning images, which are all meticulously labeled. There are 124 official figures or illustrations in this atlas; however, many of these figures have 4 parts, so there are many more than 124 individual figures or diagrams. For those individuals who own the first edition, there is a



significant amount of revision and expansion in the third edition so that I would recommend an update with the third edition. For those who own the second edition, it may not be worth updating to the third edition. There are some small changes between the second and third editions. The organization of the sectional anatomy is different: a chapter devoted strictly to histologic sections (ie, chapter 6) was added. Most of the histologic figures were previously included in the sectional anatomy chapter in the second edition. MR images in the second edition were acquired on 1.5T scanners, whereas the third edition contains higher resolution MR imaging sections obtained on 3T and 9.5T imagers.

In summary, the third edition offers a slight improvement on the second edition; Duvernoy's second edition has been the gold standard for describing the anatomy of the human hippocampus. There is no other atlas that has such beautifully photographed images with corresponding diagrams and MR images as *The Human Hippocampus*. For those neuroscientists, neurosurgeons, neuroradiologists, and neurologists who are interested in this region of anatomy, this book is a must.